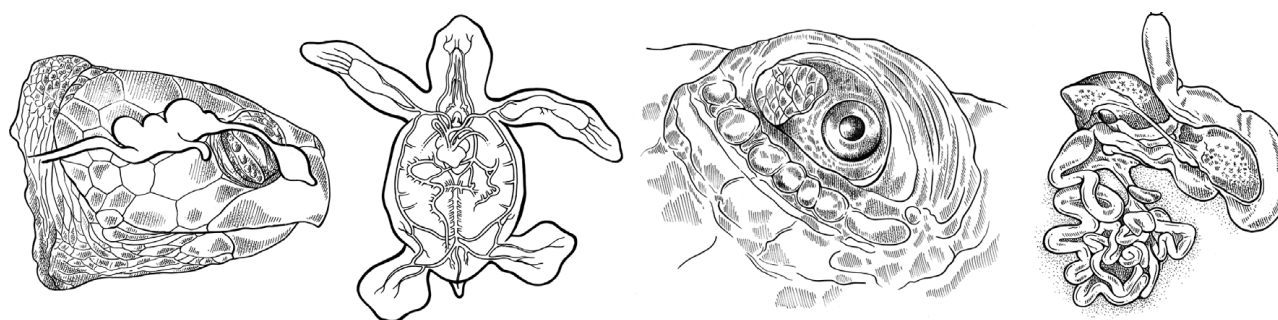
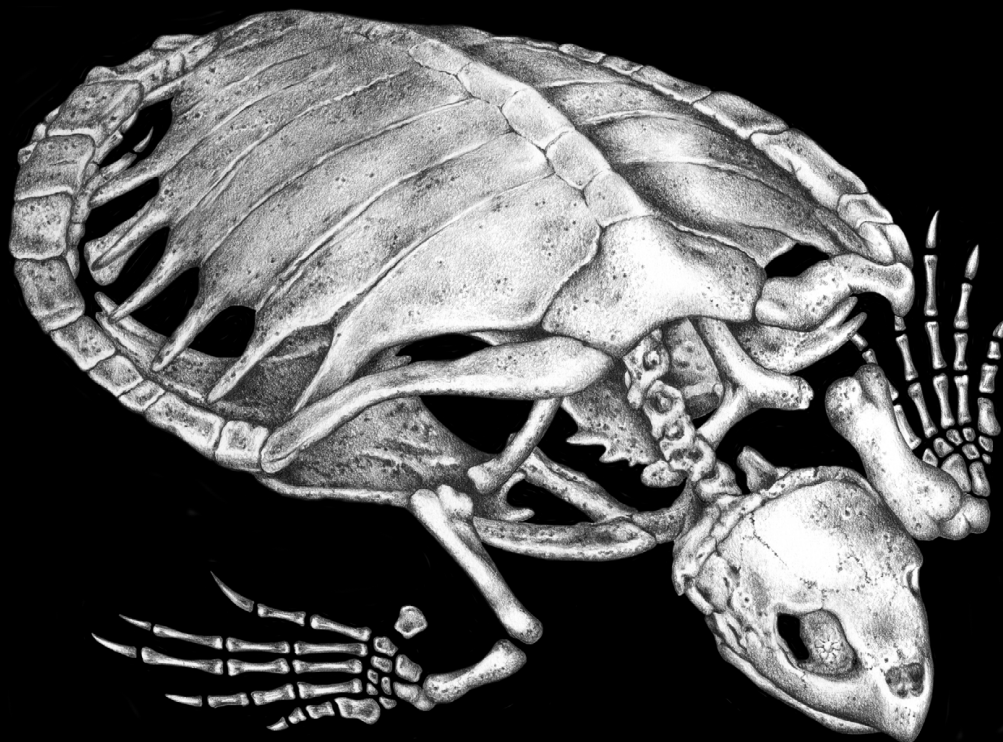




NOAA Technical Memorandum NMFS-SEFSC-470

The Anatomy of Sea Turtles



Jeanette Wyneken, Ph.D.

Illustrated by Dawn Witherington

December 2001

U. S. Department of Commerce
National Oceanic and Atmospheric Administration
National Marine Fisheries Service

Southeast Fisheries Science Center, 75 Virginia Beach Drive, Miami, FL 33149

NOAA Technical Memorandum NMFS-SEFSC-470



THE ANATOMY OF SEA TURTLES

by

Jeanette Wyneken, Ph.D.

U. S. DEPARTMENT OF COMMERCE

Donald L. Evans, Secretary

NATIONAL OCEANIC AND ATMOSPHERIC ADMINISTRATION

Conrad C. Lautenbacher, Jr., Administrator

NATIONAL MARINE FISHERIES SERVICE

William T. Hogarth, Assistant Administrator for Fisheries

December 2001

Unpublished reports are used for documentation and timely communication of preliminary results, interim reports, or special-purpose information, and have not received complete formal review, editorial control, or detailed editing.

NOTICE

The National Marine Fisheries Service (NMFS) does not approve, recommend or endorse any proprietary product or material mentioned in this publication. No reference shall be made to NMFS, or to this publication furnished by NMFS, in any advertising or sales promotion which would indicate or imply that NMFS approves, recommends or endorses any proprietary product or proprietary material herein or which has as its purpose any intent to cause directly or indirectly the advertised product to be used or purchased because of NMFS publication.

Correct citation of this report is:

Wyneken, J. 2001. The Anatomy of Sea Turtles. U.S. Department of Commerce NOAA Technical Memorandum NMFS-SEFSC-470, 1-172 pp.

The scientific contents of the The Anatomy of Sea Turtles

© 2001 Jeanette Wyneken.

Copyright claimed on pages iii-172 exclusive of page 4

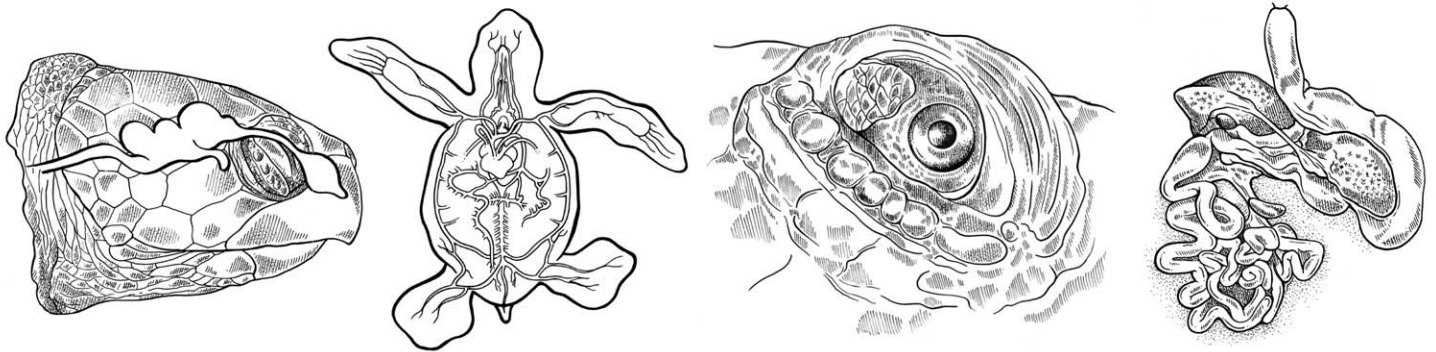
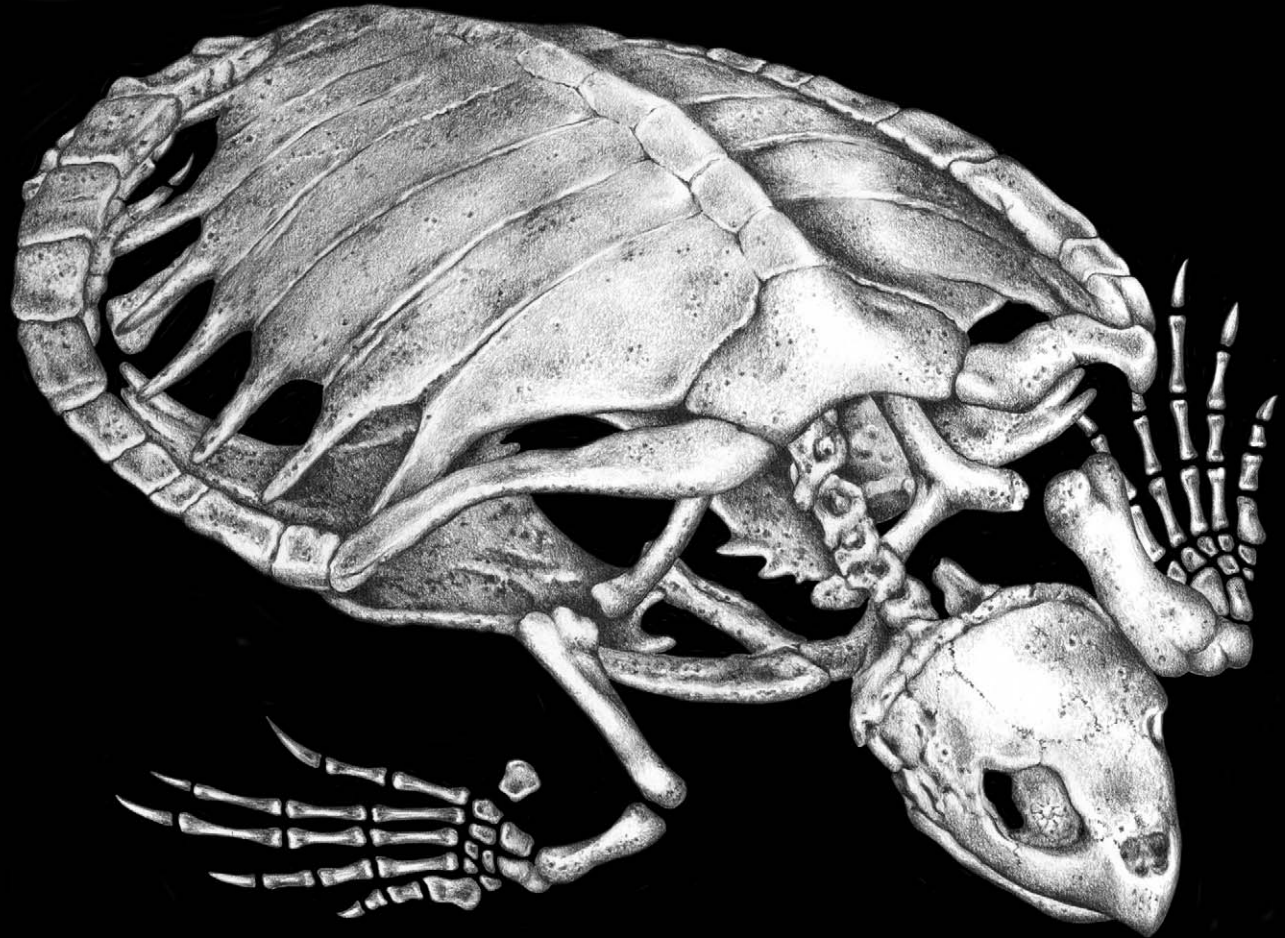
Copies of this report can be obtained from:

National Marine Fisheries Service
Southeast Fisheries Science Center
75 Virginia Beach Drive
Miami, FL 33149

or

National Technical Information Service
5285 Port Royal Road
Springfield, VA 22161
(503) 605-6000
(800) 553-6847 (rush orders)

The Anatomy of Sea Turtles



Jeanette Wyneken, Ph.D.

Illustrated by Dawn Witherington

PREFACE

The need for an up-to-date guide to the anatomy of sea turtles became clear toward the end of the 1900s. Increasing numbers of individuals developed the interest, talents, and techniques to study the biology of sea turtles, contend with their illnesses and injuries, and address the nature of sea turtle mortalities. This manual was written in response to these needs and was designed to be accessible to a variety of users. It provides a fundamental background, reference photos of normal anatomy, and diagrams to guide novice or professional biologists, stranding personnel, and veterinarians. Species identification, standard dissection techniques, standard measurements, and basic anatomy are covered with a diverse audience in mind. While this manual does not serve as a necropsy guide, it may serve as a reference when conducting necropsies. It is designed particularly with the understanding that many users will be working with it in the field or under less-than-ideal conditions. *The Anatomy of Sea Turtles* is organized so that it can be used either as a guide to dissection or as an anatomical reference to species identification, standard methods, and dissection (pp. 1-42) or as an anatomical reference to sea turtle structures or systems.

Most of the photos in this guide are by the author. However, several individuals contributed pictures that enhanced the quality of the manual. These include Larisa Avens, George Balazs, Peter Bennett, Beth Chittick, Larry Crowder, Bill Dailey, Sheryan Epperly, Craig Harms, Eve Haverfield, Bruce Homer, Chris Johnson, Ursula Keuper-Bennett, Joanne Braun McNeill, Anne Meylan, David Owens, Denise Parker, Donna Shaver, Tom Smoyer, J. Vasconcelos, and Wendy Teas. Access to specimens, dissection assistance, and/or comments on drafts of the manual were

provided by George Balazs, Ruth Boettcher, Mike Bresette, Brian Cousin, Lisa Csuzdi, Nancy DiMarco, Sheryan Epperly, Kristin Fick, Allen Foley, Jerris Foote, T.H. Frazzetta, Ellis Greiner, Craig Harms, Kristin Hart, Hector Horta, Elliott Jacobson, Chris Johnson, Ken Kardong, Jennifer Keller, Kate Kelso, Greg Lewbart, Peter Lutz, Charles Manire, Carol Hardy McFadden, Joanne Braun McNeill, Nancy Mette, Jeff Miller, Debra Moore, Steve Morreale, David Owens, Joe Parsons, Robert Prescott, Peter C. H. Pritchard, Tony Redlow, Anders Rhodin, Kurt Rusenko, Cheryl Ryder, Michael Salmon, Karrie Singel, Melissa Snover, Trish Sposato, Fred Steinberg, Kelly Stewart, Wendy Teas, Mike Walsh, James Weege, Pat Wells, Donna Weyrich, Dale Wilke, Blair Witherington, Wayne Witzell, and Larry Wood. The Cayman Turtle Farm, Chelonian Research Institute, Florida Fish and Wildlife Conservation Commission, Gumbo Limbo Environmental Center, Harbor Branch Oceanographic Institution, The Marinlife Center of Juno Beach, Mote Marine Laboratory, Philadelphia Academy of Sciences, National Marine Fisheries Service-Beaufort Laboratory, National Marine Fisheries Service-Miami Laboratory, North Carolina Wildlife Commission, University MRI, Inc., and the U.S. Fish and Wildlife Service provided access to specimens and logistical help.

Many individuals provided thoughtful discussions during the preparation of this manual and *The Anatomy of Sea Turtles* video. The quality and coverage of *The Anatomy of Sea Turtles* was greatly improved by their attention and suggestions.

This manual's illustrations and layout are by Dawn Witherington.

PHOTOGRAPHIC CREDITS

The following people contributed photos that enhanced the quality of this manual. Where known, turtle tag numbers or their identifications are also provided.

Ursula Keuper-Bennett and Peter Bennett: Figs. 11, Tutu; Fig. 20, Ake

Beth Chittick: Fig. 145

Larry Crowder: Fig. 141

Bill Dailey: Fig. 21

Craig Harms: Figs. 81, 161, 187

Bruce Homer: Fig. 176

Chris Johnson: Figs. 9, 17

Heather Kalb and David Owens: Fig. 234

Joanne Braun McNeill: Fig. 15

Anne Meylan: Fig. 77

Peter C. H. Pritchard: Fig. 189

Tom Smoyer (Harbor Branch Oceanographic Institution): Figs. 10, 12, 13, 14, 19, 31, 45, 58, 70, 71, 90, 106, 229

J. Vasconcelos: Fig. 24

TABLE OF CONTENTS

Basic Terminology and Characters for Species Identification.....	1
Species Identification	4
Skull Anatomy	8
Species Identification from Skulls	13
Rhamphotheca Structure	26
Standard Measurements	28
Methods of Dissection	33
Skeletal Anatomy	43
Muscle Anatomy	59
Circulatory Anatomy	74
Lung and Airway Anatomy	105
Gastrointestinal Anatomy	108
Glands	115
Nervous System.....	125
Sense Organs	146
Urogenital System.....	153
Selected Bibliography.....	166
Index	169

Anatomical Terminology

There are several terms used here that describe the spatial relationships of structures. Below, these are defined specifically for sea turtles (Figs. 1-2).

Dorsal is toward the top of the shell (the carapace).

Ventral is toward the plastron.

Anterior is toward the head.

Posterior is toward the tail.

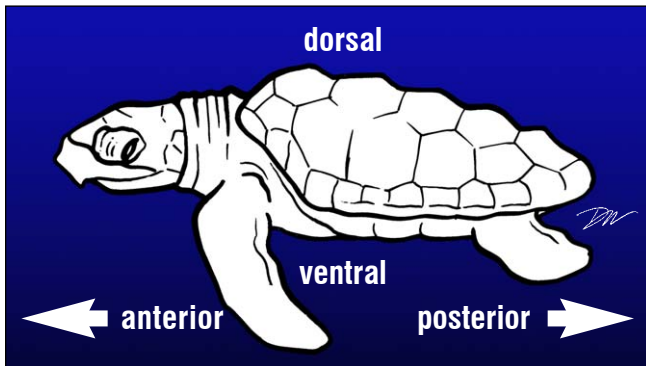


Fig. 1. Anatomical terminology.

Medial is toward the midline.

Lateral is away from the midline, toward the sides.

Proximal is close to the body or the start of a structure.

Distal is away from the body or main structure.

Deep to is underneath a structure

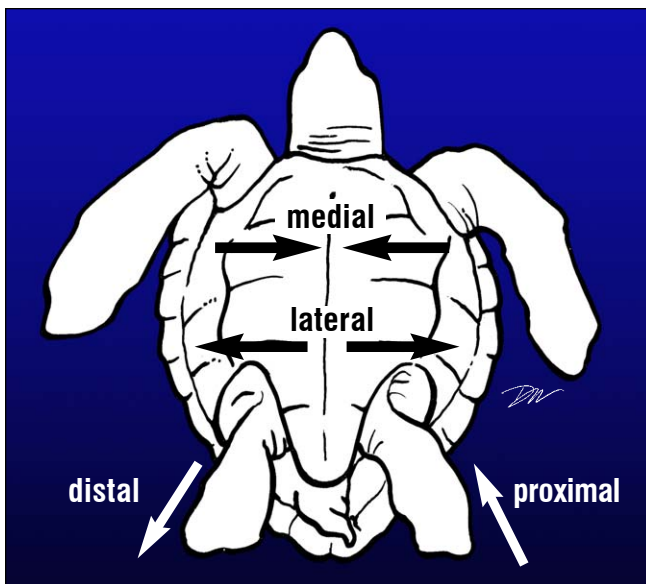


Fig. 2. Relative anatomical position.

Characters for Species Identification

Sea turtle identification, from external characters, is based upon the scales on the head, form of the jaws, the number of claws on the feet, and the numbers and arrangement of the plates or scutes on the shell. The scutes of the carapace (the top shell) are numbered from front to back (Fig. 3). The primary scutes (Fig. 4) used as key characteristics are the **marginals**, **laterals (costal)**, **vertebrals**, and **nuchal**, as well as the **inframarginal** or bridge scutes.

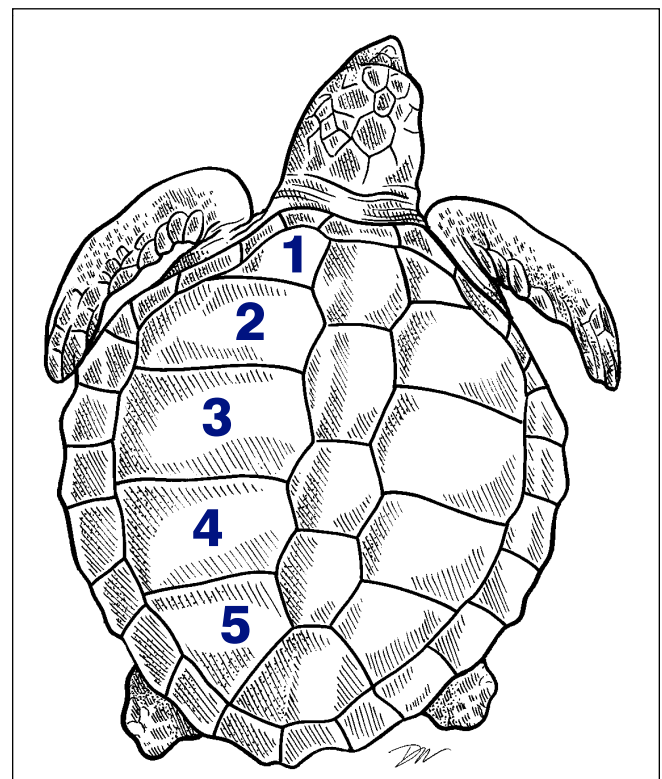


Fig. 3. Numbering the carapace scutes.

The bottom shell is the **plastron**. It also has distinct scute patterns, but these are used more often as landmarks for internal structures than for species identification (Fig. 5). From anterior to posterior, the **intergular** scute is closest to the neck, then (in order) are the **gular**, **humeral**, **pectoral**, **abdominal**, **femoral** and the **anal** scutes. Some individuals have a single unpaired **interanal scute** that is found between or posterior to the anal scutes.

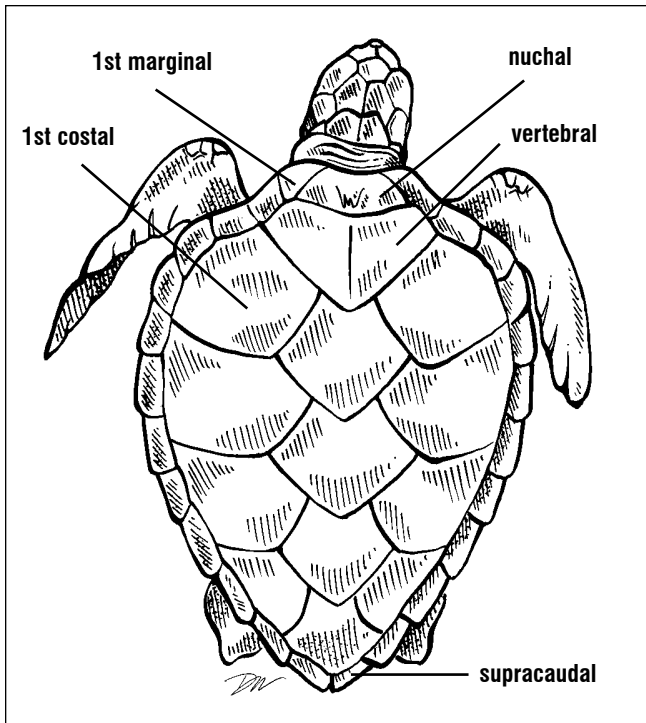


Fig. 4. Scutes of the carapace.

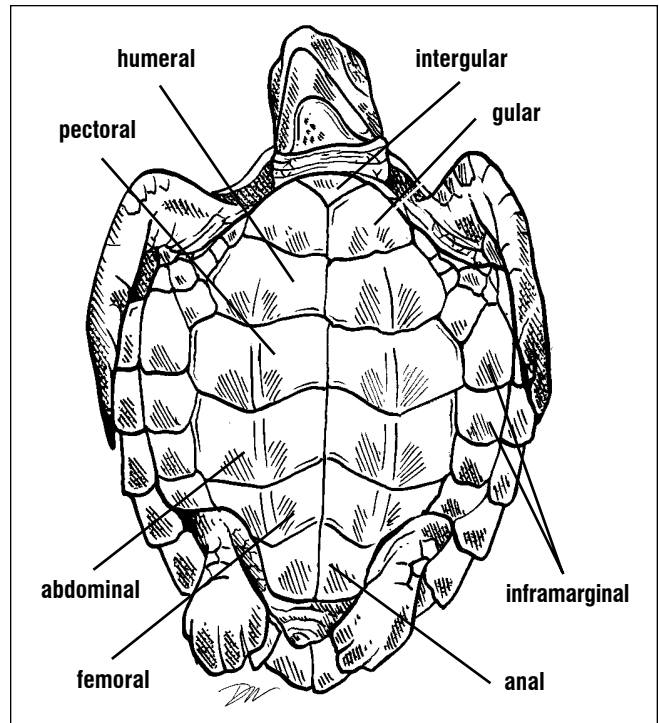


Fig. 5. Scutes of the plastron and bridge.

Scutes of the carapace and plastron. The lateral scutes are also known as costals or pleurals. The last marginal scutes on each side are termed supracaudals or postcentrals (Fig. 4). The scutes between the plastron and the carapace are the

Cheloniidae (hard-shelled sea turtles) are characterized by the scales on the head, carapace, and inframarginal scute patterns and numbers, as well as the numbers of claws on the flippers (Figs. 6-7). Most species have 2 claws. Claw I is

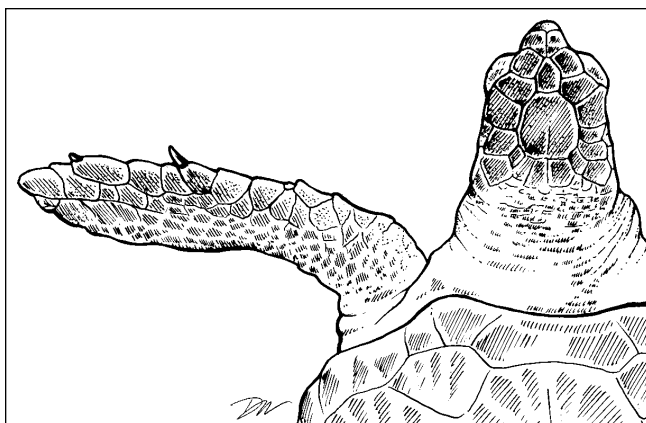


Fig. 6. Position and numbering of claws.

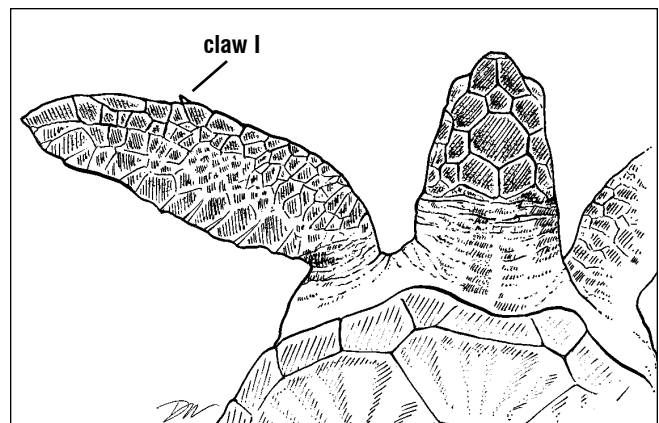


Fig. 7. The single claw occurs on the first digit. No claw forms on the second digit.

inframarginals (Fig. 5). While the number of inframarginals is somewhat variable, the most common count is often listed as a key characteristic.

usually larger than claw II and becomes strongly curved in adult males. The number of claws on the front and hind limbs is the same.

CHARACTERS FOR SPECIES IDENTIFICATION

Leatherbacks lack both distinctive head scales as adults and have minimal keratin covering on the jaws. The hard-shelled sea turtles have keratinous scales on the dorsal and lateral head that are used in identification of species (Fig. 8). The **prefrontal** scales occur in pairs. One or more **supernumerary** scales may occur along the midline and separate the pairs. Other head scales (**supraocular**, **postocular**, **frontal**, **frontoparietal**, **parietal**, **interparietal**, **temporal**, and **tympanic scales**) may vary slightly in form but not in position relative to one another. In some cases, individual variations in the head

scales can be used to identify individual turtles.

A key to the species is found on the next page. It summarizes species identification using external characteristics.

Several internal bony and jaw (rhamphotheca) characters also may be used for species identification. These are described later (Species Identification from Skulls, pp. 13-25; Rhamphotheca Structure, pp. 26-27; Skeletal Anatomy, pp. 50-51).

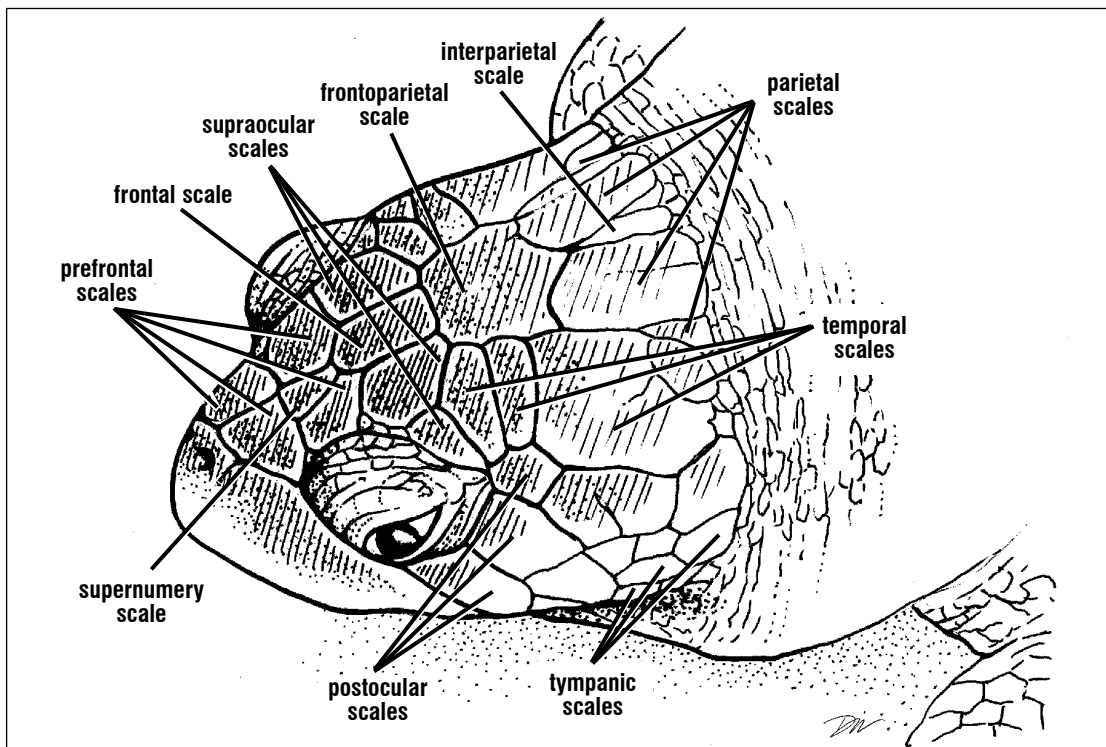
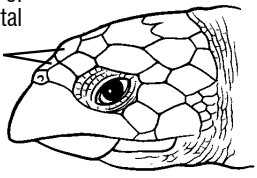
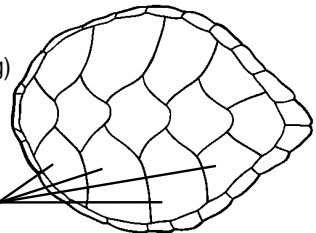
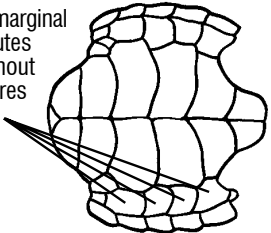
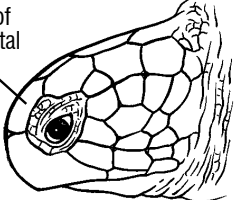
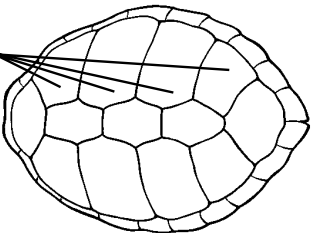
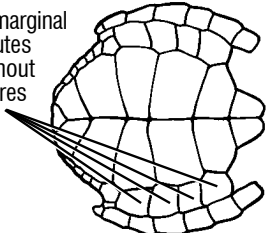
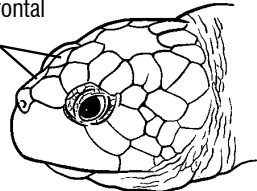
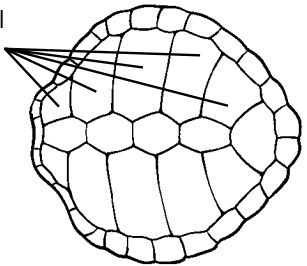
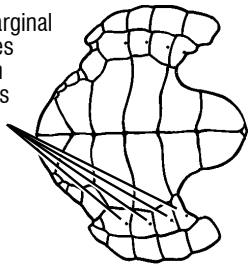
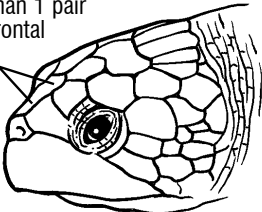
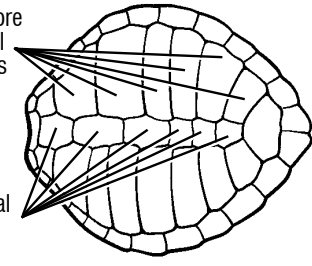
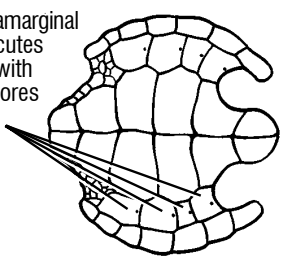
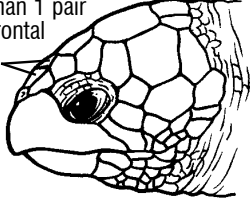
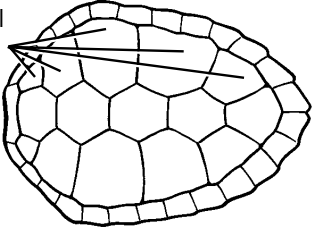
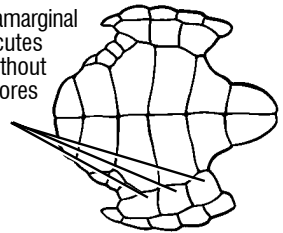

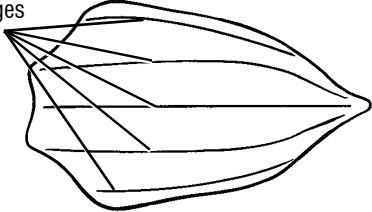
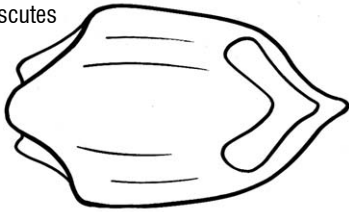


Fig. 8. Head scales of cheloniid turtles. The major sets of scales used in species identification are the prefrontals. There are often supernumerary scales (multiple extra scales) between the prefrontals. These lack pattern and are usually small. The other labeled scales serve as landmarks.

SPECIES IDENTIFICATION

head	carapace	plastron
<p>2 pairs of prefrontal scales</p> 	<p>scutes imbricated (overlapping)</p> <p>4 lateral scutes</p> 	<p>4 inframarginal scutes without pores</p> 
<p>Hawksbill - <i>Eretmochelys imbricata</i></p>		
<p>1 pair of prefrontal scales</p> 	<p>4 lateral scutes</p> 	<p>4 inframarginal scutes without pores</p> 
<p>Green turtle - <i>Chelonia mydas</i></p>		
<p>more than 1 pair of prefrontal scales</p> 	<p>5 lateral scutes</p> 	<p>4 inframarginal scutes with pores</p> 
<p>Kemp's ridley - <i>Lepidochelys kempii</i></p>		
<p>more than 1 pair of prefrontal scales</p> 	<p>6 or more lateral scutes</p> <p>6 or more vertebral scutes</p> 	<p>4 inframarginal scutes with pores</p> 
<p>Olive ridley - <i>Lepidochelys olivacea</i></p>		
<p>more than 1 pair of prefrontal scales</p> 	<p>5 lateral scutes</p> 	<p>3 inframarginal scutes without pores</p> 
<p>Loggerhead - <i>Caretta caretta</i></p>		
<p>no scales</p> 	<p>ridges</p> 	<p>no scutes</p> 
<p>Leatherback - <i>Dermochelys coriacea</i></p>		

Species Identification

Sea turtles can be separated into the hard-shelled (cheloniid) and the leathery-shelled (dermochelyid) species. There is just one dermochelyid species, the leatherback, *Dermochelys coriacea* (Figs. 9-10). It is black with white speckling. Five dorsal ridges run the length of the carapace, two ridges form the margins, and few ridges occur ventrally. A notch occurs in each side of the upper jaw and the limbs lack claws.



Fig. 9. *Dermochelys coriacea*, adult.



Fig. 10. *Dermochelys coriacea*, hatchling.

The cheloniids can be distinguished from one another by the scales on top of the snout, called the prefrontals and by the scutes on the carapace. The green turtle, *Chelonia mydas* (Figs. 11-13), has one pair of prefrontal scales (Fig. 12). The carapace is smooth with 4 pairs of lateral scutes. Carapace color changes with age. It is black in hatchlings, then turns brown and tan in juveniles, and in adults, it is olive or gray-green, sometimes with speckles of yellow and brown. The plastron is white in hatchlings. It turns creamy yellow, sometimes temporarily pink or gray depending on the population.

Adults have a creamy yellow plastron except in the more melanistic green turtles (referred to as black turtles) found in some Pacific waters. The green turtle has one claw on each limb. There are 4 inframarginal scutes on each side and two Rathke's pores, one each in the axillary and inguinal scales (see Glands, pp. 122-123).



Fig. 11. *Chelonia mydas*, adult.



Fig. 12. *Chelonia mydas*, juvenile.



Fig. 13. *Chelonia mydas*, hatchling.

SPECIES IDENTIFICATION

The remaining species have 2 pairs of prefrontal scales (Fig. 8) and, as young, they have keels (ridges) on their shells. The loggerhead, *Caretta caretta* (Figs. 14-17), has a large head and brown carapace with 5, or sometimes 4, lateral scutes. The nuchal scute (the marginal just dorsal to the neck) is in contact with the first lateral scute. In hatchlings, the carapace is brown with various shades of grey (Fig. 14). The plastron of hatchlings is creamy to brown. In juveniles to adults it is creamy and tan. The carapaces of juveniles (Fig. 16) develop streaks of yellow and tan. Sometimes the scutes of juveniles slightly overlap one another at their margins. In adults, there is no overlap of scutes. The carapace is primarily brown with occasional individuals retaining some tans or even black (Fig. 17). The shells of loggerheads often host large epibiont communities. Loggerheads have two claws on each limb.



Fig. 14. *Caretta caretta*, hatchling.



Fig. 15. *Caretta caretta*, plastron. Loggerheads often have 3 inframarginals however, this characteristic is variable.



Fig. 16. *Caretta caretta*, immature. Immature loggerheads often have sharp keels on their vertebral scutes and posterior marginal. These recede with larger size and age so that loggerheads found in coastal waters often bear little of or no signs of the keels.



Fig. 17. *Caretta caretta*, adult. The jaws have thick, robust rhamphotheca (beak-like structures) for crushing food.

The hawksbill, *Eretmochelys imbricata*, as a hatchling, is dark mahogany brown on both the carapace and the plastron (Fig. 18). As the turtle grows, the head elongates and the carapace develops a distinctive pattern of yellow, black, tan and brown radiating through the scutes (Fig. 19). This color persists though adulthood. The nuchal scute does not touch the first lateral scute in hawksbills. This distinguishes the hawksbill carapace from the loggerhead pattern. The head of the hawksbill is nearly twice as long as it is wide and has a long narrow beak or **rhamphotheca** (Fig. 20). Hawksbills have two claws on



Fig. 18. *Eretmochelys imbricata* hatchling (left) and *Caretta caretta* hatchling (right). Note that the nuchal scute touches the first lateral in loggerheads but not in hawksbills.



Fig. 19. *Eretmochelys imbricata*, immature. The narrow head and imbricate (overlapping) scutes of the hawksbill are clear.



Fig. 20. *Eretmochelys imbricata*, adult.

The last two species that occur in U.S. waters are the ridleys (Figs. 21-24). These turtles are mostly gray in color. The Kemp's ridley, *Lepidochelys kempii*, occurs in east coast waters. The olive ridley, *Lepidochelys olivacea* occurs in Pacific and South Atlantic waters (but occasionally strays into tropical North Atlantic regions). The hatchlings of both species are gray-brown.



Fig. 21. *Lepidochelys kempii*, adult

The carapace assumes a nearly round appearance as the turtle grows and the marginal scutes become wide (Fig. 21). There are 4 (sometimes 3) inframarginal scutes. Characteristic pores are found within each inframarginal scute (Fig. 22) in both ridley species. Ridley turtles have two claws on each limb.

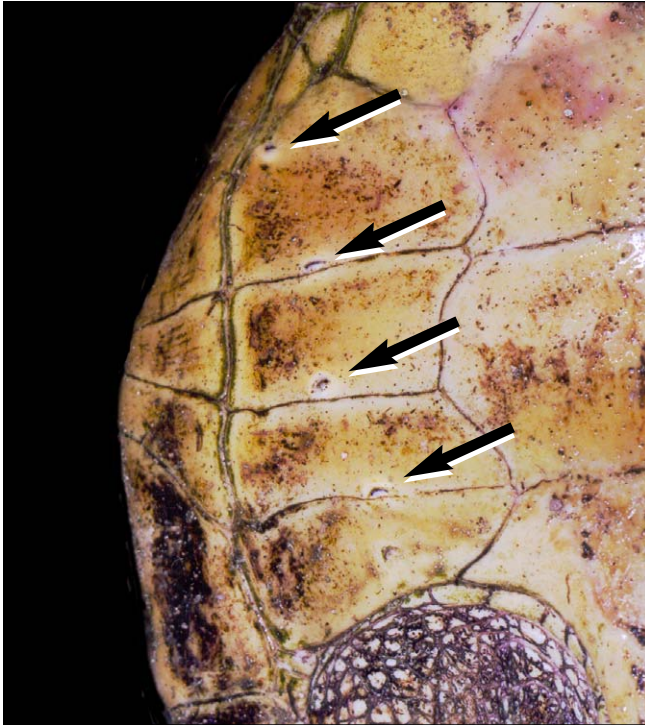


Fig. 22. *Lepidochelys* *inframarginals* with Rathke's pores.

Kemp's ridley turtles are dark grey to grey-green in color. They have 5 lateral scutes (4-6 is common).




Fig. 23. *Lepidochelys* *hatchlings*. *L. kempii* (right) has just 5 lateral and vertebral scutes while *L. olivacea* (left) has 6 or more lateral and vertebral scutes.

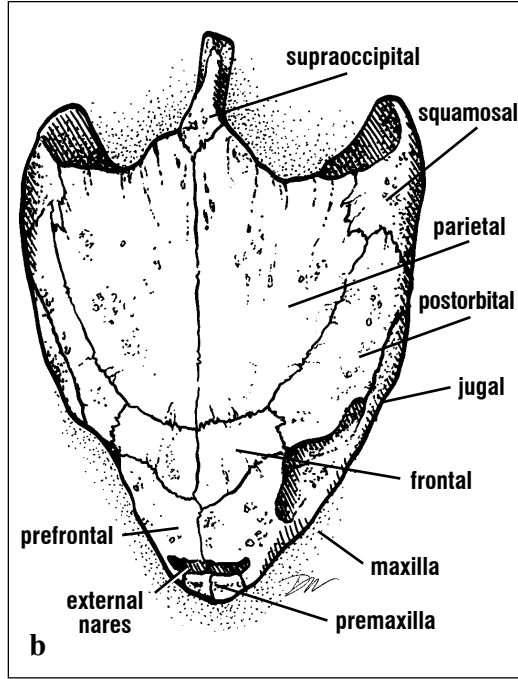
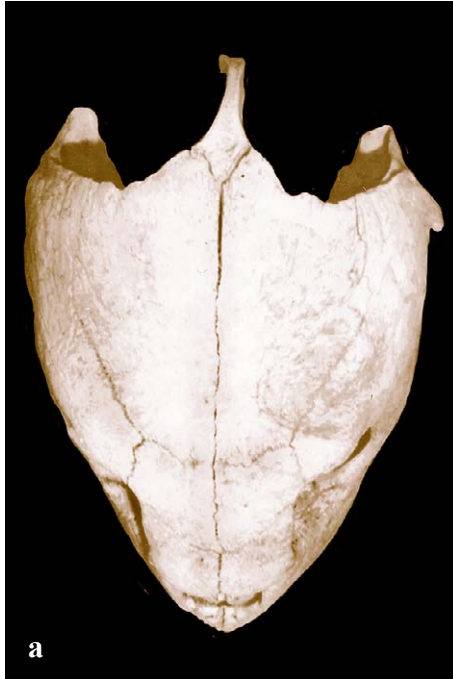Olive ridleys turtles are dark grey. They typically have more than 6 normally aligned lateral scutes, 6 or more normally aligned vertebral scutes (Fig. 23) and many supraocular scales (Fig. 24).



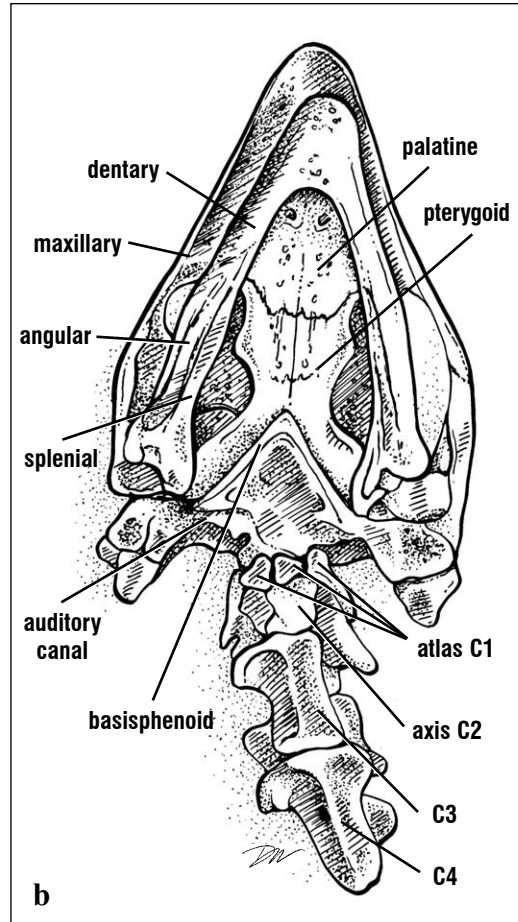
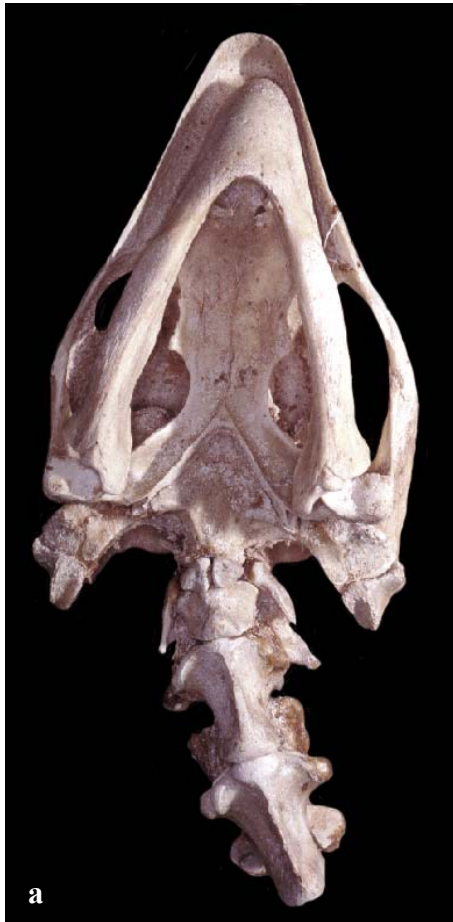Fig. 24. *Lepidochelys olivacea*, adult

Skull Anatomy

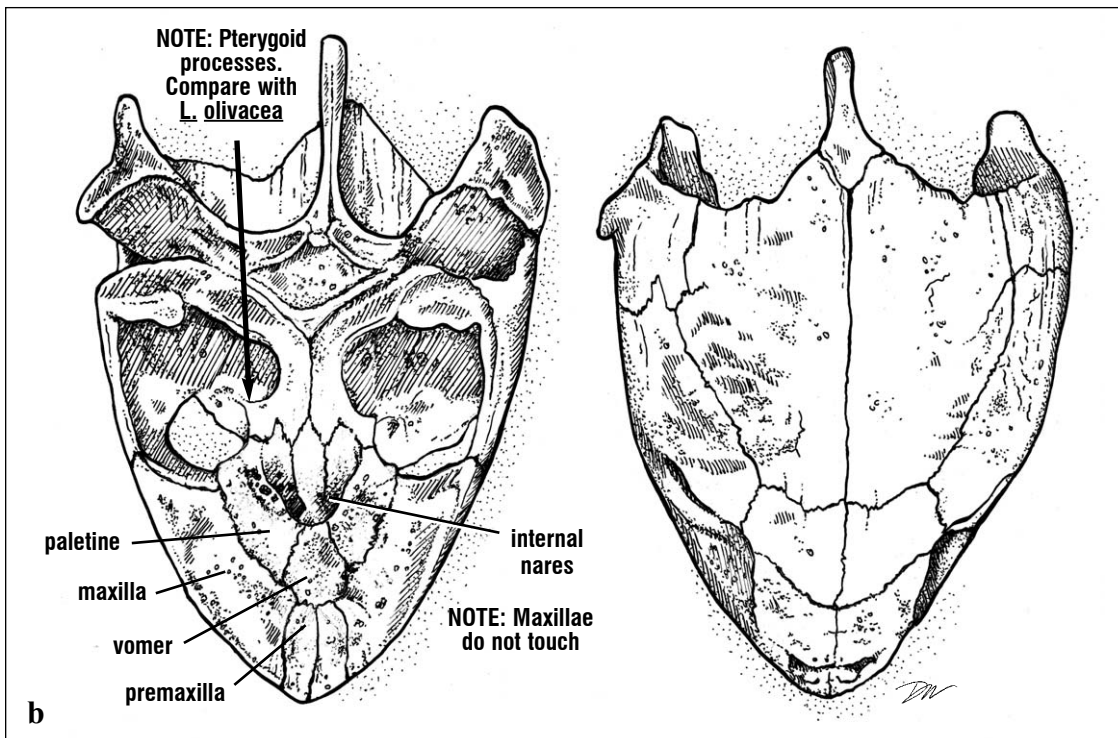
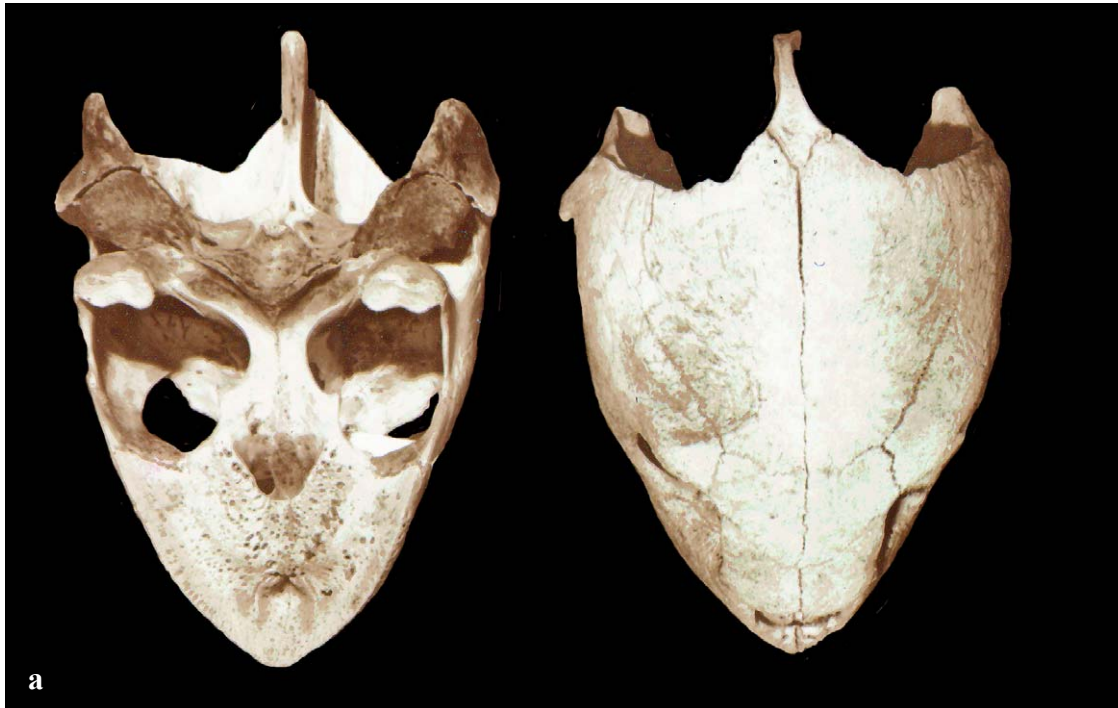The skull is organized into an inner braincase, the **neurocranium**, which houses the brain and an outer bony superstructure, the **splanchnocranium**. The anterior splanchnocranium along with the mandibles form the jaws. The splanchnocranium also houses the sense organs and provides the muscle attachment sites for jaw, throat and neck muscles. The braincase is found along the midline, internal to the skull roof, snout, and jaw bones of the splanchnocranium. The external bones of the splanchnocranium (Fig. 25) are the same in all species, however their specific form and some articulations differ. Skull shape and the patterns of bones of the palate (roof of mouth; Figs. 26-27) are diagnostic for species identification. Lateral bones (Fig. 28) are important landmarks for locating internal structures. The jaws (Fig. 26) and the neurocranium (Fig. 29), also are composites of several bones.



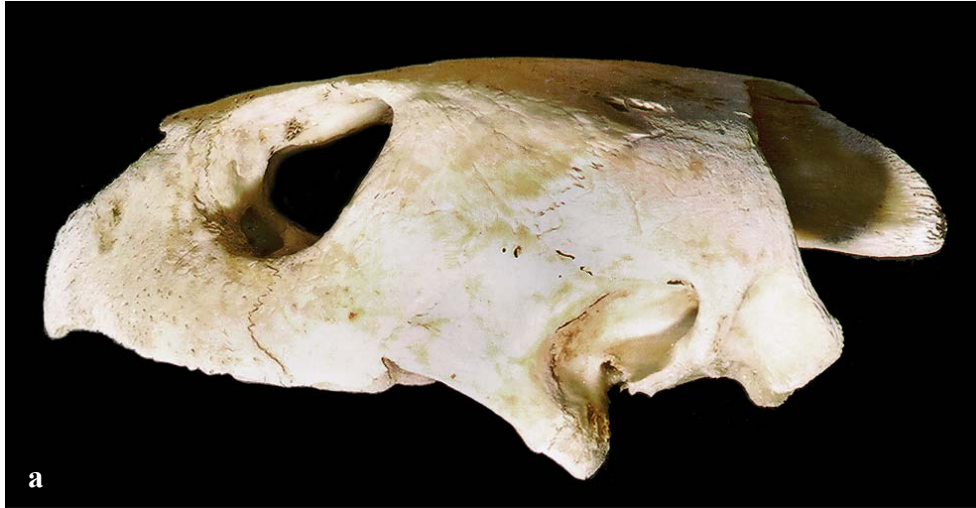Figs. 25a and 25b. The dorsal and lateral bones are identified here. With the exception of the supraoccipital, these are bones of the splanchnocranium.



Figs. 26a and 26b. Ventral bones of the skull (with the hyoid skeleton of the throat removed) are shown with the lower jaw and anterior neck vertebrae articulated. Both the upper and lower jaws are composed of multiple bones. The posterior braincase, part of the neurocranium, articulates with the cervical vertebrae. The vertebrae are composed of several parts: a vertebral body or centrum located ventrally and dorsal arch elements. C1 - C4: Cervical vertebrae.



Figs. 27a and 27b. The specific articulations and forms of the bones are characteristic of each species. The bones that make up the palate are frequently used as key characteristics. For example, in this ridley skull, the vomer prevents the maxillae from touching. In the loggerhead, a grossly similar skull, the vomer does not reach the premaxillae, so the maxillaries articulate. The pterygoid process shape and position are also key characteristics.



Figs. 28a and 28b. *The lateral bones, identified on this cheloniid skull, vary in form with species. The eye would be housed in the orbit and the auditory canal (ear) would occupy the notch posterior to the quadratojugal.*

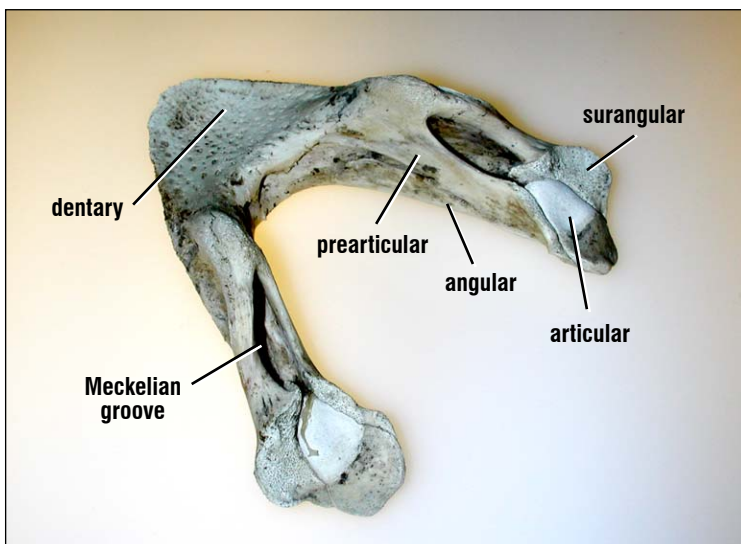
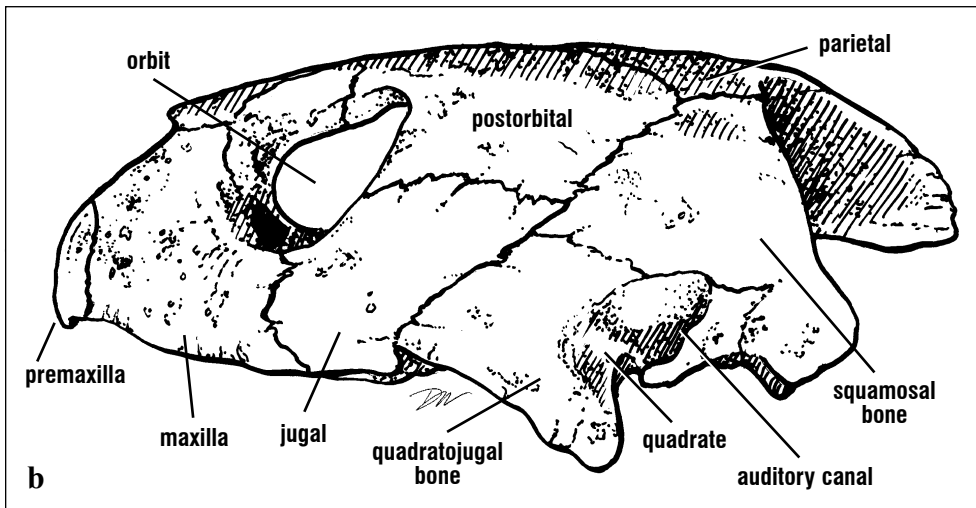
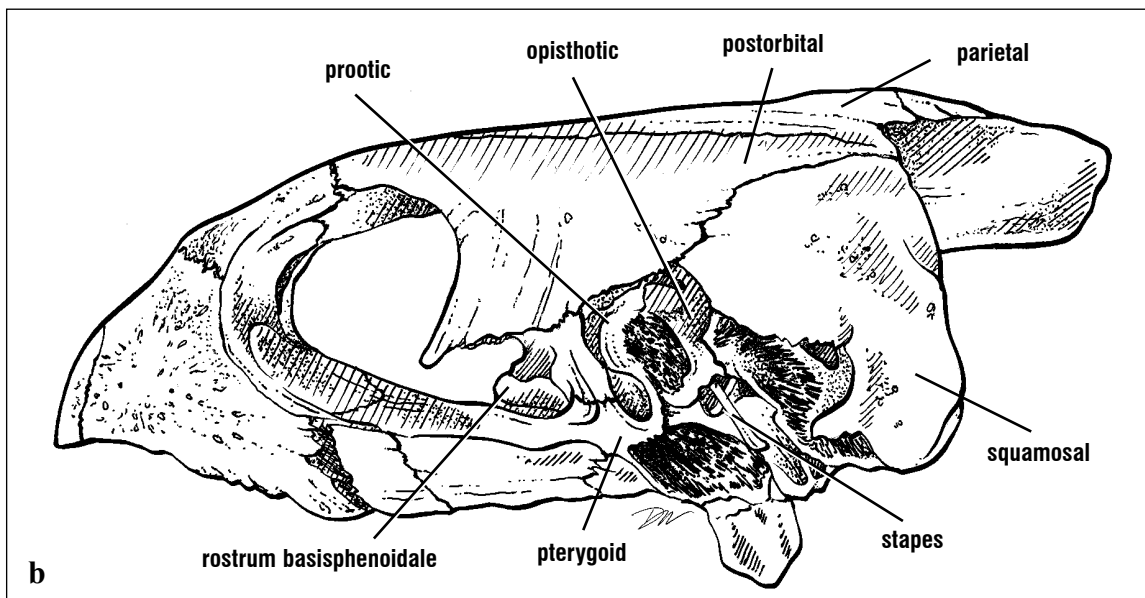
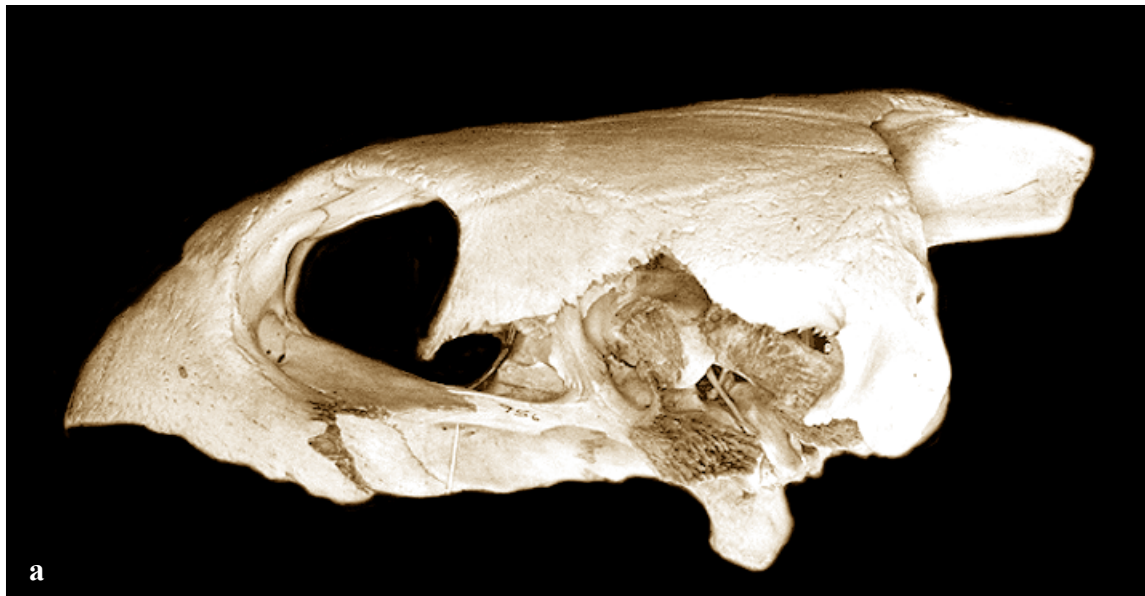


Fig. 29. *The lower jaw is a composite of the dentary, angular, surangular, prearticular, splenial (not shown) and articular bones. The cartilaginous portion is Meckel's cartilage; it is found in the Meckelian groove in life.*



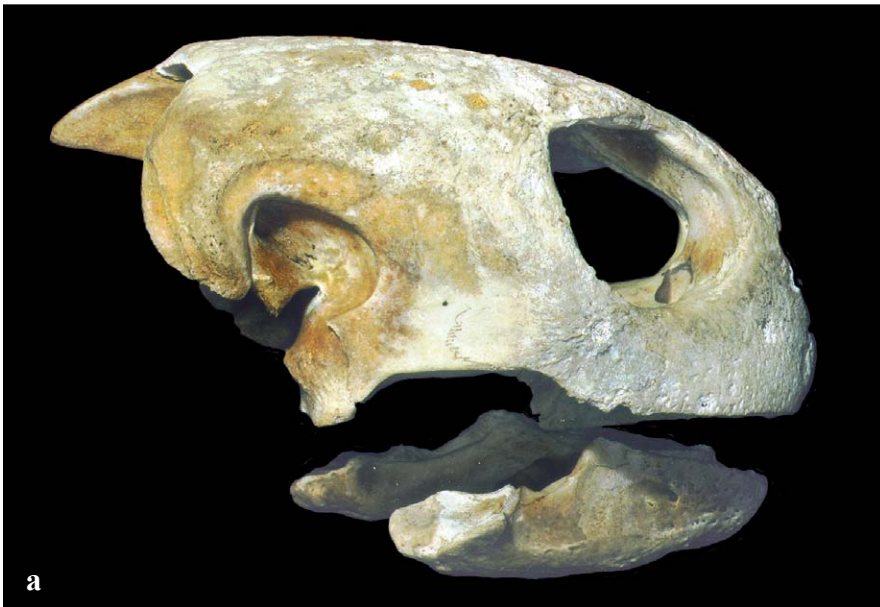Figs. 30a and 30b. *The neurocranium is partially exposed by the removal of the jugal, quadratojugal, and quadrate of a hawksbill skull. The braincase is small and housed internal to the skull roof. Anterior bones (rostrum basisphenoidale and pterygoid) and lateral bones (prootic and opisthotic) form walls of the braincase.*

Species Identification from Skulls

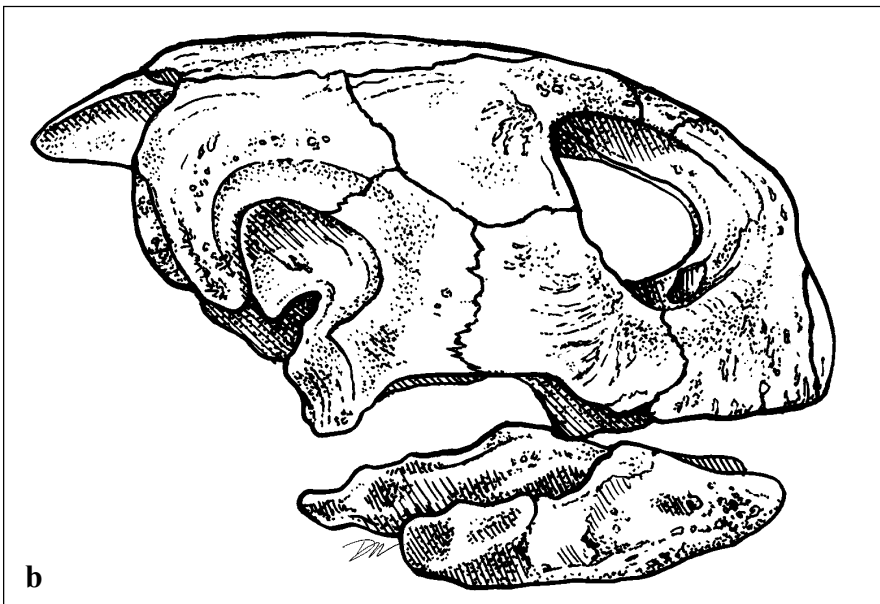
The following descriptions are based upon bony characteristics alone and do not include other diagnostic features of the scales or the form of the rhamphotheca (keratinaceous beak, see Rhamphotheca Structure, pp. 26-27).

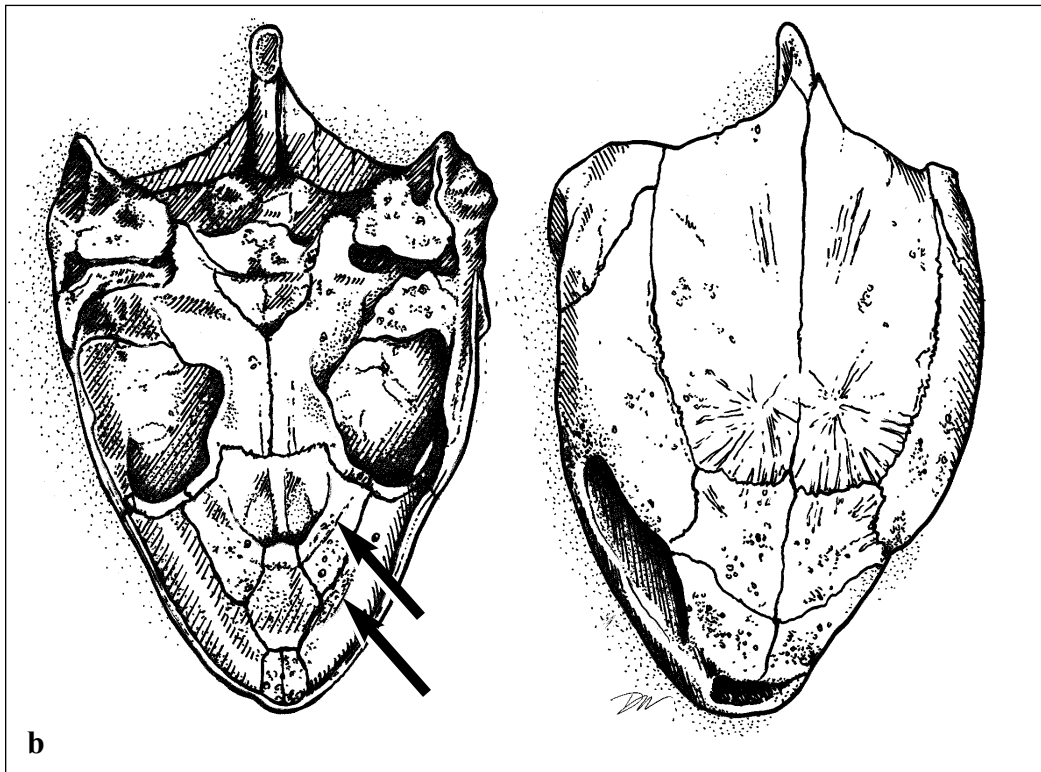
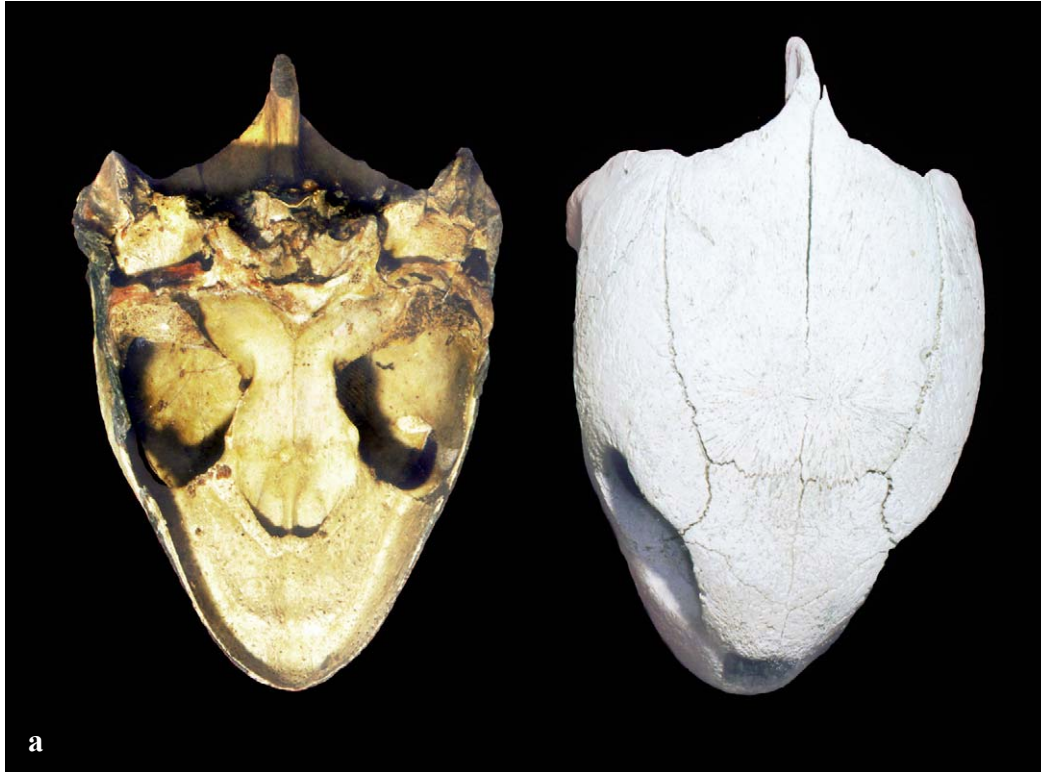Chelonia mydas (Figs. 31 - 33). The skull is rounded with a short snout and shallow parietal

notches (Fig. 31). The upper jaw is described by a smooth U-shaped outline; the palate between the margins of the upper jaw and the internal nares (the alveolar surface) has a pair of ridges that run parallel to the outer edge of the jaw (Fig. 32). The lower jaw, has a ridge running parallel to the inner surface (Fig. 33) and a midline cusp.

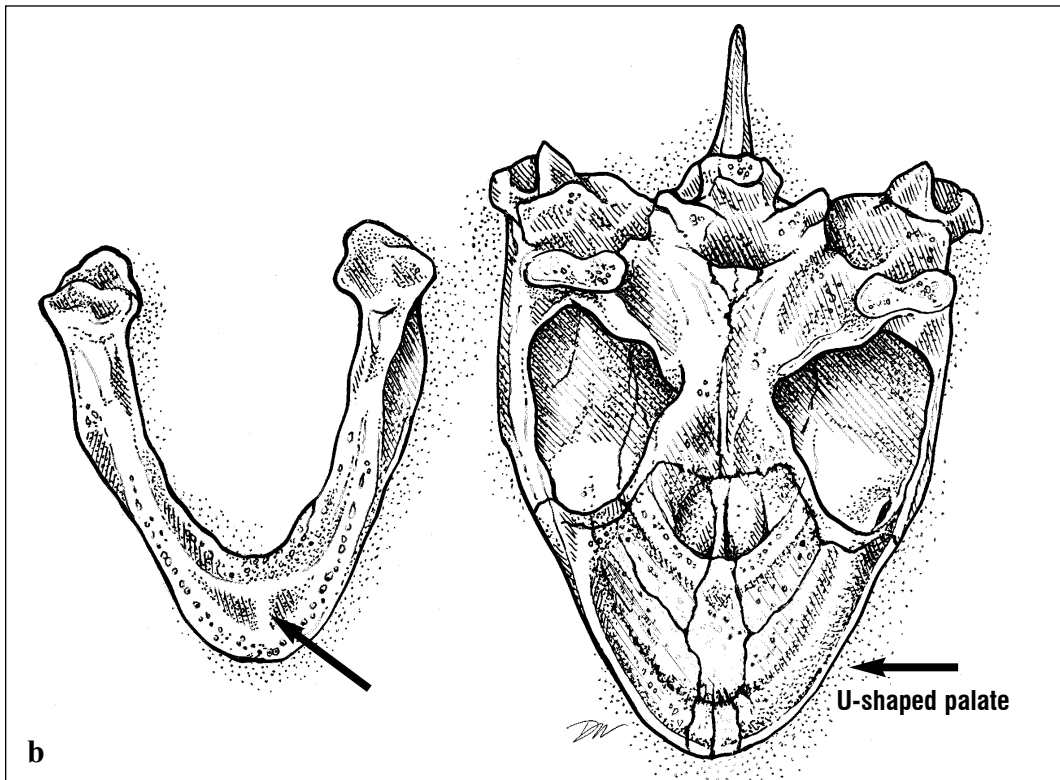
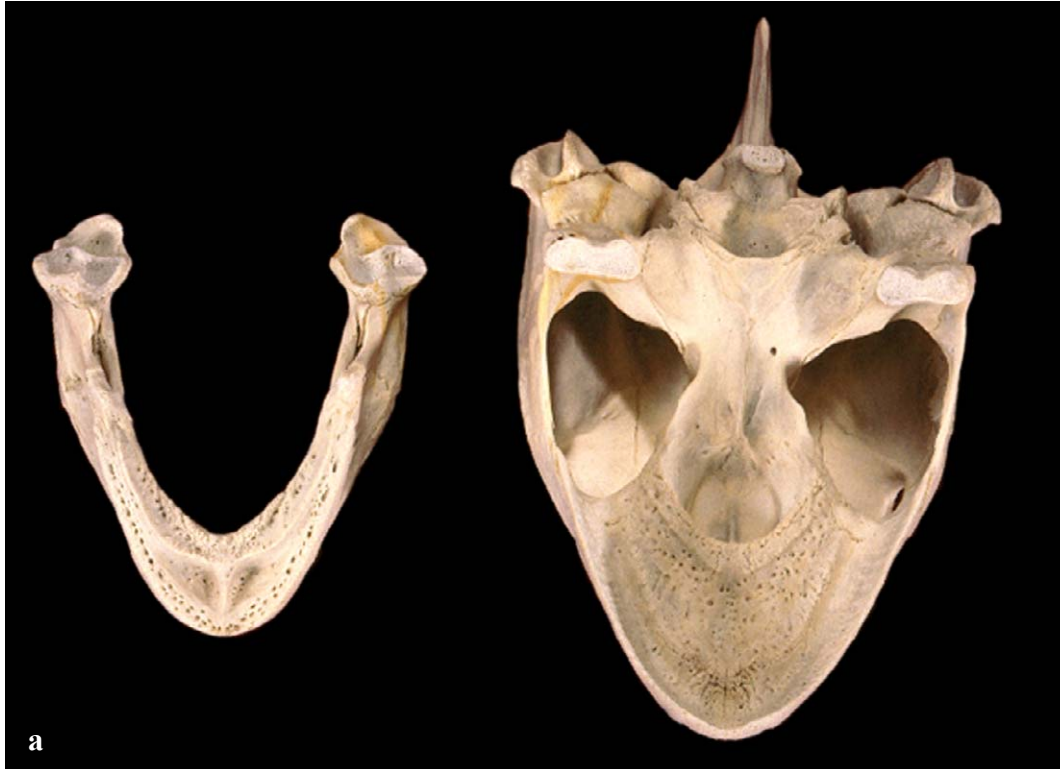

Figs. 31a and 31b. *Chelonia mydas*, lateral view.





Figs. 32a and 32b. *Chelonia mydas*, dorsal and ventral skull. Note ridges on palate at arrows.

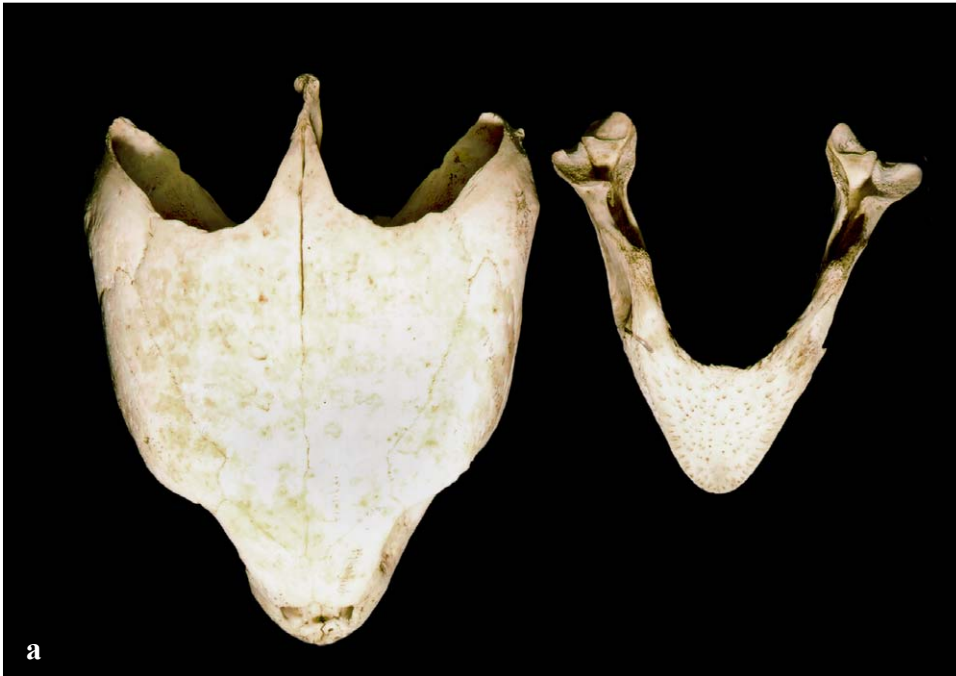

Figs. 33a and 33b. *Chelonia mydas*, ventral skull and lower jaw. Midline cusp of lower jaw at arrow.

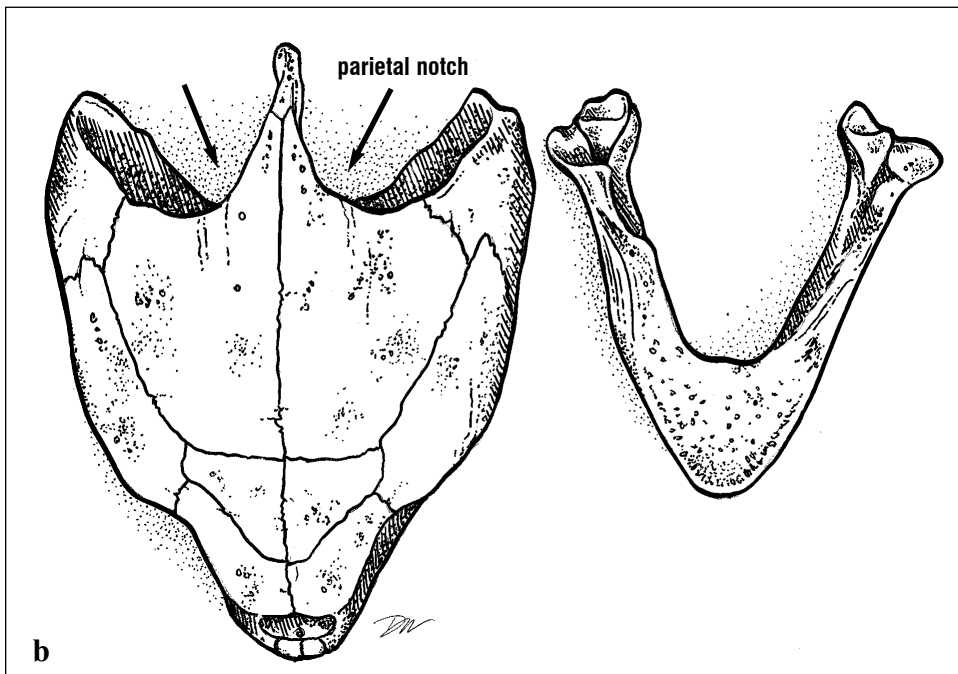
SPECIES IDENTIFICATION FROM SKULLS

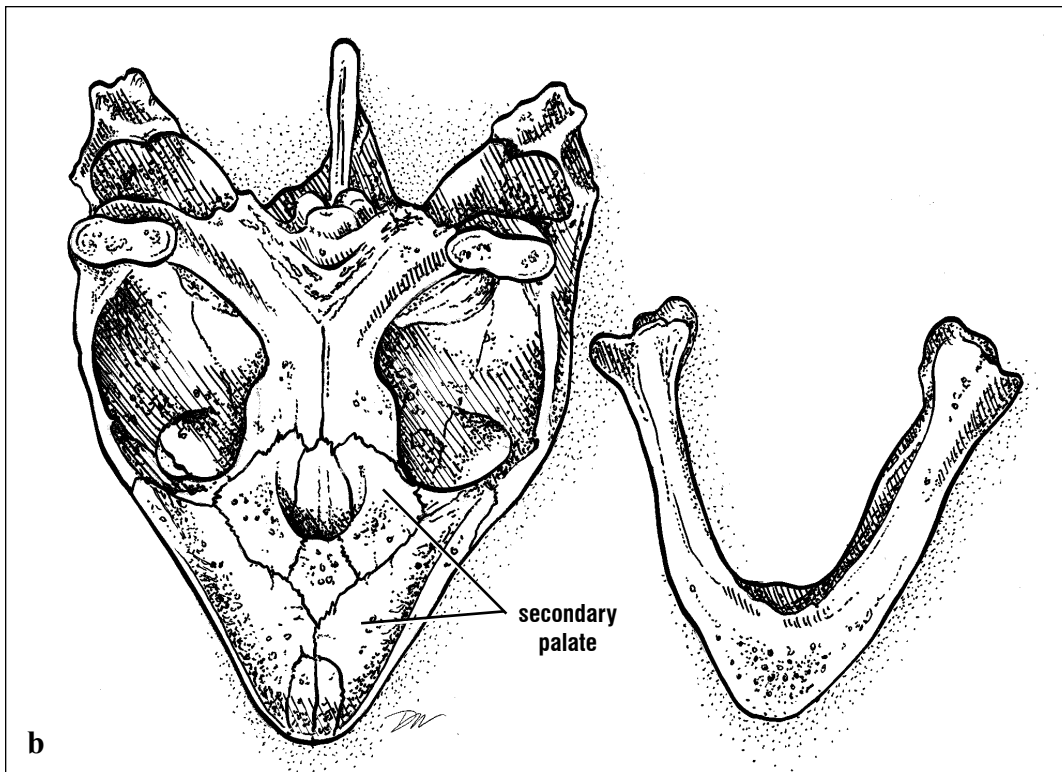
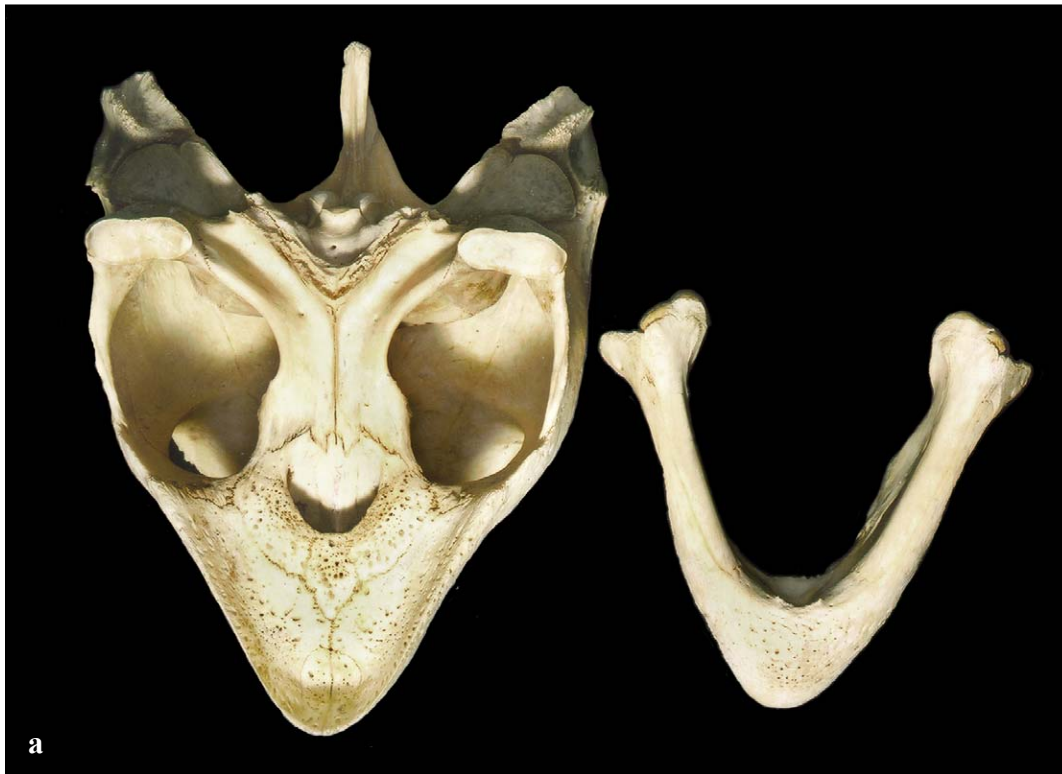Caretta caretta (Figs. 34 and 35). The head of the loggerhead is relatively large, wide posteriorly, and the snout tapers anterior to the orbits. The parietal notches (wide U-shape emarginations formed by the posterior borders of the squamosal, parietal and supraoccipital bones) are large (Fig. 34). The jaws are robust and

shaped like a wide V. Loggerheads have a relatively long secondary palate. (The secondary palate is the shelf of bone that separates or partially separates food and air passages.) The palate lacks alveolar ridges and the two maxillary bones contact one another posterior to the premaxillary bones (Fig. 35).



Figs. 34a and 34b. *Caretta caretta*, dorsal skull and lower jaw. Parietal notches are at arrows.



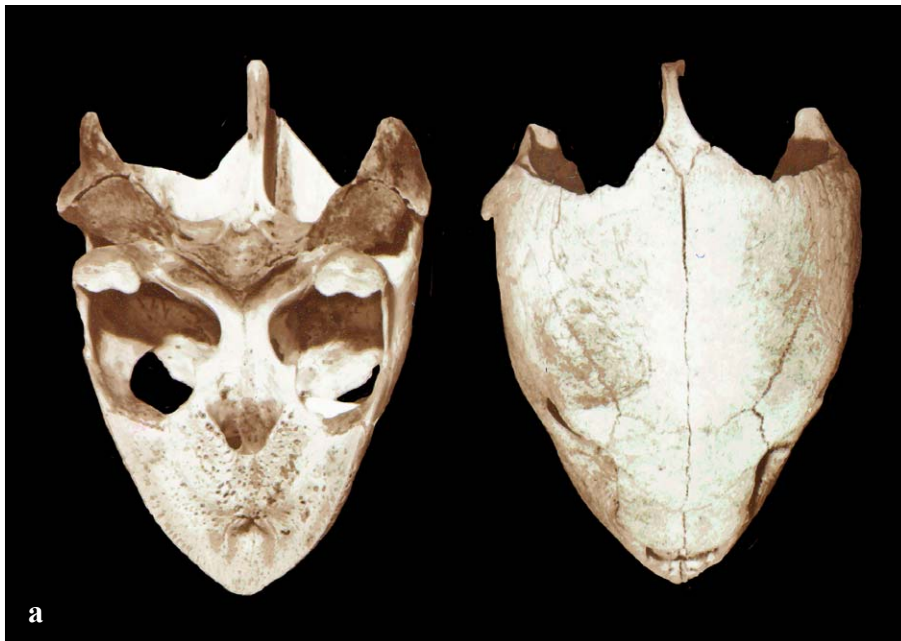

Figs. 35a and 35b. *Caretta caretta*, ventral skull and lower jaw. Note that the two maxillary bones touch at the middle of the palate.

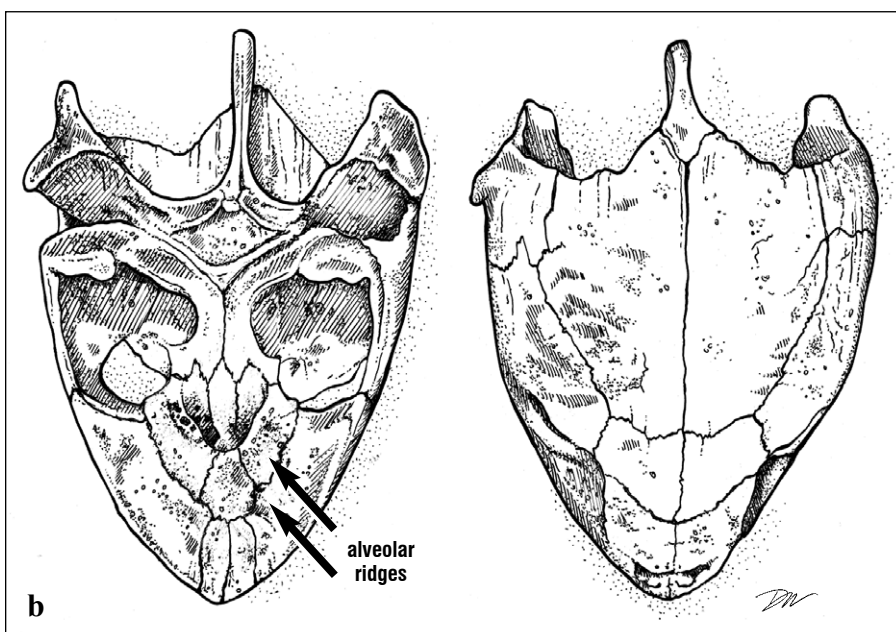
SPECIES IDENTIFICATION FROM SKULLS

***Lepidochelys kempii* (Fig. 36).** The skull is similar in overall shape to that of the loggerhead but can be distinguished from the loggerhead by the features of the palate. The Kemp's ridley skull is roughly triangular in shape. The parietal notches are well developed (Fig. 36). The snout tapers anterior to the orbits. The jaws are shaped like a wide curved V and there is a relatively long secondary palate.

The palate has longitudinal alveolar ridges and the two maxillary bones are separated by the vomer which extends anteriorly to articulate with the premaxillary bones (Figs. 27 and 36). The orbits are relatively small when compared with other species and each has a ridge of bone along its dorsal margin that extends laterally from the anterior portion of the postorbital bone.



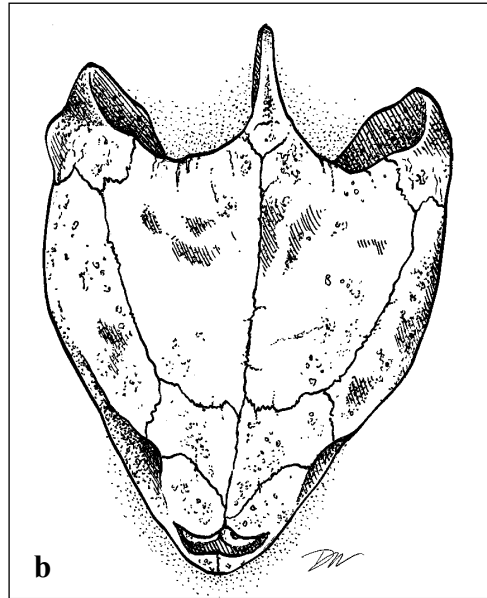
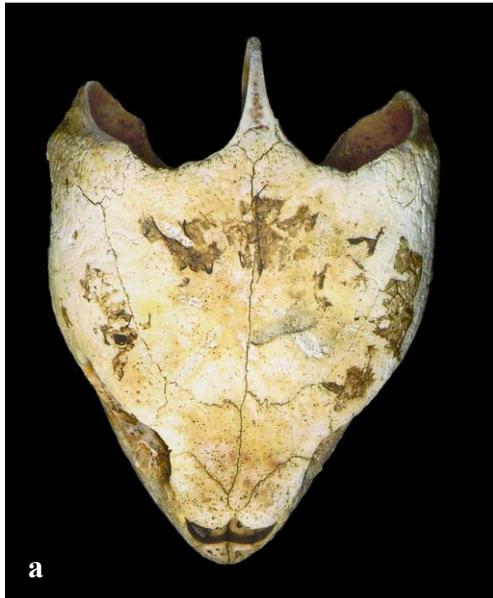Figs. 36a and 36b. *Lepidochelys kempii*, dorsal and ventral skull.



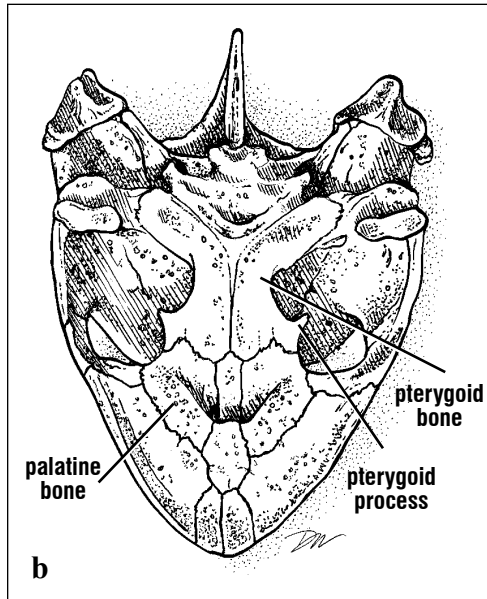
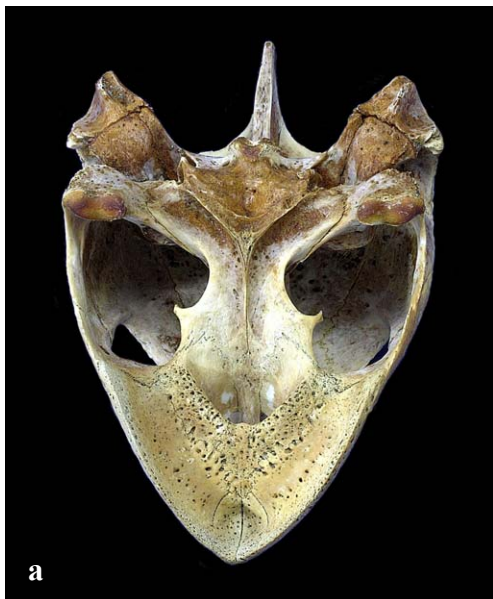SPECIES IDENTIFICATION FROM SKULLS

Lepidochelys olivacea (Figs. 37-39). The olive ridley skull is similar in shape to skulls of the loggerhead and Kemp's ridley. It is roughly triangular in shape, wide posteriorly, and has deep parietal notches. The jaws are shaped like a wide V. The palate lacks alveolar ridges. The two

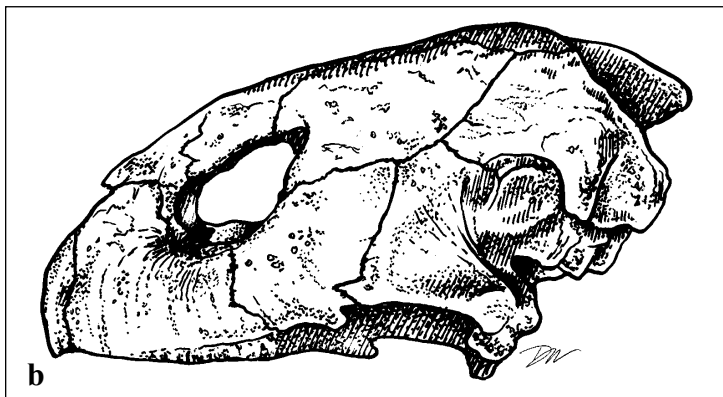
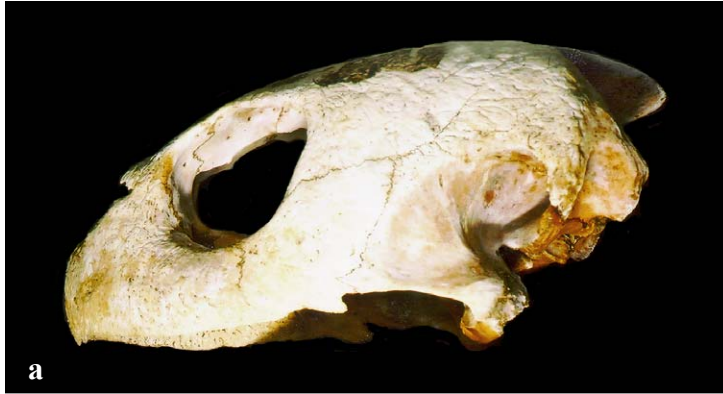maxillary bones are separated by the vomer which articulates with the premaxillary bones. The orbits are larger than in *L. kempii* (Figs. 39-40) and the pterygoid bones are broad at their narrowest point when compared with other species.



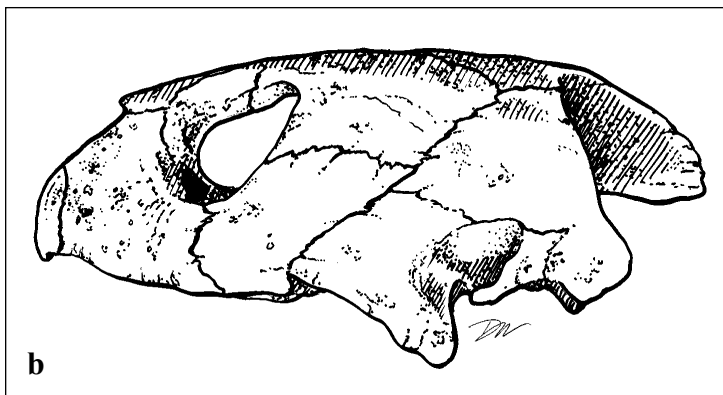
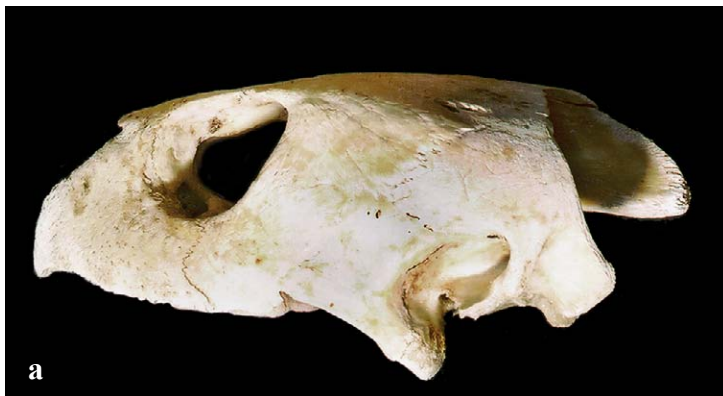Figs. 37a and 37b. *Lepidochelys olivacea*, dorsal skull



Figs. 38a and 38b. *Lepidochelys olivacea*, ventral skull. The pterygoid bone of the olive ridley is proportionately wider and the pterygoid processes are more pronounced than in the Kemp's ridley.



Figs. 39a and 39b. *Lepidochelys olivacea*, lateral skull. When measured across its longest axis, the orbits of *L. olivacea* are proportionately larger than those of *L. kempii*.

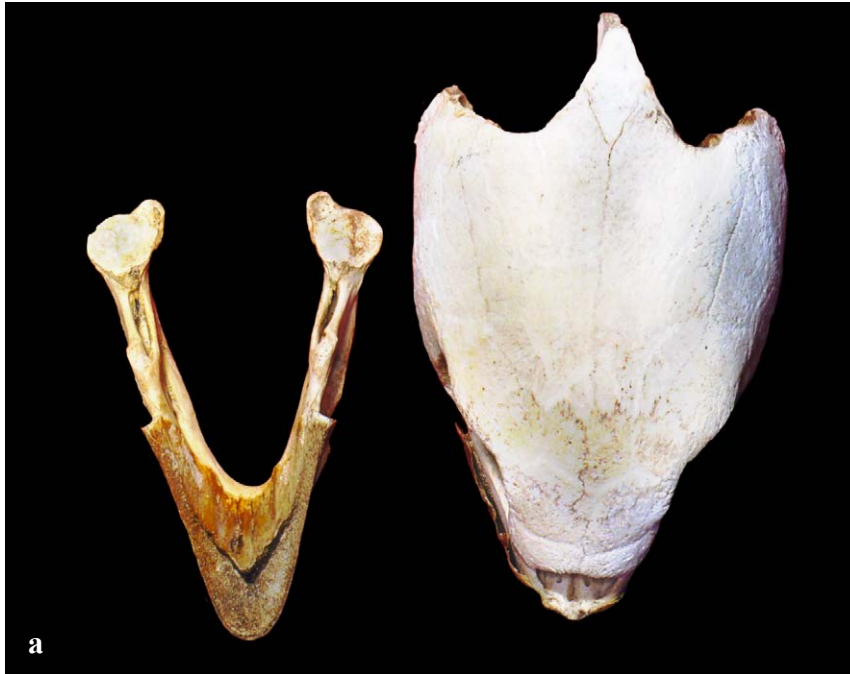

Figs. 40a and 40b. *Lepidochelys kempii*, lateral skull. Note the proportionally smaller orbit and slightly more hooked snout.

SPECIES IDENTIFICATION FROM SKULLS

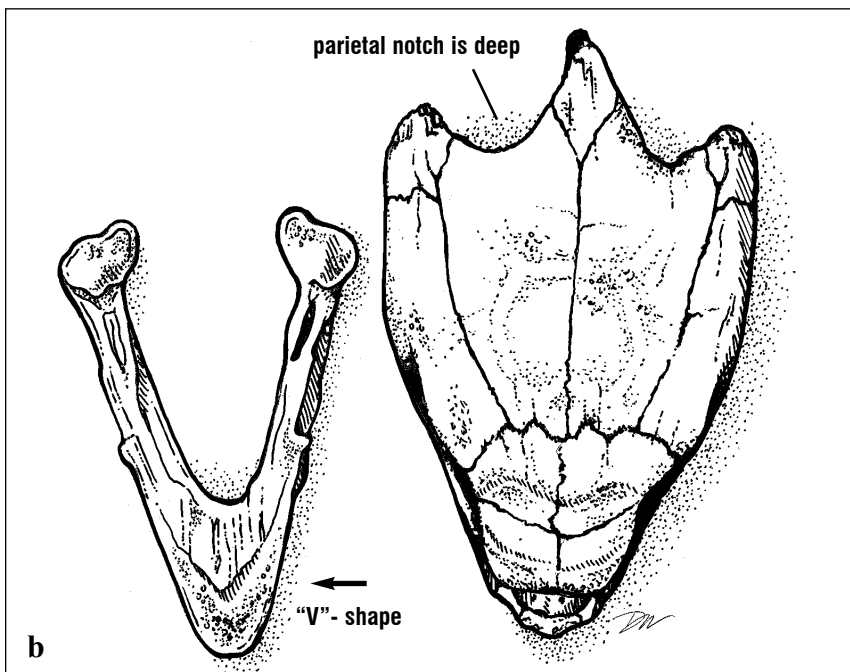
Eretmochelys imbricata (Figs. 41-42). The hawksbill skull is long and narrow in all but the youngest turtles (hatchlings). The length is approximately equal to twice the width (measured at the skull's widest part; Fig. 42). Hawksbill skulls have deep parietal notches and the snout tapers to a

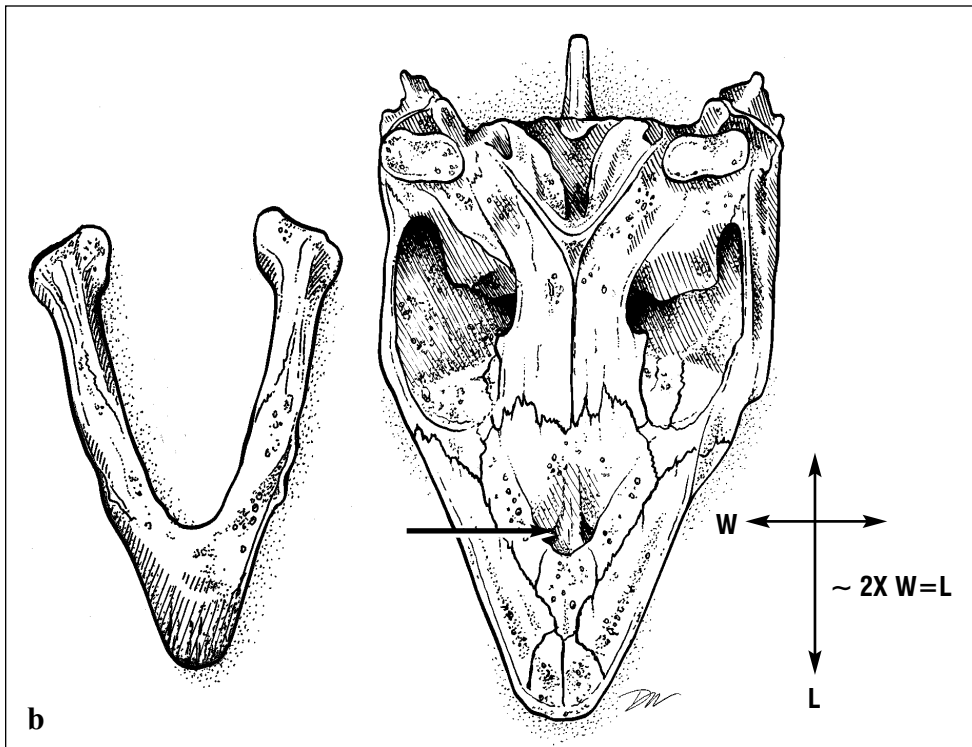
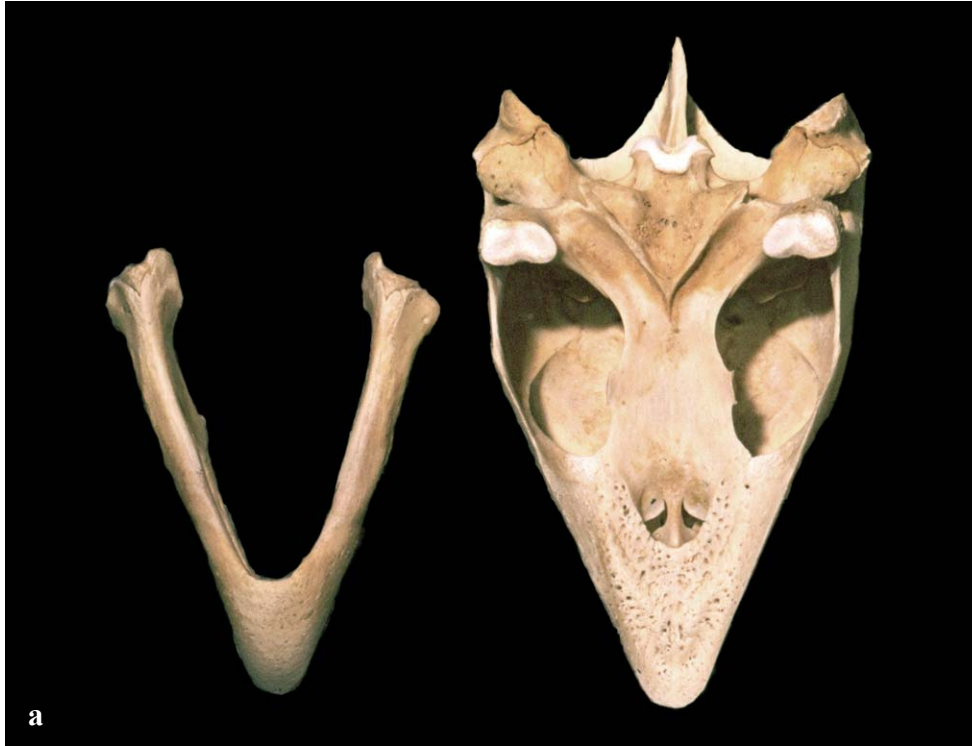point. The jaws are V-shaped and narrow (Fig. 41). The secondary palate is well developed and the internal nares are situated in the anterior third of the mouth. The two maxillary bones are separated by the vomer which extends anteriorly to articulate with the premaxillary bones (Fig. 42).



Figs. 41a and 41b.

Eretmochelys imbricata, dorsal skull and lower jaw with rhamphotheca. The jaws are very narrow and V-shaped.



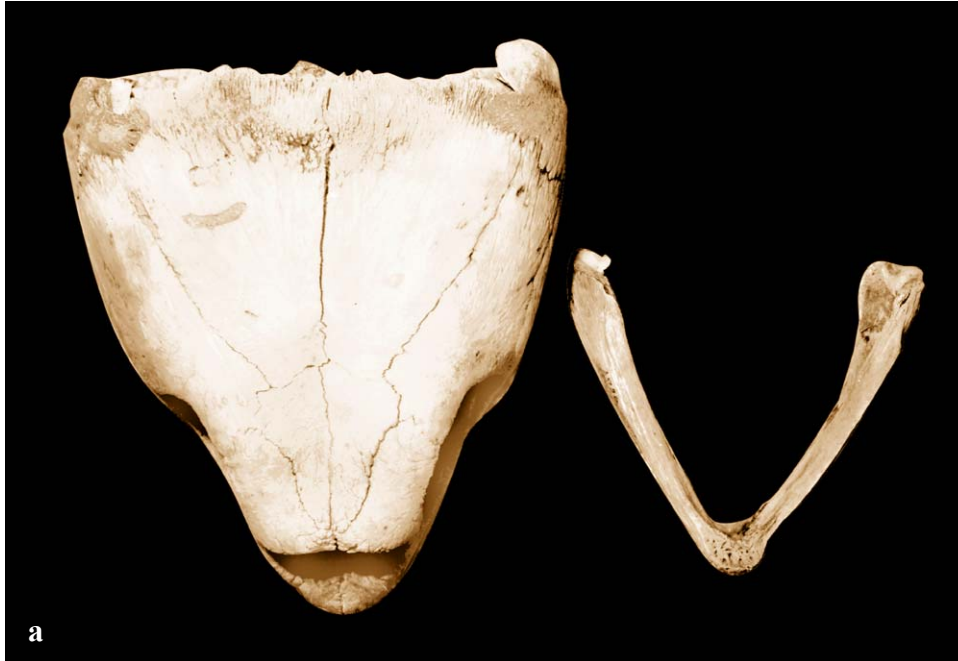

Figs. 42a and 42b. *Eretmochelys imbricata*, ventral skull and lower jaw. The skull is longer and narrower than that of any other species. The secondary palate is long so that the internal nares (arrow) are relatively far back.

SPECIES IDENTIFICATION FROM SKULLS

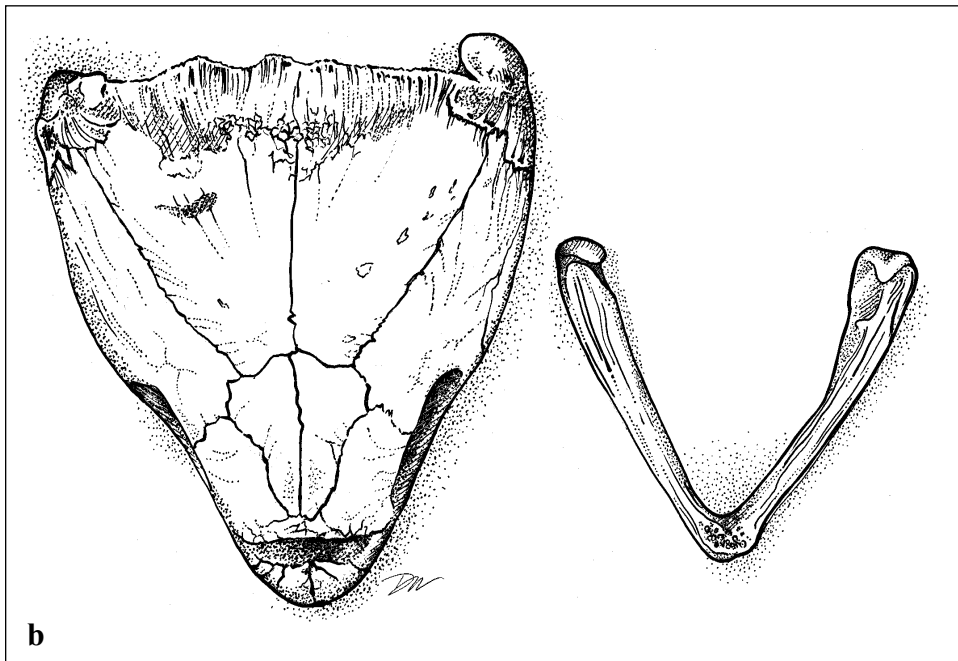
Dermochelys coriacea (Figs. 43 - 44). Leatherback skulls are unlikely to be mistaken for those of any other species. The skull is wide and rounded anteriorly with large orbits; there are no parietal notches (Fig. 43). The bones articulate loosely; there is little or no secondary palate (Fig. 44). The

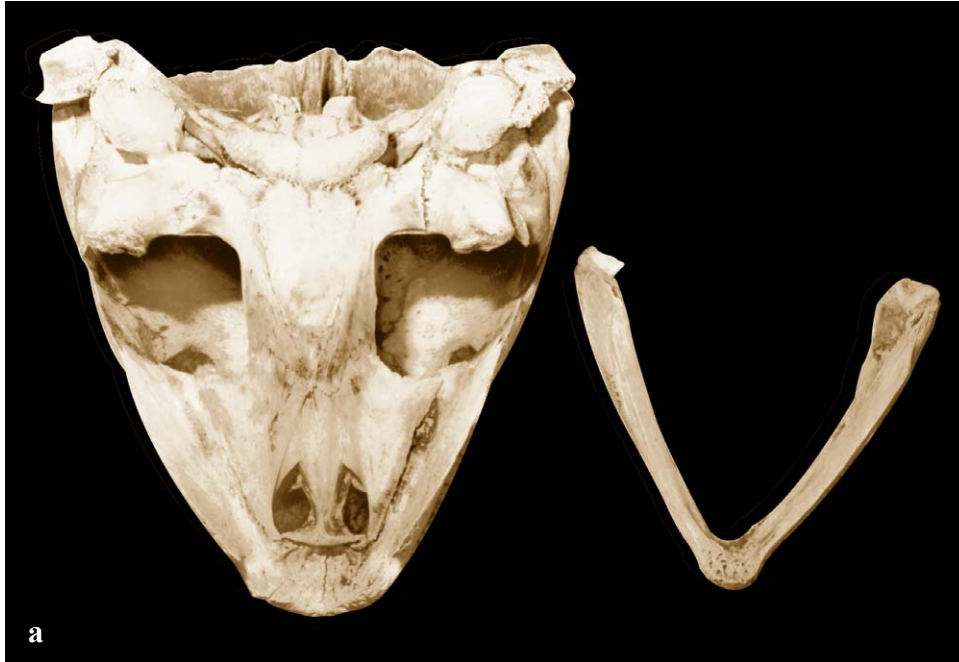margins of the jaws are sharp and possess notches. There are pointed cusps on the anterior maxillary bones. The lower jaw comes to a dorsally directed point at the mandibular symphysis (where the two halves of the lower jaw join). The lower jaw has a cartilaginous portion medial to the dentary.



Figs. 43a and 43b.

Dermochelys coriacea, dorsal skull and lower jaw. The bones fit together more loosely than in other species. The leatherback skull and skeleton has been described as neotenic (having embryonic characteristics) in form because of the lack of bony fusions.





Figs. 44a and 44b.
Dermochelys coriacea,
ventral skull and lower jaw.
Note the lack of a secondary
palate and the loose
articulations of the bones.

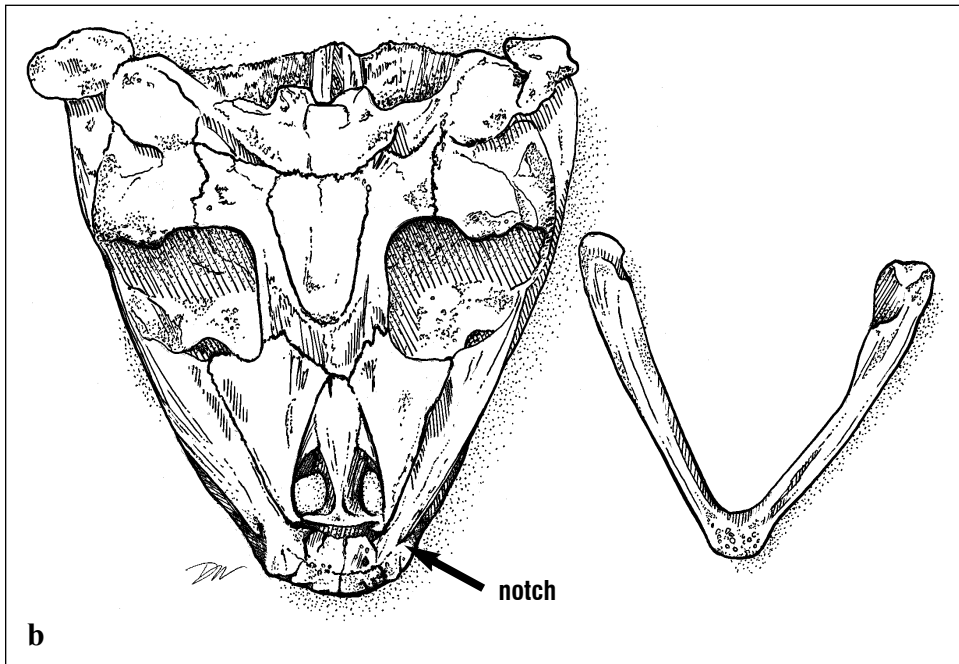

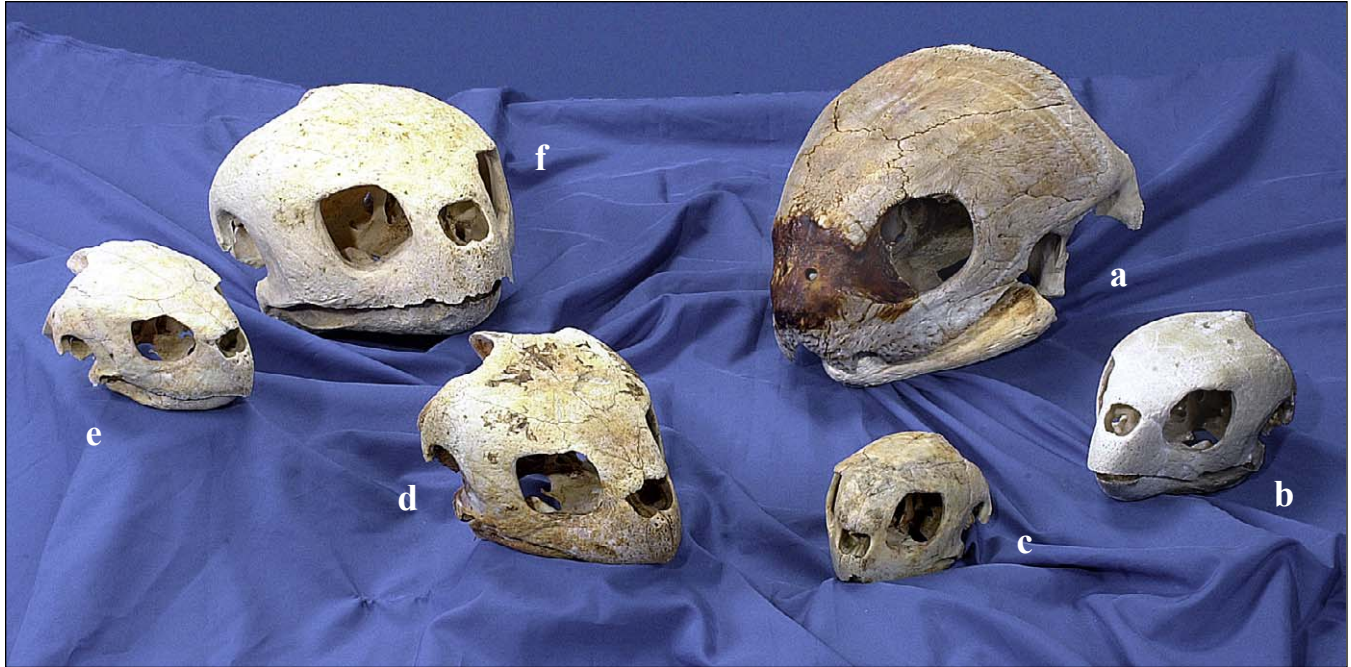


Fig. 45. Skulls of all the species found in US waters. *Caretta caretta* (f). The hawksbill, green turtle and Kemp's ridley skulls are from immature animals, others are from adults. Clockwise from top right: *Dermochelys coriacea* (a), *Eretmochelys imbricata* (b), *Chelonia mydas* (c), *Lepidochelys olivacea* (d), *Lepidochelys kempii* (e),

Rhamphotheca (beak)

The rhamphotheci are the keratinous beaks of the upper and lower jaws in cheloniids. They cover the maxillary, premaxillary, and vomer bones of the upper jaw, and the dentary of the lower jaw. They differ with diet and can be used to identify species.

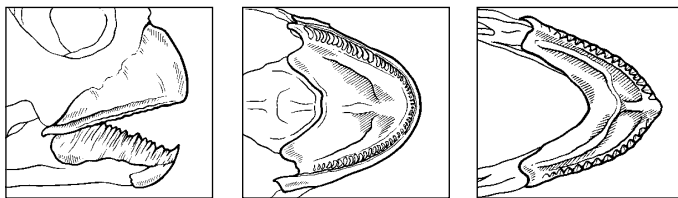
Several terms are used to describe the positions of parts of the mouth or rhamphotheci. Alveolar refers to the surfaces and edges of the

jaws where teeth would be found in nonchelonian reptiles. Palatal refers to the horizontal surface forming the roof of the mouth. Buccal refers to the portion of the lower plate next to the tongue.

Below, species-specific characteristics of the rhamphotheci (Fig. 46), useful in species identification, are illustrated and described.

Fig. 46. *Rhamphotheca* characteristics by species.

Chelonia mydas



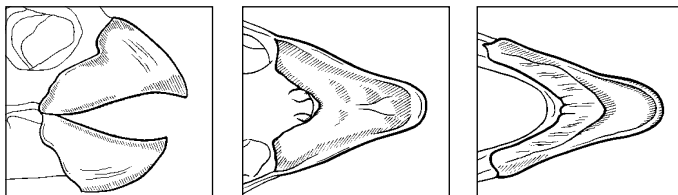
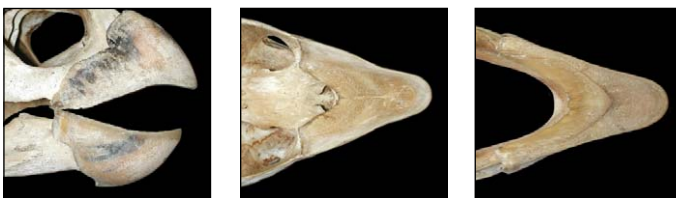Rhamphotheci

Upper Rhamphotheca

Lower Rhamphotheca

- Snout rounded, outer keratin smooth and delicately built.
- Edges are outlined by serrations and spike-like cusps.
- Upper rhamphotheca serrated, short, pointed cusps.
- Inner surface with vertically aligned ridges.
- Lower rhamphotheca is serrated with vertical spike-like processes.
- Parallel inner ridge with row of smaller cusps.
- Midventral ridge without spikes connects the two.
- Alveolar surface has two depressions to either side of the midline ridge.

Eretmochelys imbricata



Rhamphotheci

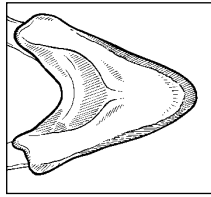
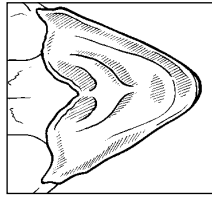
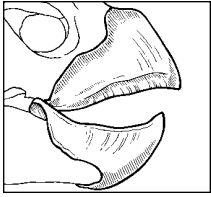
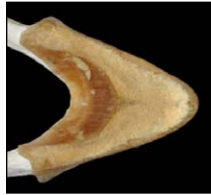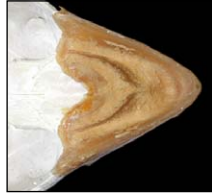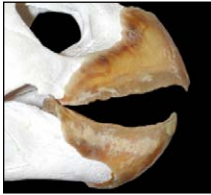
Upper Rhamphotheca

Lower Rhamphotheca

- Rhamphotheca moderately built.
- Snout narrow and pointed with sharp alveolar edges.
- Upper rhamphotheca's palatal portion is mostly smooth.
- Slight ridge, parallel to the maxillae; ridge may wear in older turtles.
- Lower rhamphotheca is narrow and smooth.
- Triangular process extends anteriorly from the buccal (posterior) margin.

RHAMPHOTHECA STRUCTURE

Caretta caretta



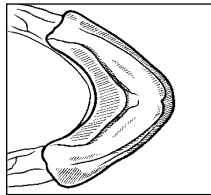
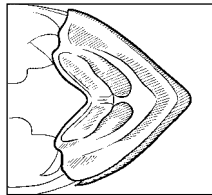
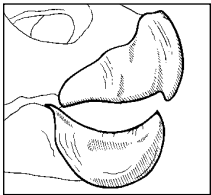
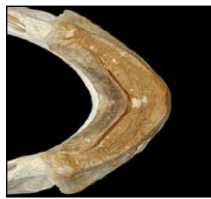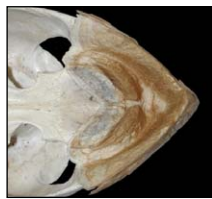
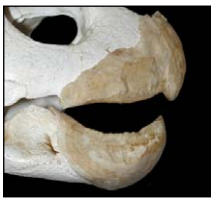Rhamphotheci

Upper Rhamphotheca

Lower Rhamphotheca

- Rhamphotheci robustly constructed with sharp alveolar edges.
- In young, upper and lower jaw come to a point.
- Upper rhamphotheca: palatal portion is wide and forms crushing surface inside mouth.
- Two V-shaped palatal ridges are found in young turtles; worn smooth in older animals.
- Lower rhamphotheca is trough-like with a thick crushing surface.
- U-shaped cutting surface is found along the posterior margin.

Lepidochelys kempii



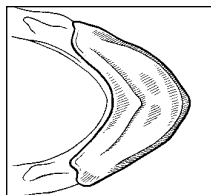
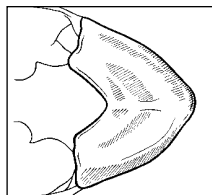
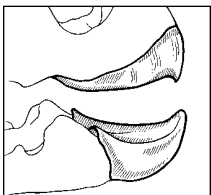
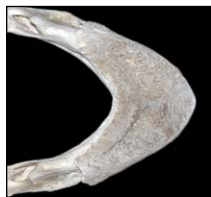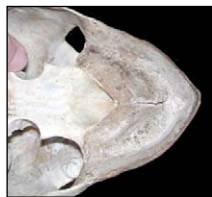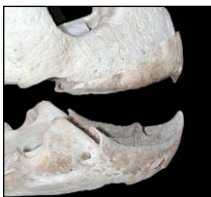Rhamphotheci

Upper Rhamphotheca

Lower Rhamphotheca

- The rhamphotheci are heavily constructed with thick alveolar surfaces.
- Both upper and lower jaws come to anterior hook-like points.
- Upper rhamphotheca: forms wide crushing surface with sharp-edged alveolar margins.
- The palatal portion has large cusps bilaterally.
- Lower rhamphotheca is trough-like with two depressions that receive the palatal cusps.
- Sharp U-shaped ridge marks the posterior border.

Lepidochelys olivacea



Rhamphotheci

Upper Rhamphotheca

Lower Rhamphotheca

- Rhamphotheci are heavily constructed with thick alveolar surfaces.
- Both the upper and lower rhamphotheci are pointed at the anterior midline.
- Upper rhamphotheca forms a wide plate with a sharp-edged alveolar surface.
- Palatal portion has a ridge bilaterally extending just anterior to the internal choanae.
- Lower rhamphotheca has a sharp, wide, V-shaped ridge running posteriorly along the buccal margin.

Standard Measurements

Several different lengths are measured when describing turtle size (Fig. 47). Each measurement is taken in order to ensure that comparative data are available to share with other programs world-wide. Over-the-curve measurements are taken with a non-stretching tape measure while straightline measurements are taken with calipers. The following are the standard measurements and their landmarks.

Standard Length (SCL and CCL) are measured from the mid-point of the nuchal scute to the posterior-most tip of the carapace in cheloniids (Figs. 48-49). Standard carapace length is a straightline measurement from the anterior-most

point on the midline of the nuchal scute to the posterior-most tip of the last marginal (supracaudal or postcentral) scute. Curved carapace length uses the same landmarks but is taken over the curve of the carapace with a tape measure. If the tape crosses epibionts, notation should be made describing this aberration in the measurement. In leatherbacks, SCL is measured from the middle of the nuchal notch to the posterior-most tip of the caudal peduncle. To measure the CCL of a leatherback, pull the tape tight between the middle of the nuchal notch and the terminal tip of the caudal peduncle, without forcing the tape along the ridge.

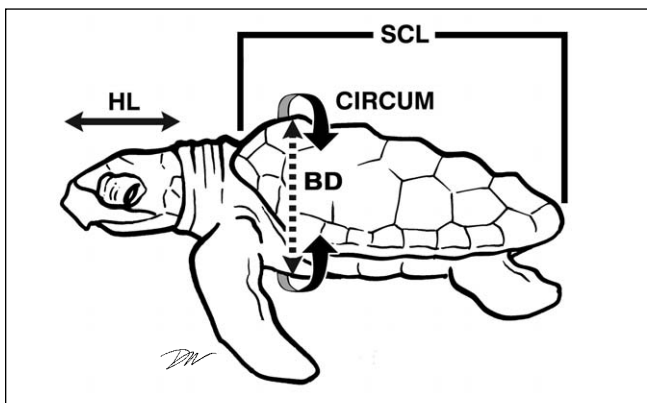
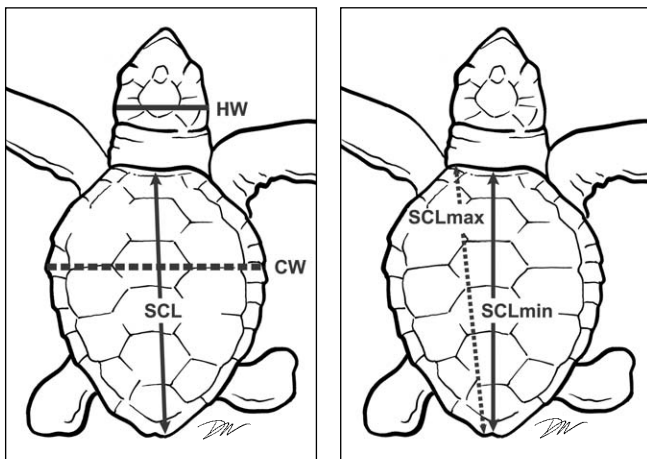


Fig. 47. Landmarks for standard measurements. Each is described in detail in the text.



Fig. 48. Straightline Standard Length: *SCL*.



Fig. 49. Over-the-Curve Standard Length: *CCL*.

STANDARD MEASUREMENTS

Minimum Carapace Length (SCL_{min} and CCL_{min}), also known as notch-to-notch length, is measured from the mid-point of the nuchal scute to the notch where the two most posterior marginal scutes meet (Figs. 50-51).



Fig. 50. *Minimum Straightline Carapace Length (Notch-to-Notch): SCL_{min}.*

Maximum Carapace Length (SCL_{max} and CCL_{max}), also sometimes called greatest length, is from the anterior-most part of the carapace to the posterior-most tip of the carapace on the same side (Figs. 52-53).



Fig. 52. *Maximum Straightline Carapace Length: SCL_{max}.*



Fig. 51. *Minimum Carapace Length Over-the-Curve (Notch-to-Notch): CCL_{min}.*



Fig. 53. *Maximum Over-the-Curve Carapace Length: CCL_{max}.*

STANDARD MEASUREMENTS

Carapace Width (SCW and CCW) is measured at the widest part of the carapace (not at specific scutes). In leatherbacks, carapace width is at measured the widest points, typically on the most lateral ridges. Care should be taken to ensure that the calipers and/or tape measure are perpendicular to the animal's long axis. The maximum width taken using a tape measure will not always fall on the same location as that measured with calipers (Figs. 54-55).



Fig. 54. Straightline Width: *SCW*.



Fig. 55. Over-the-Curve Width: *CCW*.

Maximum Head Width (HW) is measured using calipers at the widest part of the head (Fig. 56).



Fig. 56. Maximum Head Width (*HW*) is measured at the widest part with the calipers perpendicular to the long axis of the skull. This position varies with species so that, in some, it is near the jaw joint and in others, it is found more posteriorly.

Maximum Head Length (HL) is measured along the midline from the anterior-most part of the upper jaw to the posterior-most bone of the skull - the supraoccipital crest (Fig. 57). This bone is identified by feeling for the landmark (palpating).

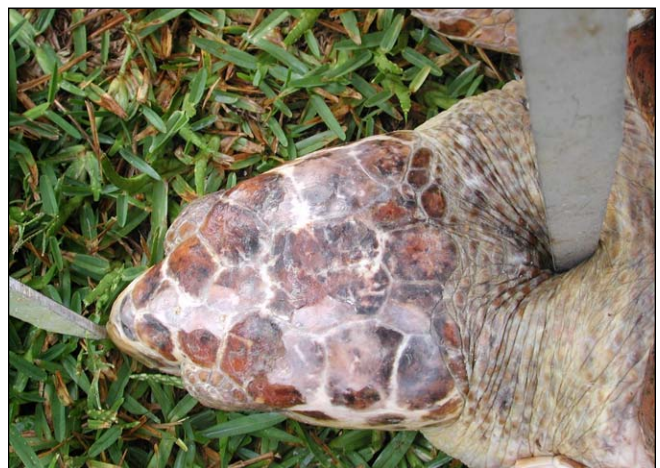

Fig. 57. Maximum Head Length (*HL*) is measured from the posterior tip of the supraoccipital crest (found by palpating) to the anterior-most part of the head, often the rhamphotheca (beak) of the upper jaw.

STANDARD MEASUREMENTS

Body Depth (BD) is recorded with the animal propped on its side or by digging a trench for the caliper jaws under an adult animal on land. This measurement is taken with calipers at the point of maximum carapace height when the bottom jaw of the calipers is held parallel to the plastron (Fig. 58).



Fig. 58. *Body Depth (BD)* measurements are taken at the body's maximum height. On a live turtle, an average of at least 3 measurements should be taken between breaths because the depth changes during breathing.

When measuring the animal, be sure to look for tags or tag scars on the front and hind flippers and, in the leatherback, near the tail (Fig. 59).

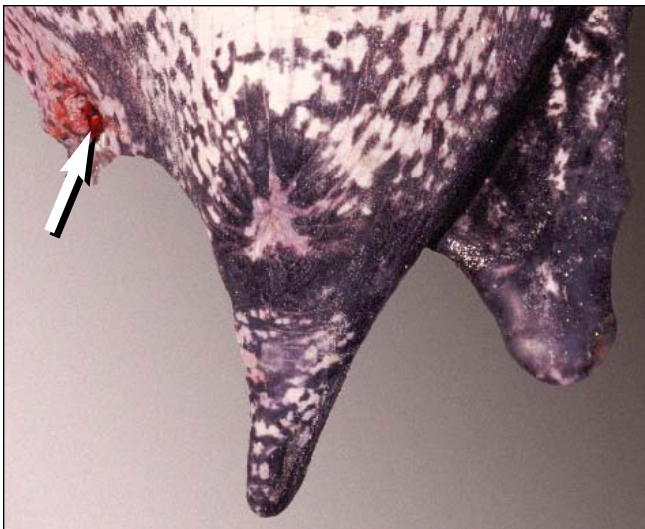


Fig. 59. *Tag tear-out scar on a leatherback.*

Plastron Length (SPL), straightline or curved (**CPL**), is defined by the posterior-most part of the plastron hard structure to its anterior-most hard structure. These points may extend beyond the intergular or gular scute at the ventral base of the neck and the anal or interanal scute of the plastron (Figs. 60-61).

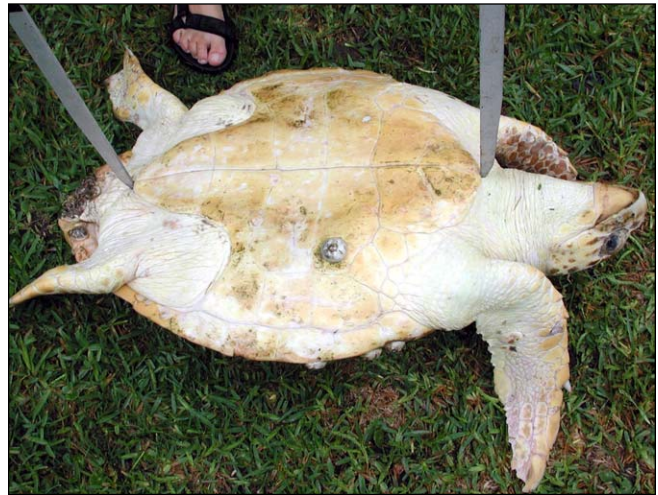

Fig. 60. *Plastron Length (SPL)* is measured with calipers extended from the anterior-most end of the plastron to the posterior-most end. These landmarks may occur beyond the scutes.



Fig. 61. *Plastron Length (CPL)* is measured with an aligned tape measure. This method gives a slightly longer measurement than one obtained with calipers.

STANDARD MEASUREMENTS

Total Tail Length (TTL) is measured from the posterior-most point of the plastron to the tail tip. The **Plastron-to-Vent Length (PVTL)**, a separate measurement, is from the middle of the cloaca, or vent, to the posterior-most tip of the plastron. The **Vent-to-Tip (VTTL)** measure is taken from the middle of the vent to the tip of the tail or it can be calculated by subtraction (Figs. 62-63).

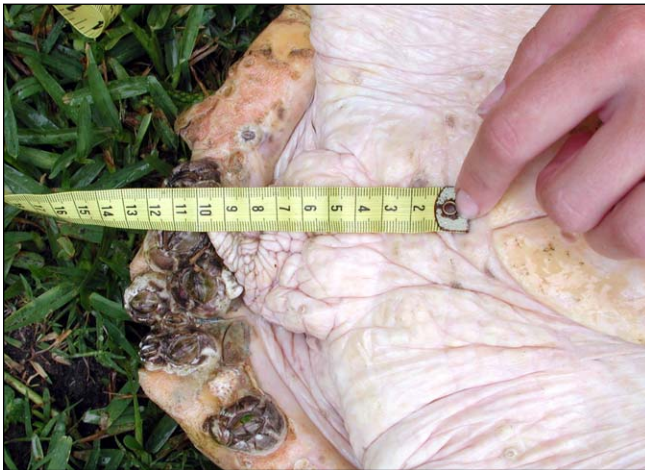

Fig. 62. Tail Length (TTL) is typically measured with a tape measure extending from the posterior-most part of the plastron to the tip of the tail. The tape measure is allowed to follow the curl in the tail. Caliper measures tend to be slightly shorter.

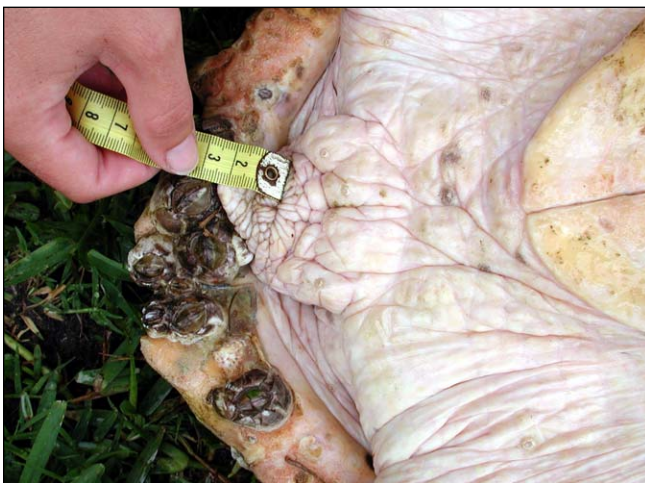

Fig. 63. The Vent-to-Tip measurement (VTTL), shown here, is taken from the middle of the cloaca (vent) to the tip of the tail.

Circumference (CIRCUM) is the greatest circumference taken perpendicular to the turtle's long axis (excluding the flippers; Figs. 64-65).

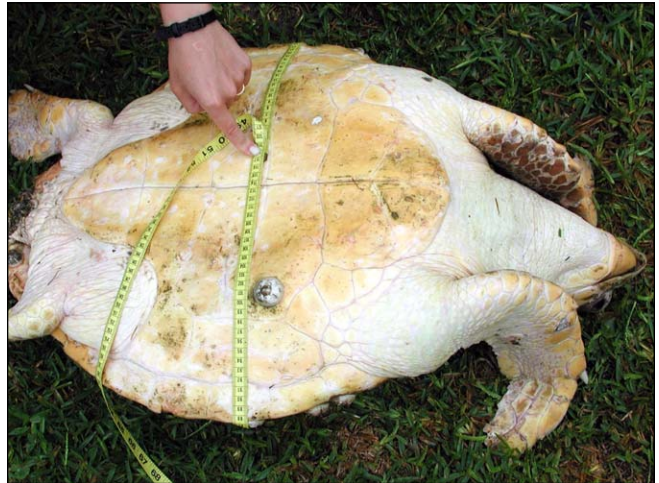

Fig. 64. Circumference (CIRCUM) is taken with a tape measure. It can be measured with the turtle lying on its carapace.



Fig. 65. Circumference also can be taken with the turtle on its plastron. For very large animals, it may be necessary to dig under the turtle in order to get the tape aligned properly. When the tape is stretched over epibionts, such as barnacles, this should be noted.

Methods of Dissection

Tools and Preparation. Before beginning your dissection, make sure you have all necessary tools, data sheets, pens, and pencils. Tools should include large and small calipers, a tape measure (Fig. 66), a camera, one or more saws, snips (metal or bone shears), one or more sharp knives, scalpel blades and handles, a sharpening stone or steel, and hemostats or pliers (Fig. 67). Other useful tools are blunt probes, forceps with and without teeth, scissors, pipettes and/or syringes for removing fluid. Bowls, plastic bags or jars and string or rubber bands are also useful. Protective gear should minimally include gloves; boots,

coveralls or aprons are recommended. Access to towels will be important. Be sure to start with sharp instruments and be prepared to sharpen them frequently. Turtle skin can be tough and dulls knives and scalpel blades quickly. For clean up, herbal and anti-bacterial soaps are good for neutralizing odors and disinfecting, respectively. A 10% chlorine bleach (sodium hypochlorite) solution will help disinfect floors, bowls, or trays. Mix 1 part liquid chlorine bleach with 9 parts water. Check stock solution concentrations; some brands are stronger than others. Bleach solution is too harsh for use on most good tools.



Fig. 66. Tools used to measure the animal: a nonstretching tape measure and large sliding calipers (tree calipers).

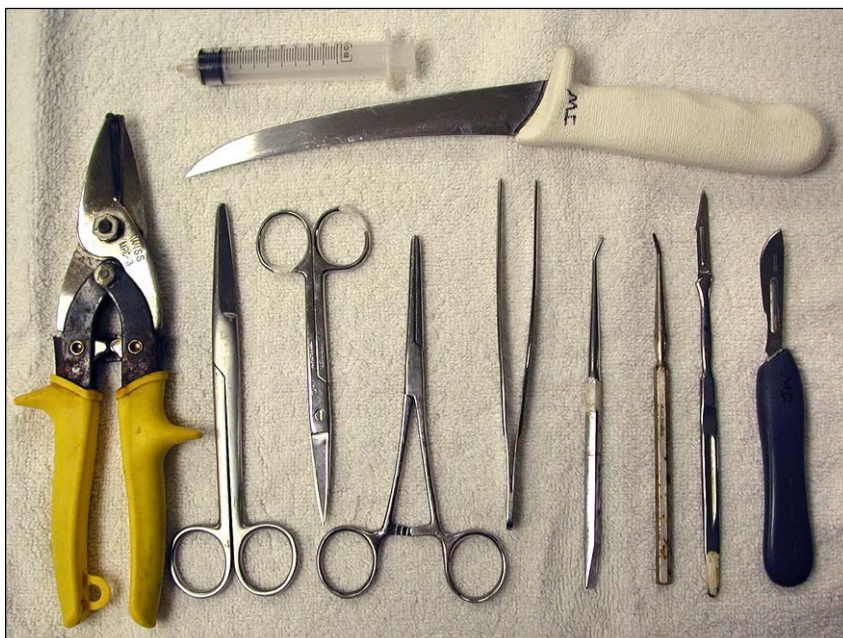

Fig. 67. Examples of tools used for the dissection (left to right): Metal snips, blunt scissors, pointed scissors, hemostatic forceps, forceps without teeth, blunt probes, and scalpels. A syringe and knife (at the top) are particularly useful.

Instructions for use of this guide.

Dissections typically proceed by body region while investigators tend to look-up structures by system. Hence, the dissection will be briefly described by region. The more complete description of each structure, should it be needed, will be found in sections dedicated to the details of organ systems.

The following are instructions for the most common dissections. Individuals differ in the order in which they proceed. There is no one correct way, however, all dissections should start with a thorough external examination and verification of the species. Photographs are helpful for verifying species, documenting anomalies, and addressing questions.

In most cases, it is easiest to work with a carcass that is placed on its back (Fig. 68). Working with very large animals may require the assistance of heavy equipment to move the carcass.

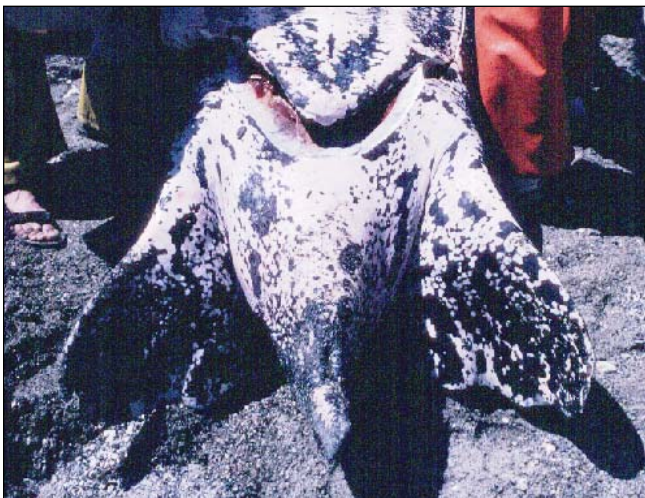

Fig. 68. Carcasses should be placed on their backs for access to most viscera.

When positioning the carcass for dissection, pay attention to proximity to buildings, drainage and tides. Before beginning a dissection, consider the time of day as dissections may take hours. In some cases, packing the animal or some parts of the animal in ice is a good strategy to minimize decomposition.

External examination. A complete description of the carcass should start with an external examination. Species, size, and sex, (if mature) should be noted. Foreign materials, anomalies, and healed or fresh wounds should be described including their locations. Tumors are common in some species, especially green turtles, and should also be described by size, color, texture and location.

Starting the dissection. Start by removing the plastron. Make a cut through the skin of the neck then extend it laterally (Fig. 69). Cut around the axillary regions near the plastron and along the seam made by the marginal and inframarginal scutes (Fig. 70). Bony processes from the plastron bones extend into the peripheral bones near the anterior and posterior inframarginal scutes. Hence, the cut cannot follow the seam completely. The skin and muscle near the hind limbs are thin, so care should be taken here to avoid cutting into the body cavity. The cut should follow along the plastron's posterior margin.

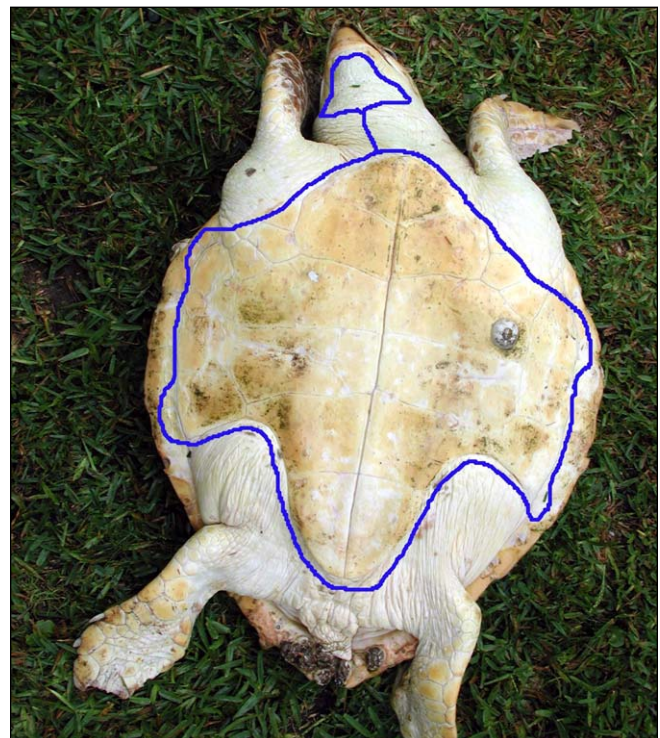


Fig. 69. An outline is shown to trace the path of the initial cut needed to successfully remove the plastron.

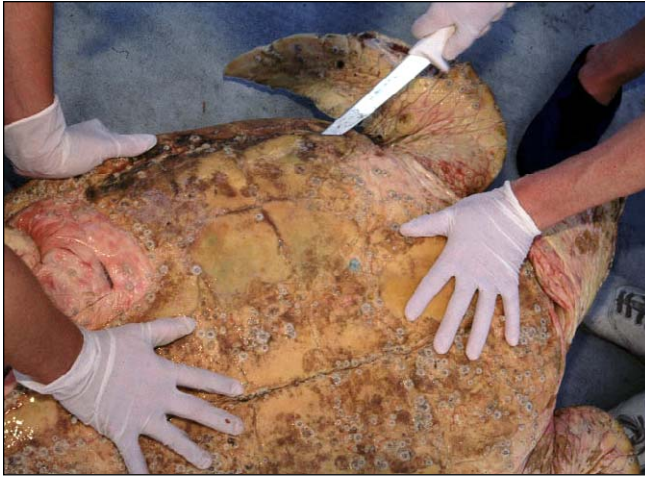

Fig. 70. *The cut may be made with a knife or scalpel blade. When using a knife, be sure the point is kept very near to the plastron so that it does not cut the viscera.*

The anterior part of the plastron is attached to the pectoral apparatus (the shoulder bones) via thick connective tissue. (In cheloniids, this is near the midline at the margins where the humeral and gular scutes meet). This connection must be cut close to the plastron (Fig. 71) in both hard-shelled and leatherback sea turtles to avoid damaging the heart, great vessels, or thyroid gland (Figs. 72-73). Once this attachment is free, lift the plastron while separating muscle and blood vessels from the shell by blunt dissection and careful cutting. Blunt dissection, the use of the hands or blunt instruments to separate structures, will often free the shoulder muscles from the plastron and from the peritoneum (the translucent connective tissue covering the organs).

Before removing the plastron completely from both sides, locate the greenish gray Rathke's glands in green turtles and ridley turtles. They are located deep to the Rathke's pores (Fig. 22) and embedded in fat. The gland feels denser than the fat when palpated. If a sample is needed, section the gland, and like most organs, if dropped in water, it will sink whereas fat will float, making it possible to distinguish the two.

Internal Landmarks. Once the plastron is removed, you will see that the ventral surface of the body is mostly covered by muscles (Figs. 72-73). There are 3 major groups of muscles that must be cut or dissected away to expose the viscera. These are the longitudinal muscles along the neck, the large pinnate (feather-shaped) “chest” muscles used for swimming, and the fan-shaped pelvic muscles that were attached to the plastron (Fig. 73).

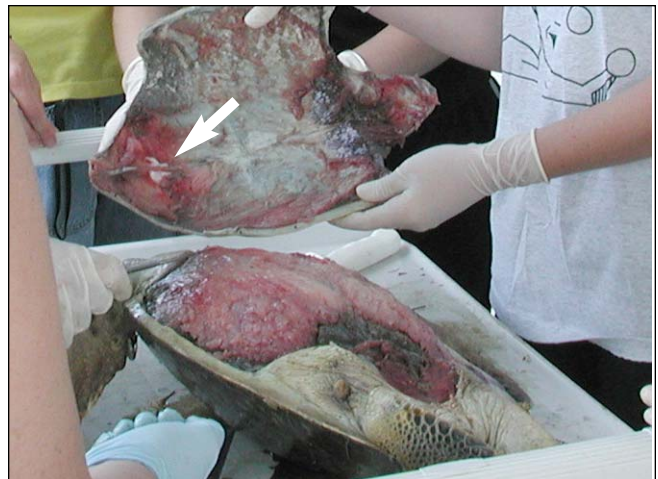

Fig. 71. *To free the plastron, the attachment from the acromion processes to the plastron (at arrow) must be cut.*

Good landmarks that you can use to find organs are the **acromion processes** (Fig. 73) and the long triangular **coracoid processes** (procoracoids; see Skeletal Anatomy, p. 51; Muscle Anatomy, p. 61) on each side of the body. The two acromion processes cross the anterior body just posterior to the neck and extend to the shoulder joint. They attach medially, via ligaments, to the plastron. The coracoid processes extend posteriorly from the shoulder joint toward the abdomen. These two parts of the shoulder girdles serve as attachments for many of the large muscles that move the flippers (Fig. 73; see Skeletal Anatomy Figs. 112-115). The space defined within the borders of the right and left acromion and coracoid process serves as a landmark for the heart, great vessels, and thyroid gland. The major blood vessels will also act as guideposts for locating the thyroid and thymus glands.

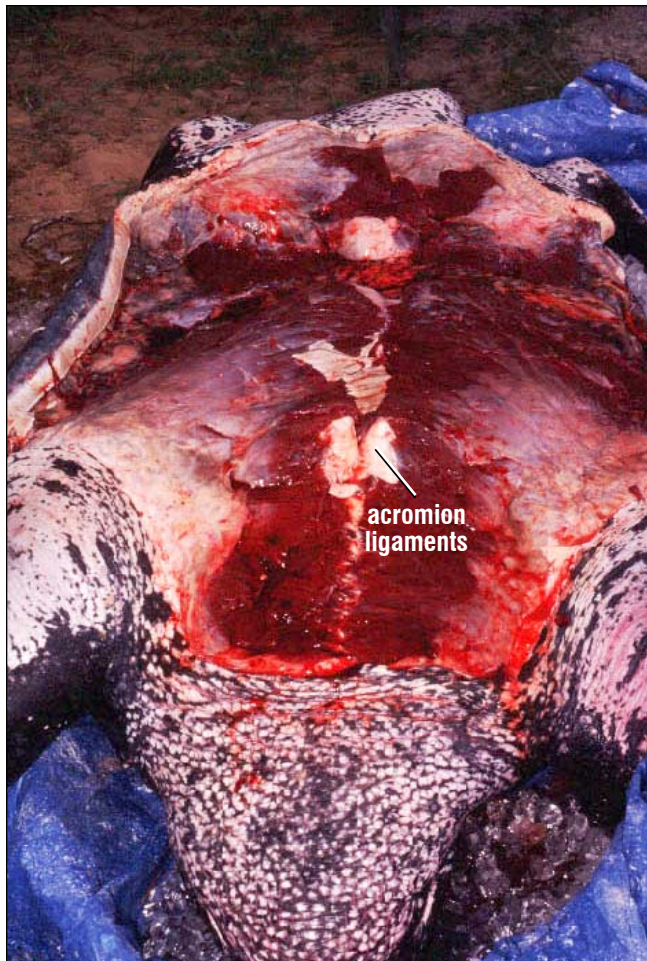

Fig. 72. The massive pectoral and pelvic musculature can be seen in this leatherback. The two white patches on the anterior body are the cut ligaments of acromion processes. The head is toward the bottom of the picture.

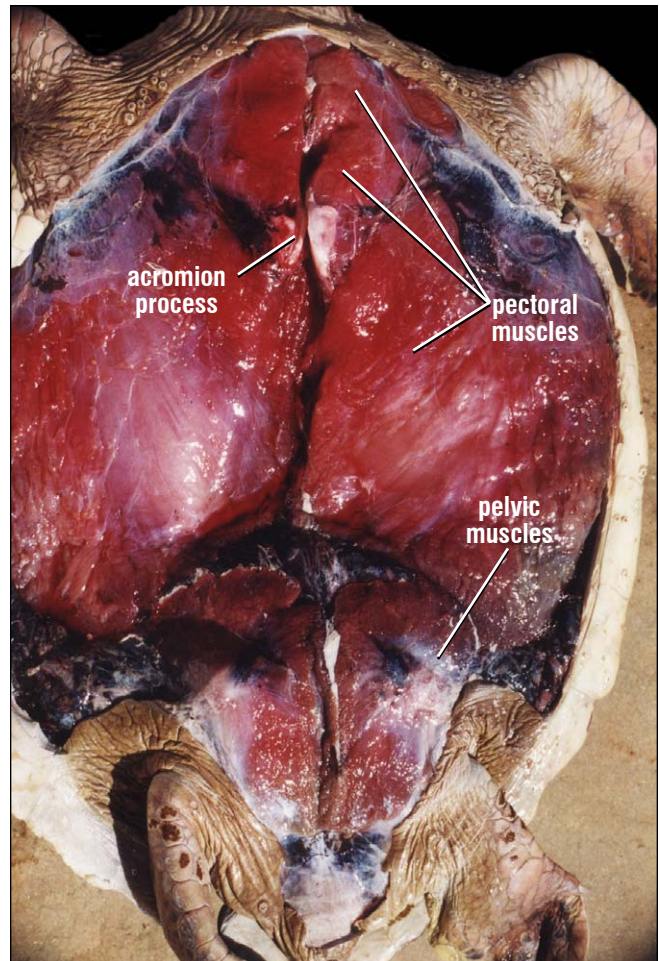


Fig. 73. The ventral pectoral and pelvic musculature covers most of the peritoneum and organs. These must be removed to expose the peritoneal cavity. The paired acromion processes are visible adjacent to the midline but the fan-shaped coracoids are covered by the pectoral muscles. Anterior is toward the top of the picture.

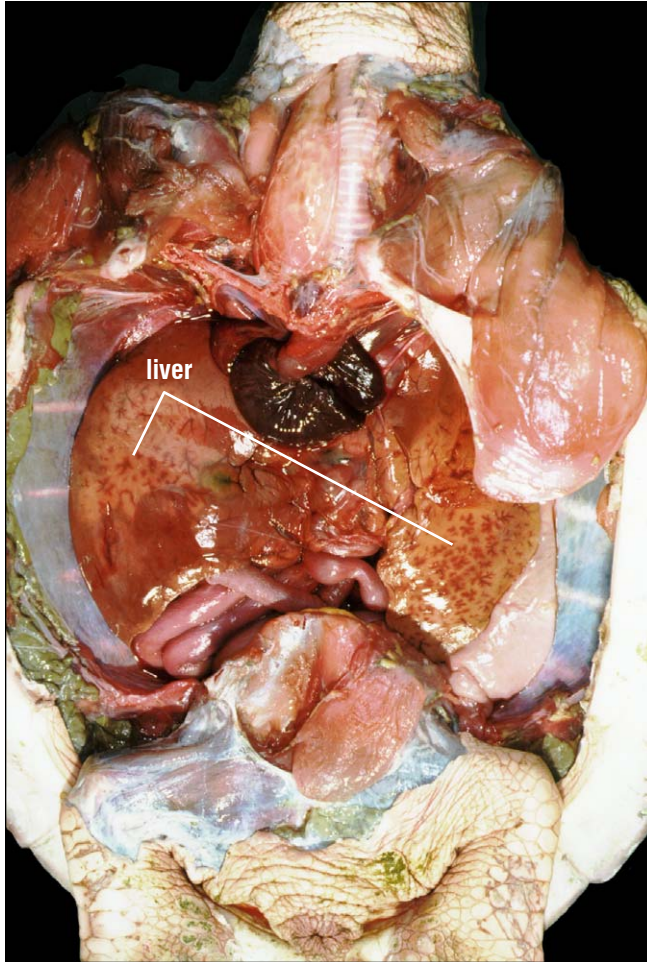


Fig. 74. The peritoneum has been removed to expose the layout of the organs. The heart is centrally located, posterior to the trachea. The liver is to each side of the heart. The pectoral girdle was removed from the animal's right side (left in photo) and reflected laterally on the animal's left side.

Rotating the acromion and coracoid anteriorly will help separate the muscles from the peritoneum (encasing the viscera). The heart, liver, and major blood vessels (Fig. 74) usually can be seen through this layer. To expose the viscera, remove the flippers and shoulder girdles by breaking the attachments of the scapula to the carapace. Free the shoulder muscles attached to the shell and neck (cut or break them). Twist the acromion and coracoid until the scapula, which extends from the

shoulder joint to the anterior carapace, is free. Use blunt dissection to remove the remaining attachments then lift the shoulder girdle and flipper out of the body.

Cardiovascular anatomy. Open the **pericardium** (Fig. 75) to reveal the heart. The pericardial cavity will often contain fluid, particularly in specimens that have been frozen and thawed.

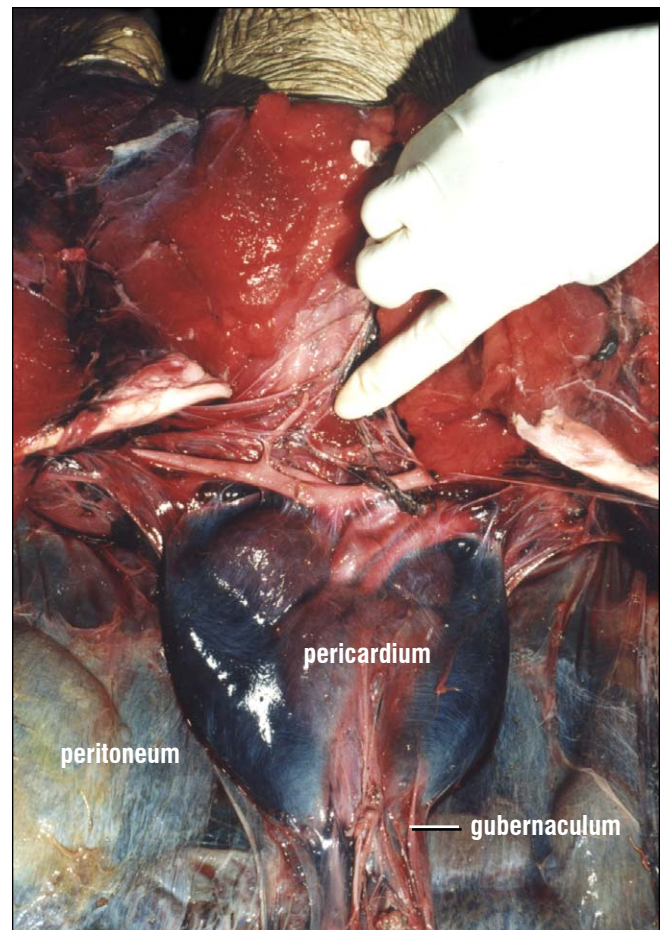


Fig. 75. The pericardium contains the heart and pericardial fluid. The great vessels (aortas and pulmonary arteries) are seen posterior to the thyroid, at the fingertip, and the horizontal arteries. The heart is attached posteriorly via the gubernaculum, a cord of tissue at the base of the pericardium. The peritoneum, a translucent fibrous membrane surrounding the organs, is seen to either side of the pericardium.

Upon opening the pericardium, 3 of the chambers of the heart are visible: the single **ventricle**, **left atrium** and **right atrium** (Fig. 76). The ventricle is attached to the pericardium via a fibrous connective tissue cord called the **gubernaculum cordis** (Fig. 75). After the gubernaculum is cut, the heart can be rotated anteriorly to reveal the fourth chamber, the **sinus venosus**. The sinus venosus is thin-walled; it collects venous blood from the head, ventricle, lungs and body (see Circulatory Anatomy, Fig. 129).

The great vessels (pulmonary artery, left aorta, and right aorta) arise from the anterior and ventral part of the heart. The right aorta gives off a branch almost immediately, the **brachiocephalic trunk** (Fig. 76) which then branches to the left and right. Small thyroid arteries arise from the brachiocephalic trunk and drain the single thyroid gland. The thyroid gland feels like a round gelatinous mass. Careful trimming of fat and connective tissue will reveal the red to brown thyroid (Fig. 75). The brachiocephalic trunk then forms subclavian arteries laterally, which become axillary arteries as they pass toward the flippers. The right and left thymus glands can be found by following the brachiocephalic trunk to the subclavian and axillary arteries. Feel for the thymus glands along the subclavian and axillary arteries before trying to locate them visually. After you have identified the thymus and thyroid glands, you can remove the heart for detailed examination by cutting through all the vessels and the sinus venosus. You may tie off the vessels before cutting if you want to minimize blood draining into the body cavity.

Gastrointestinal Tract and Related Structures.

Next examine the gastrointestinal (GI) tract. Expose the **esophagus** leading to the stomach and the **trachea** to the lungs with a midventral cut in the neck skin. Open the neck skin and muscle as deep as the **hyoid** (the skeletal structures that support the tongue and some neck muscles). Cut along the inner surface of the lower jaw to free the tongue, glottis, trachea, and esophagus. The trachea and esophagus

will exit posterior to the hyoid apparatus. The esophagus is deep and slightly to the (turtle's) right of the trachea. Cartilaginous rings characterize the trachea. The esophagus is a collapsed muscular tube. If you have difficulty finding the esophagus, you can run a blunt instrument or tube down the throat and locate the structure by moving your probe.

In the body cavity, the esophagus makes a sharp curve to the left to join to the stomach. The stomach leads to the small intestine with its digestive glands (liver and pancreas). The large intestine joins the distal small intestine and the GI tract ends with the rectum (Fig. 77).

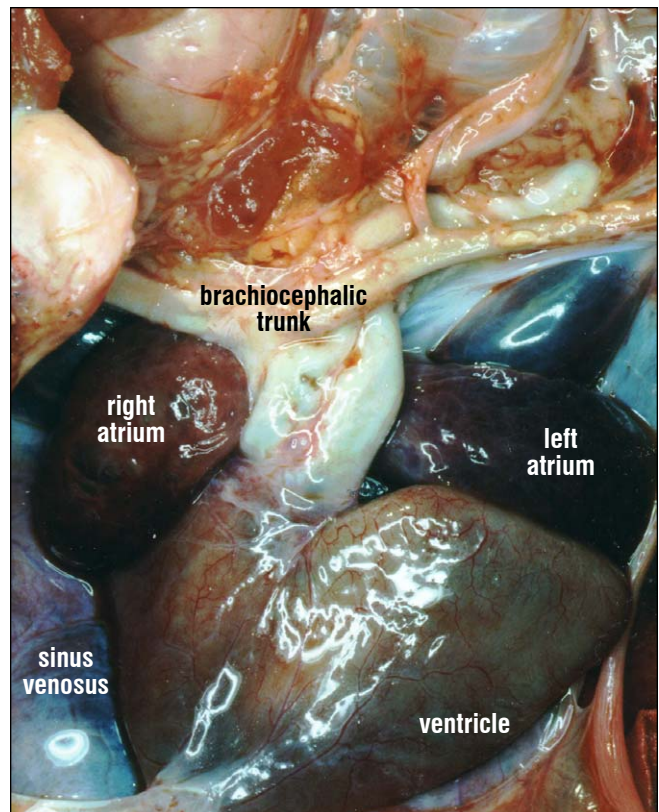
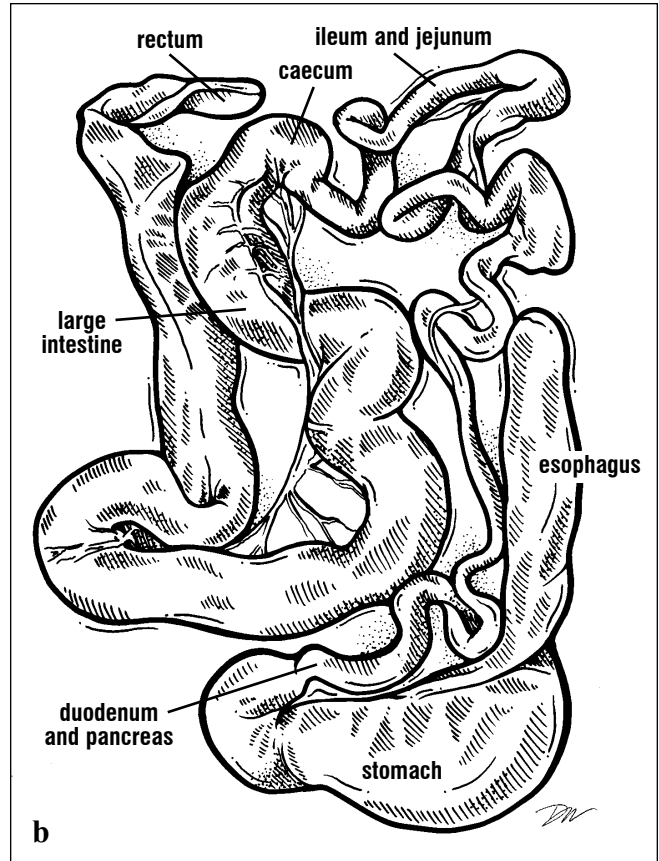
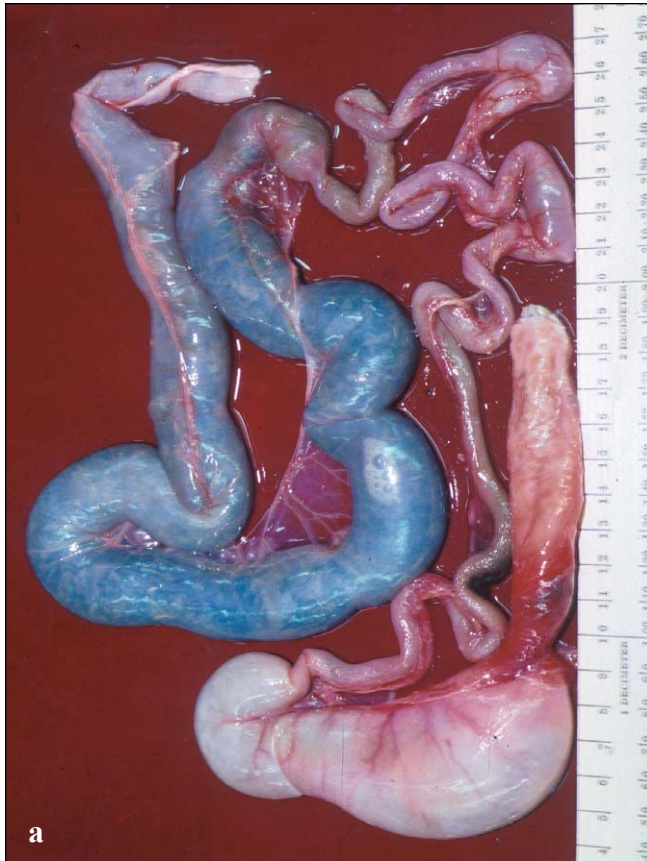

Fig. 76. The heart has 4 chambers: the sinus venosus, right atrium, left atrium, and ventricle. The two aortas and pulmonary trunk emerge from the anterior aspect of the ventricle and are seen between the two atria. The brachiocephalic trunk is a landmark for locating the thyroid and thymus glands. The heart is pushed laterally to show the sinus venosus.



Figs. 77a and 77b. The gut of a hawkbill after it has been removed and cut free from the liver, spleen, mesenteries, and cloaca. The GI tract

includes the esophagus, stomach, small intestine, and large intestine, which are easily distinguished from one another.

Once you have located the esophagus, tie it off near the mouth with string or rubber bands that will not slip. You can then cut it away from the mouth and start removing the gut for examination. Separate the esophagus and stomach from the trachea and liver by blunt dissection. The stomach is attached to the liver's left lobe ventrally and to the left lung dorsally. These attachments must be cut or broken carefully in order to free the stomach and leave the liver and left lung intact.

pyloric sphincter, the **pancreas** can be seen running distally along the **duodenum** (Fig. 77) past the **common bile duct** (a short attachment to the **gallbladder** which is found in the liver's right lobe). The pancreas is usually smooth, shiny (pink to peach colored), except in turtles that have decomposed. The common bile duct from the gallbladder can be identified by the green bile stain. The **spleen** can be found near the distal end of the pancreas. It is nearly round to oblong in shape, dark red, and highly vascular (see Circulatory Anatomy, Fig. 158 and Gastrointestinal Anatomy Fig. 164).

Continue to remove the gut by tearing or breaking the **mesenteries** (flat tissues that suspend and support the organs) and blood vessels. Be careful not to cut the stomach or intestines. The stomach joins the small intestine at the **pyloric sphincter**, a thick muscular sphincter or valve. Just past the

The intestine is long and must be cut away from its highly vascular, fan-shaped mesentery. The posterior part of the intestine is the **colon** (large intestine), which ends in a muscular **rectum** (Fig. 77). The

METHODS FOR DISSECTION

rectum is often pigmented. It enters the **cloaca**, a chamber that receives urine, eggs or sperm. Before cutting through the rectum, tie it off with string or rubber bands.

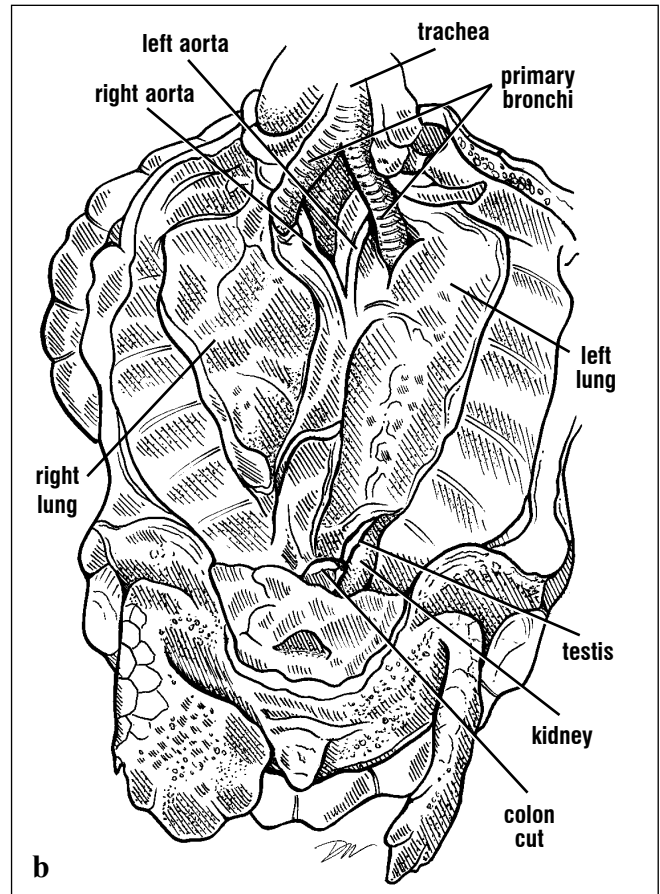
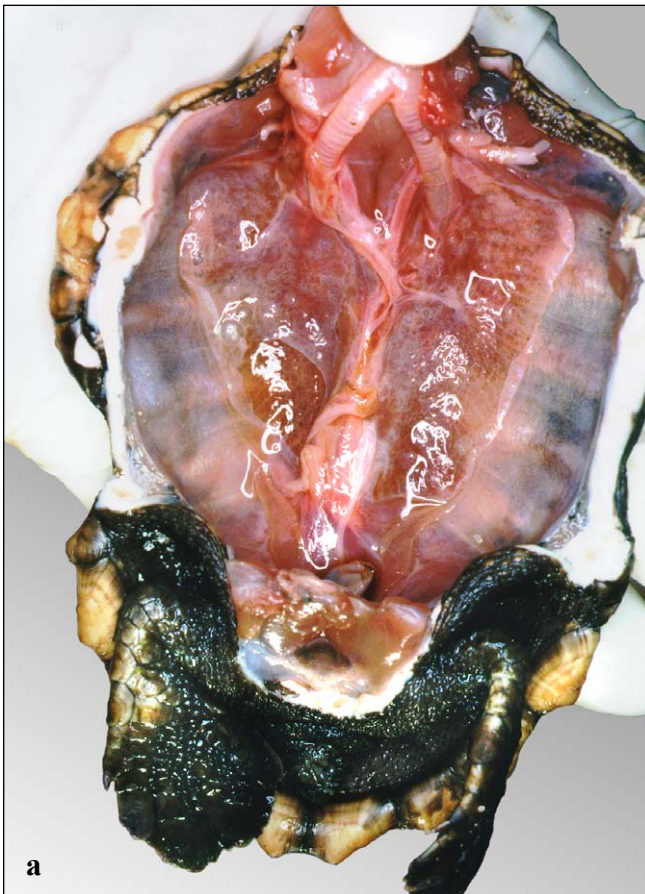
The **urinary bladder** (discussed shortly) is anatomically ventral to the rectum and is suspended on the midline of the pelvis. It too, connects to the cloaca.

Before opening the gut to examine the contents and the lining, it helps to tie it off in 3 or more sections so that there are landmarks available when describing the parts. By using pairs of ties, the gut can be cut without spilling the contents. The gross appearance of the lining of the intestines does not

always allow one to describe the location of a structure, tissue, or contents, so preset landmarks are useful. When opening the intestine, it helps to have trays or bowls ready to receive contents.

If you have not removed the **liver** with the gut, do so now by carefully freeing it from its attachments to the lungs and the peritoneum. The dense liver is composed of two lobes, with a connection of varying size between the two (Fig. 73). The right lobe is usually larger and, on its posterior surface, houses the round gallbladder. The gallbladder is usually dark green and may be full and convex or collapsed and concave (when empty).

Once the gut is removed, it is easy to see the lungs and the gonads (Fig. 77) at their posterior margin.



Figs. 78a and 78b. The lungs are in contact with the carapace. By tracing the trachea posteriorly to the 2 bronchi, the lungs can be found. They extend

for most of the length of the carapace. The gonads are found at the base of each lung. In this animal, the testes are shown.

METHODS FOR DISSECTION

Gonads. The gonads are attached to the peritoneal wall, posterior to the lung and anatomically ventral to the kidneys. The **ovaries** of mature and maturing turtles have a number of round yellow follicles that appear as small (~2 mm - 2 cm) diameter spheres embedded throughout the length of the long narrow organ. Immature ovaries are more compact, flat, often elongate, and fusiform in outline. They are often pink and granular in appearance. Ovaries tend to be attached along their length by one edge. The **oviduct** transports the follicles, then eggs, to the cloaca when mature. The oviduct is located lateral to the ovary and is not attached to it. Each oviduct extends anteriorly from the cloaca for about 2/3 the length of the body. In mature turtles, it has an "accordion" appearance. In immature turtles, it is a simple flat tube that is very narrow in the youngest and increasingly wide in older turtles (see Urogenital Anatomy, Figs. 220-221).

The **testis** is often yellow or tan, and smooth. It is fusiform in outline and is attached to the body wall by its flat dorsal surface. The **vas deferens** is a coiled tube that is found lateral to the testis transports sperm to the cloaca. In breeding males, both the testis and the vas deferens become enlarged. When in doubt about the sex of the turtle, the coiled vas deferens, even in young turtles, is an important clue (see Urogenital Anatomy, Figs. 221-222).

Lungs. The lungs are located dorsally and are attached to the carapace and vertebral column (Fig. 78). In some species (e.g., *Lepidochelys kempii* and *Caretta caretta*) the lungs are more closely attached to the vertebral column than in other species. The lungs can either be examined in the body, or by removing them. To remove the lungs, free their lateral borders, being careful not to cut into the lung tissue. The medial border of the lung will be firmly attached to each side of the vertebral column. Sometimes it helps to free the trachea from the associated connective tissue prior to breaking the fibrous connections between the lung and the vertebrae.

The trachea bifurcates into two bronchi. A bronchus enters each lung and continues with multiple internal openings into the lung. Each bronchus extends almost to the posterior end. The lungs are spongy and highly elastic.

Urinary bladder and kidneys. The urinary bladder is suspended from the midline on the dorsal surface of the pelvis (Fig. 79). It is located between the rectum and the anterior pelvis (pubis). The bladder opens into the cloaca and is not connected to the kidneys. Urine flows from the kidneys, through the **ureters**, to the cloaca. Urine enters the bladder from the cloaca (see Urogenital Anatomy, Fig. 219).

The **kidneys** are located posterior to the lungs. They are "retroperitoneal" which means that they lie beneath the peritoneal lining next to the carapace.

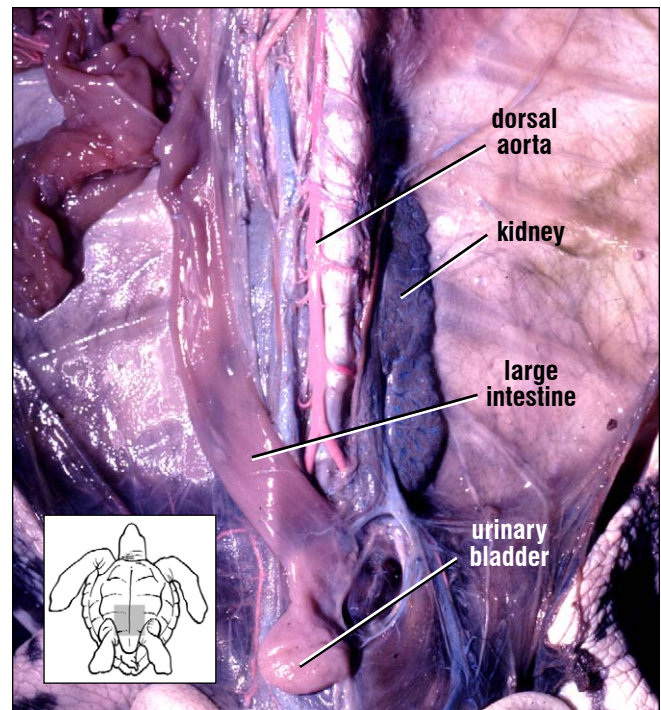


Fig. 79. A kidney in this young leatherback, is exposed and its circulation injected to separate arteries from veins. The urinary bladder is seen on the midline, as is the collapsed large intestine to one side. The dorsal aorta is along the vertebral column and gives off many branches.

They are deep relative to the gonads and slightly medial from the posterior-most border of the lungs. By making a cut in the peritoneum and teasing it away, the lobular red kidneys (Fig. 79) and their extensive systems of arteries and veins can be exposed. The ureters, often difficult to find, extend from each kidney to the cloaca.

At the anterior end of each kidney, and very near the vertebral column, there is a small elongate **adrenal gland**. The adrenal glands are often yellow or orange. They are frequently easier to locate by palpation than by sight (see Glands, Fig. 186).

Brain. To examine the brain, cut off the head near the base of the skull. Secure it with a vice or hold it carefully on a no-skid surface. In *Dermochelys coriacea* the brain and its tracts make a series of dorsoventral turns as it proceeds from anterior to posterior. A single cut will not expose this well

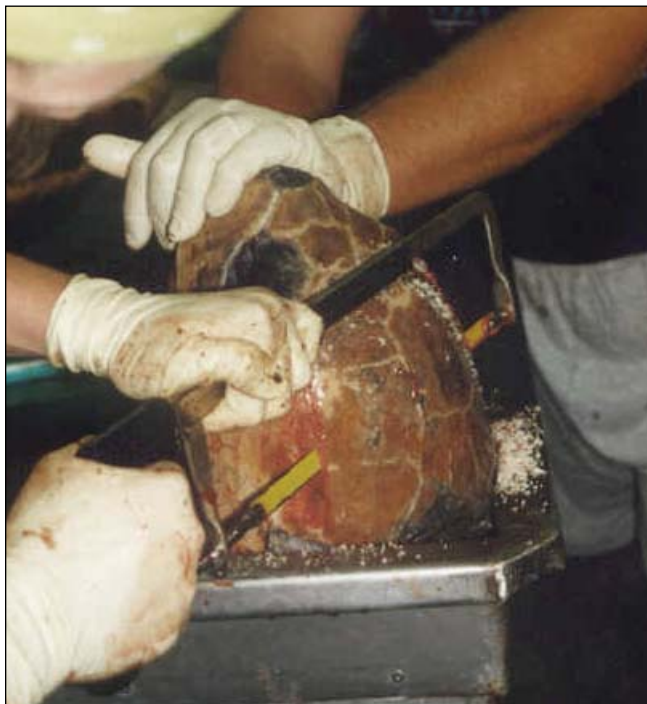

Fig. 80. The brain can be exposed by a cut parallel to the skull's long axis, running from the snout, through the tops of the orbits and posteriorly toward the middle of the supraoccipital crest.

protected structure. In the cheloniids, one of the easiest ways to expose the brain, in the absence of special saws, is to make a straight cut from the top of the snout, proceed along the inside of the top of the orbits, then continue to the posterior end of the head (Fig. 80). Once the skull cap is removed, the small brain can be seen (Fig. 81) with its (anterior to posterior) **olfactory tracts** to the nose, **optic lobes, cerebral hemispheres** and **cerebellum** (see Nervous System, Figs. 187 and 189). Sometimes the fibrous covering, the dura mater, remains covering the brain. This can be cut away.

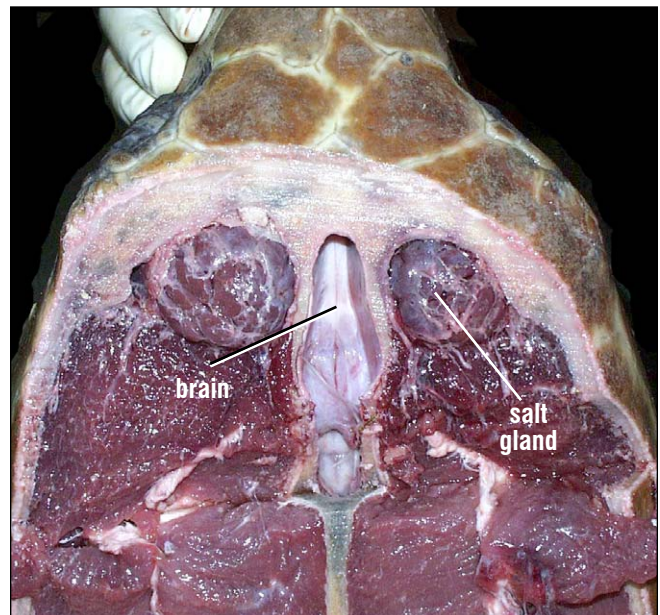


Fig. 81. The brain, along the midline, is elongate and white. Grossly, one can see the olfactory tracts. The olfactory bulbs, cerebral hemispheres, and optic lobes are covered by the dura mater; the cerebellum is the single round structure at the end of the exposed brain. If the brain is removed, then lateral and ventral cranial nerves and the pituitary can be seen. The two round, lobed structures dorsal and posterior to the eyes are the salt glands. The remaining dark tissue is muscle.

Skeletal Anatomy

The skeleton is composed of bones and cartilages. Typically, it is divided into 3 main parts: the skull, axial skeleton and appendicular skeleton (Figs. 82-84). In sea turtles, each of these bony groups is a composite of several structures. The **skull** includes the **braincase**, **jaws**, and **hyoid apparatus** (Figs. 85-86). The **axial skeleton** is

composed of the carapace, vertebrae, and ribs and the derivatives of the ribs. The **plastron** (Fig. 83) is a composite including derivatives of the axial and appendicular skeleton (ventral ribs plus shoulder elements). The appendicular skeleton includes the **flippers**, **hind limbs**, and their supporting structures (the **pectoral** and **pelvic girdles**).

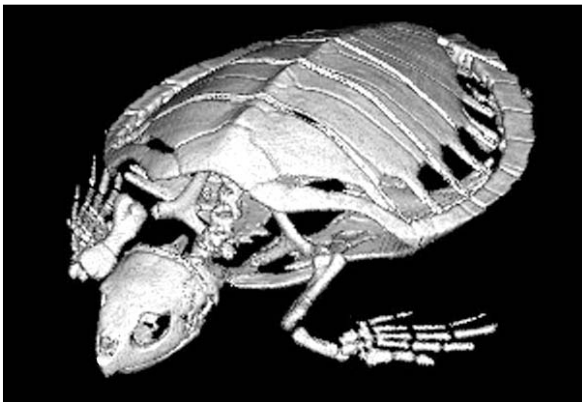


Fig. 82. *This CT (computed tomography) scan of an immature ridley turtle shows the three parts of the skeleton: the skull, axial, and appendicular skeletons and the spatial relationships of the bones. Cartilage (at the ends of many bones) is not detected by this imaging technique so bones appear loosely articulated. The arrangement of the forelimbs is such that the shoulder joint is inside the shell. The elbow flexes so the forearm moves from an anterolateral position to a medial position. Lines crossing the posterior skull and carapace are image processing artifacts.*

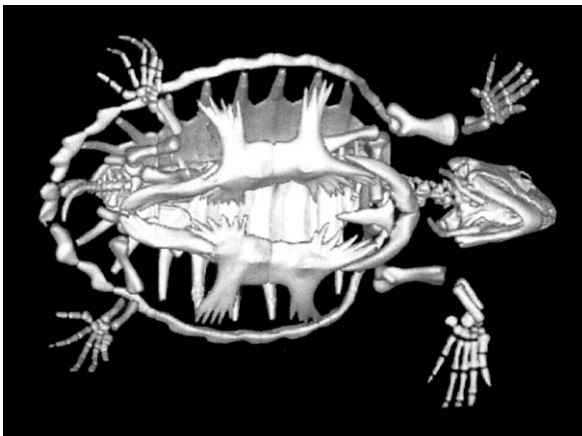


Fig. 83. *Individual plastron bones are not fused in immature turtles. The processes from the lateral plastron do not yet articulate with the peripheral bones. The hyoid apparatus (the body of the hyoid and both bony hyoid processes), which is usually lost in skeletal preparations, can be seen in the throat region. The distal phalanges of the flippers were outside of the field of view in this CT scan so the ends of the flippers are omitted.*

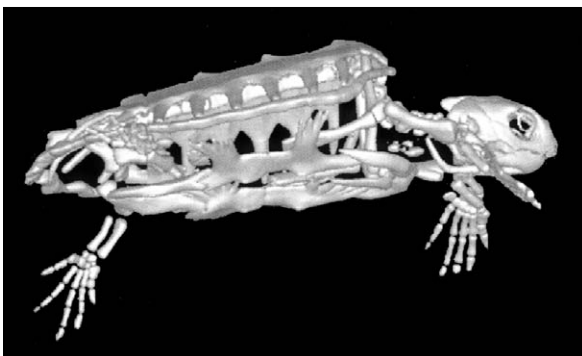
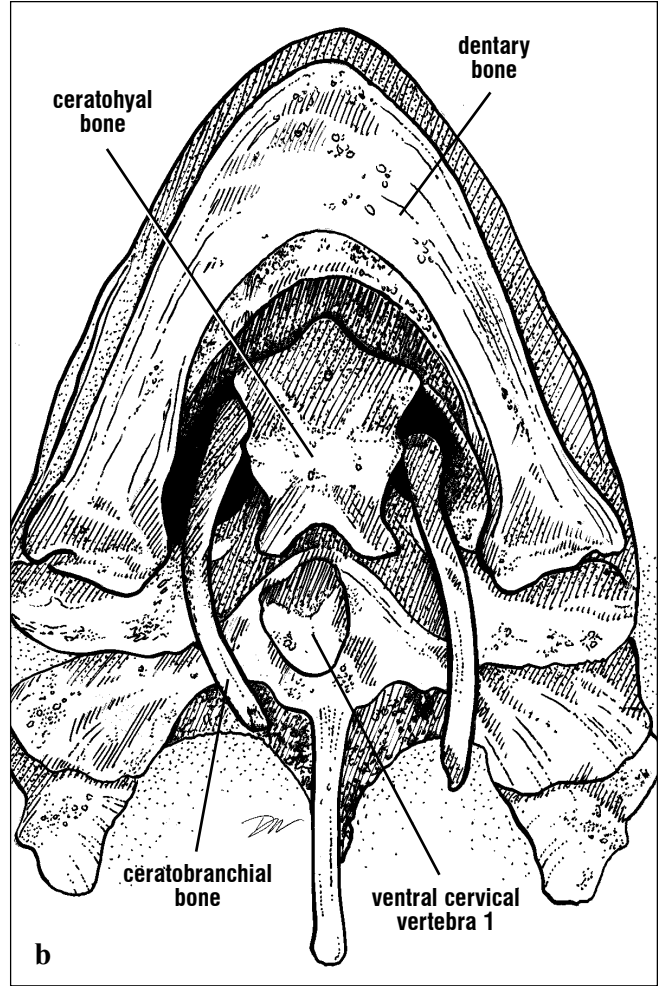
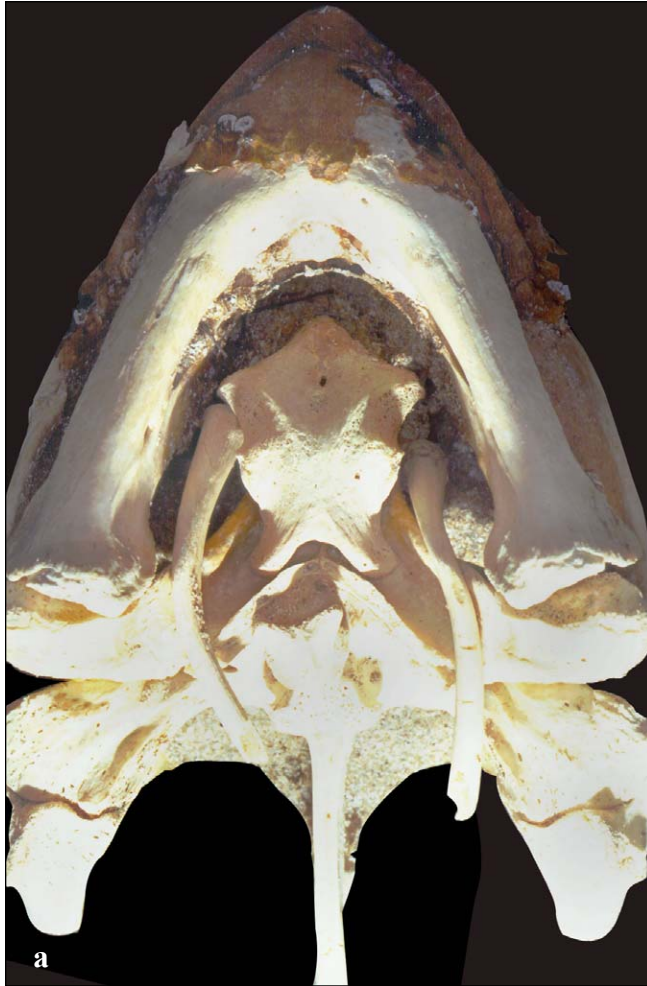

Fig. 84. *In this lateral view of an immature loggerhead, the hyoid process can be seen clearly as it passes posterior and ventral to the skull. Note that the orbits contain a ring of bones (scleral ossicles) that support the eyes. The right hind limb is directed laterally so it cannot be seen clearly.*



Figs. 85a and 85b. Loggerhead skull (ventral) showing parts of the ceratohyal or the body of the hyoid, and paired hyoid processes of the hyoid apparatus. Two cartilaginous hyoid processes are lost in skull preparation. Hyoid bones are loose in the prepared skull but are suspended between and behind the lower jaws in life. The hyoid apparatus supports the tongue and glottis and serves as muscle attachment sites for some of the throat muscles. Part of the atlas (ventral cervical vertebra 1) is resting on the occipital part of the skull, posterior to the hyoid apparatus.

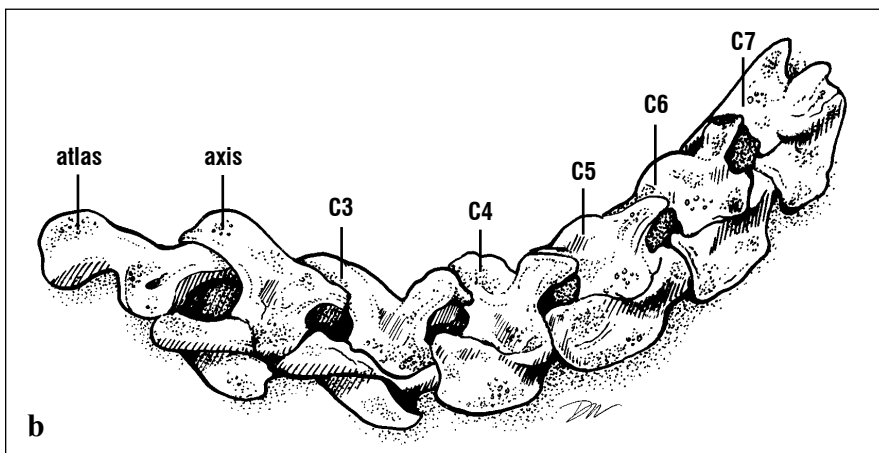


Fig. 86. Hyoid apparatus. The hyoid body supports the glottis in its concavity. Muscles attach to the hyoid processes (ceratobranchial bones) that move the throat. Cartilaginous processes are missing.

SKELETAL ANATOMY

Like all turtles, sea turtles have 7 mobile cervical vertebrae (an 8th is fused to the carapace; Figs. 87-88) and 10 thoracic vertebrae. There are 2-3 sacral vertebrae and 12 or more caudal vertebrae (Figs. 89-90). The caudal vertebrae of females are short and decrease in size distally; those of mature males are large with robust lateral and dorsal processes (Fig. 89). Each thoracic vertebra articulates with a pair of ribs, bilaterally arranged. Each rib head is aligned with the junction of two vertebral bodies (Fig. 91). Fusions of vertebrae

and ribs with dermal bone result in unique carapacial bones. **Neural** bones are associated with the vertebral column, **pleurals** are formed by the ribs and their dermal expansions, and **peripheral** bones form the margin of the carapace (Figs. 92-93). The anterior-most bone is the **nuchal** and the posterior-most is the **pygal**. Between the last neural bone and the pygal is the **suprapygal**, which lacks any vertebral fusion (Figs. 92-93). The lateral processes of the sacral vertebrae are not fused to the carapace (Fig. 89).



Figs. 87a and 87b. Lateral view of the cervical vertebrae from an adult green turtle. Each vertebra is composed of a ventral body and a dorsal arch. The ventral part of the atlas is missing from this series. The atlas articulates with the occipital condyle at the back of the skull. C7 articulates with the cervical vertebra fused to the carapace.

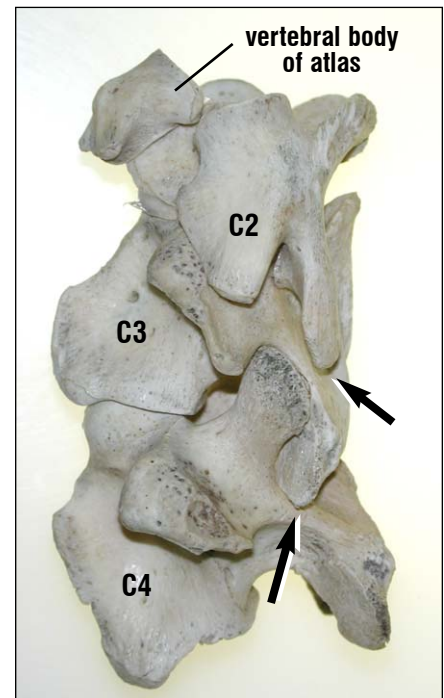
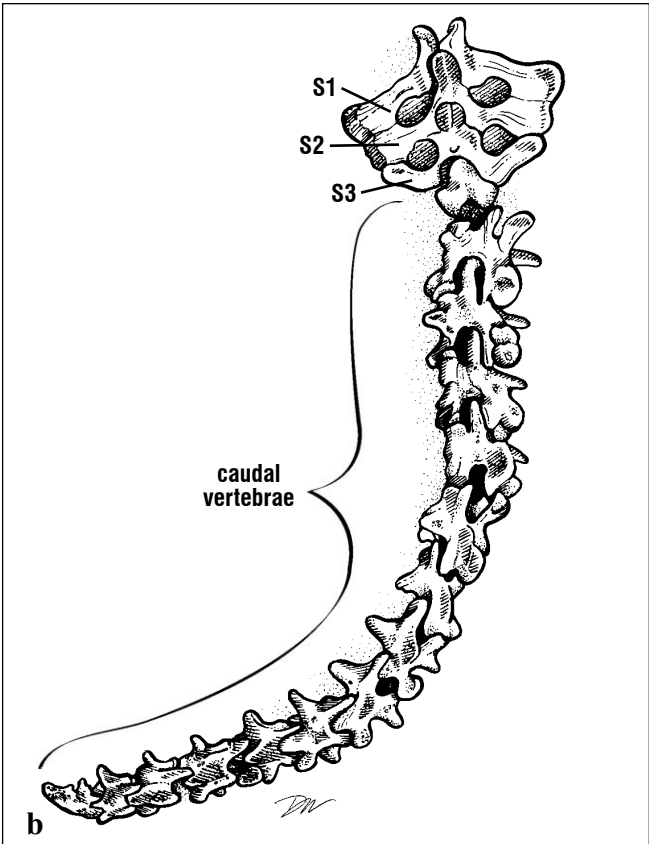



Fig. 88. The atlas (C1) and axis (C2) complex and C3 - C4, in lateral view. Dorsal is to the right. The vertebral arches of the successive cervical vertebrae articulate via sliding joints (arrows) that allow some dorsal-ventral bending of the neck, but little twisting. Each vertebra is composed of separate dorsal and ventral elements.



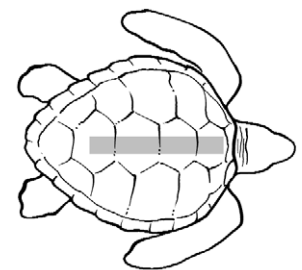
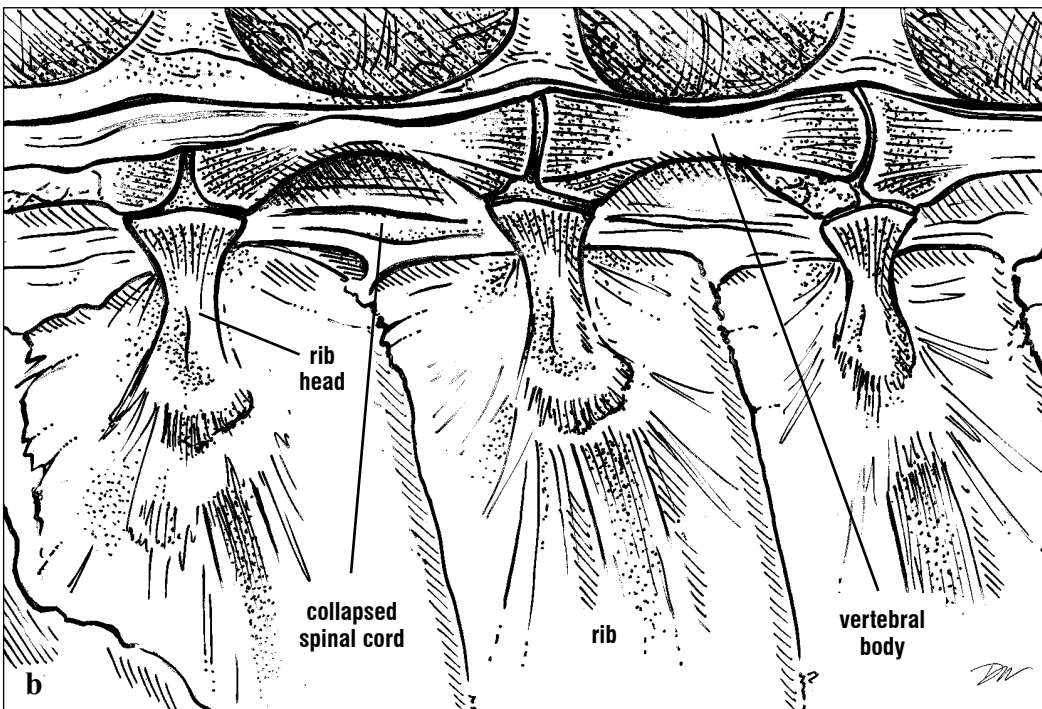
Figs. 89a and 89b. The sacral and caudal vertebrae of an adult male green turtle. The large dorsal and lateral processes are the sites of attachments for the muscles

that move the prehensile tail of mature males. S: sacral. The lateral extensions of the sacral vertebrae are formed by rib-like processes that articulate with the ilium.

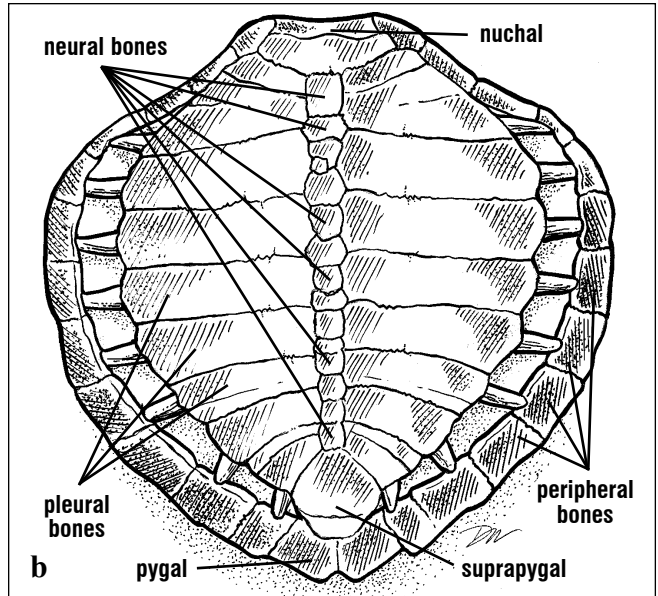

In hatchlings and *Dermochelys*, the carapace is composed of ribs and vertebrae. In cheloniids, as they mature, the shell becomes increasingly ossified. Dermal bone hypertrophies between the ribs and grows outward to form the carapace (Figs. 90 and 92-93). The ribs grow laterally to meet the peripheral bones (lying beneath the marginal scutes) in *Caretta caretta*, *Eretmochelys imbricata* and *Chelonia mydas*. In *Lepidochelys kempii*, the peripheral bones also widen with age and increasing size. The spaces between the ribs and the carapace, **fontanelles**, are closed by a membrane underlying the scutes. The fontanelles are closed completely by bone in some adult ridleys and loggerheads, but are retained posterolaterally in green turtles and hawksbills (Fig. 93).

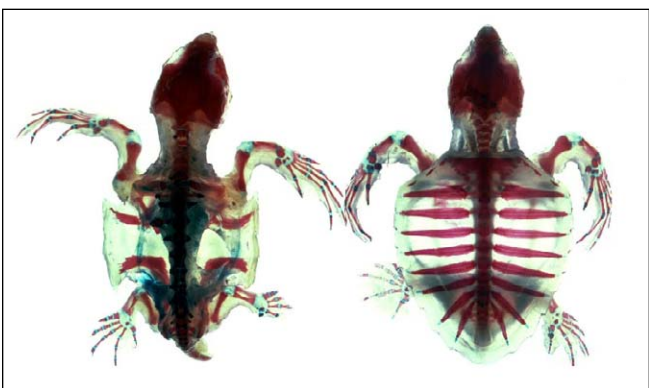

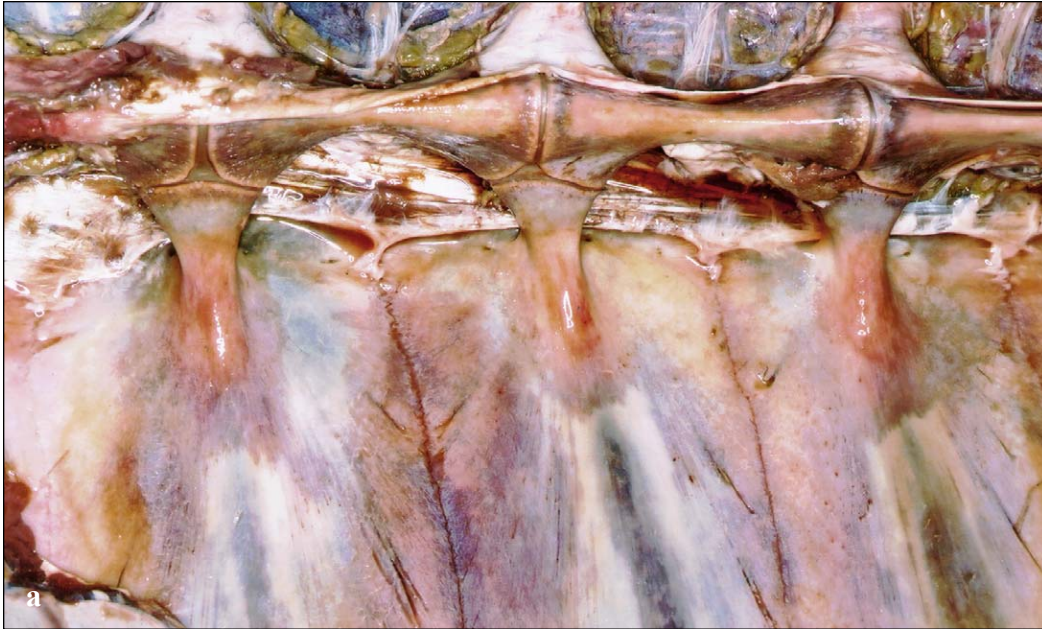Fig. 90. Cleared and stained hatchling loggerheads. (Left) Dorsal view with carapace removed showing vertebral regions and the level of ossification at the time of hatching. (Right) Dorsal view showing ribs, vertebrae and initial dermal bone hypertrophy along the ribs as the carapace develops. The plastron was removed in this specimen.

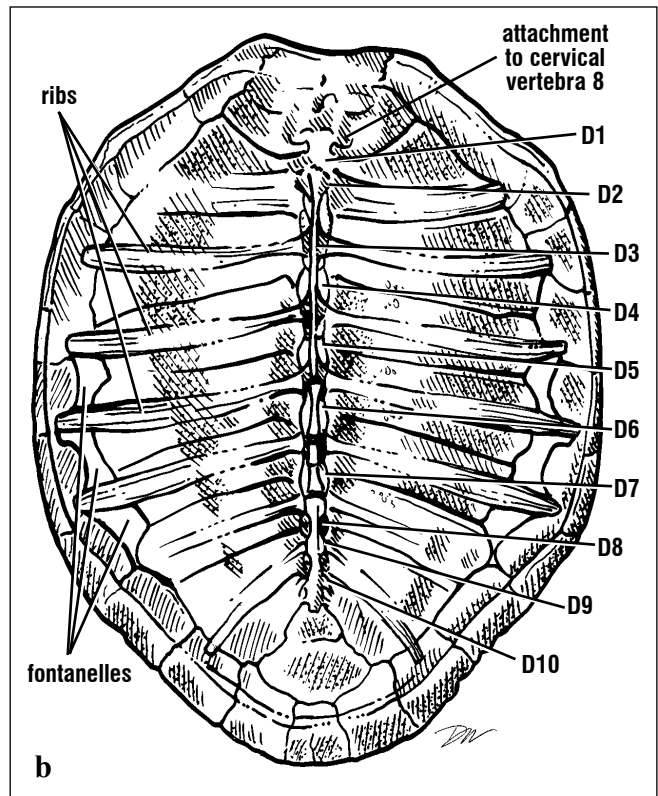
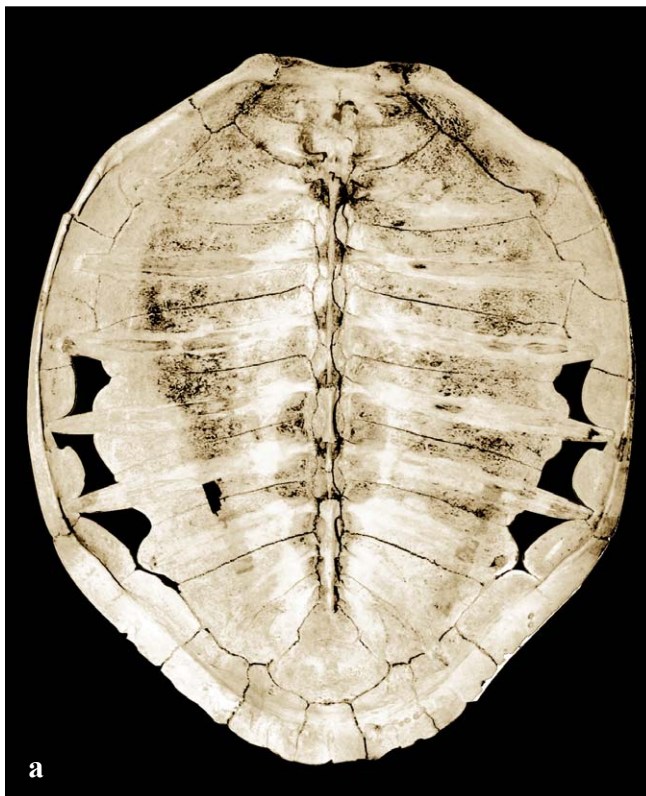


Figs. 91a and 91b. Ventral view of the carapace showing the arrangement of the ribs and vertebral bodies. The vertebral arch is incorporated into the vertebral (neural) bones of the carapace and hence, is not seen in this view. The spinal cord travels in the space formed between the neural bones and the vertebral bodies.



Figs. 92a and 92b. The bones of the carapace dorsal view are identified in this Kemp's ridley. The

bony arrangement of the shell is such that in some species supernumerary neural bones are common.



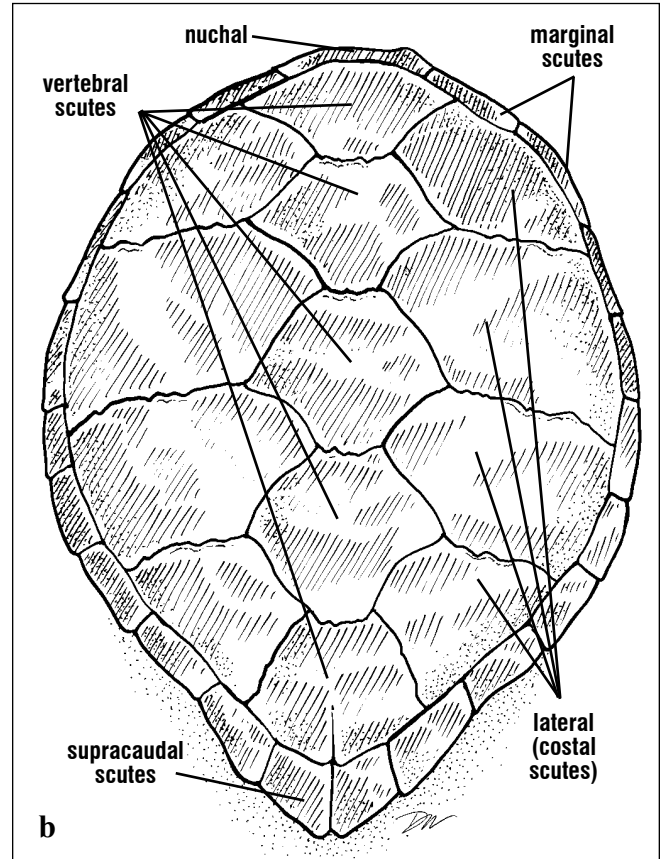
Figs. 93a and 93b. Ventral view of this hawksbill carapace shows the vertebral bodies (dorsal elements), ribs, and fontanelles. The ribs have

fused with the peripheral bones anteriorly. D: dorsal elements.

SKELETAL ANATOMY

The carapace is composed of bone covered by keratinous scutes (cheloniids, Fig. 94) or blubber and skin in *Dermochelys* (Fig. 95). The margins of cheloniid scutes and the bones' sutures do not align

with one another (Fig. 96). In the leatherback, the blubber overlies ribs and vertebrae and itself is covered dorsally with waxy skin and embedded dermal ossicles (Fig. 95).



Figs. 94a and 94b. The scutes are keratinous epidermal structures that grow above the carapace bones. Scutes grow two ways. They increase in size

(area) at their margins. The entire scute can increase in thickness.

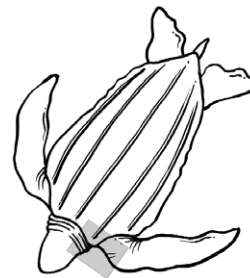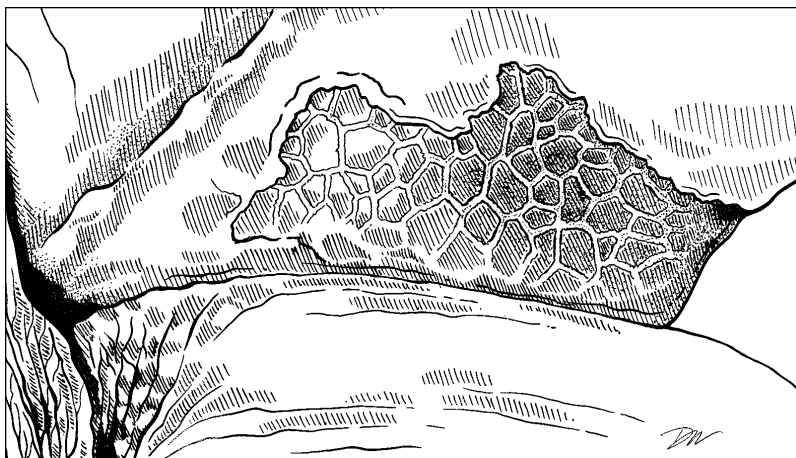


Fig 95. Dermal ossicles are bony plates that reside deep to the skin in the leatherback carapace.

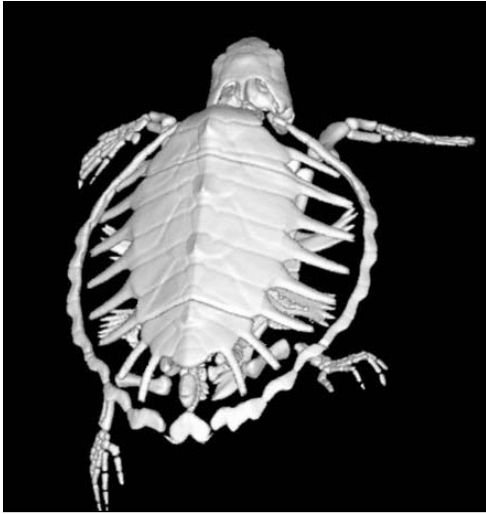
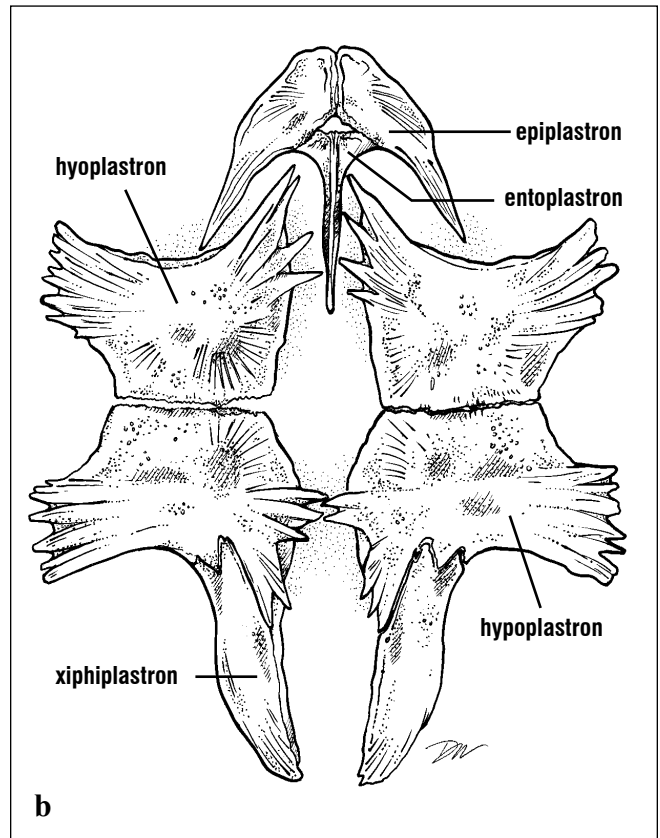
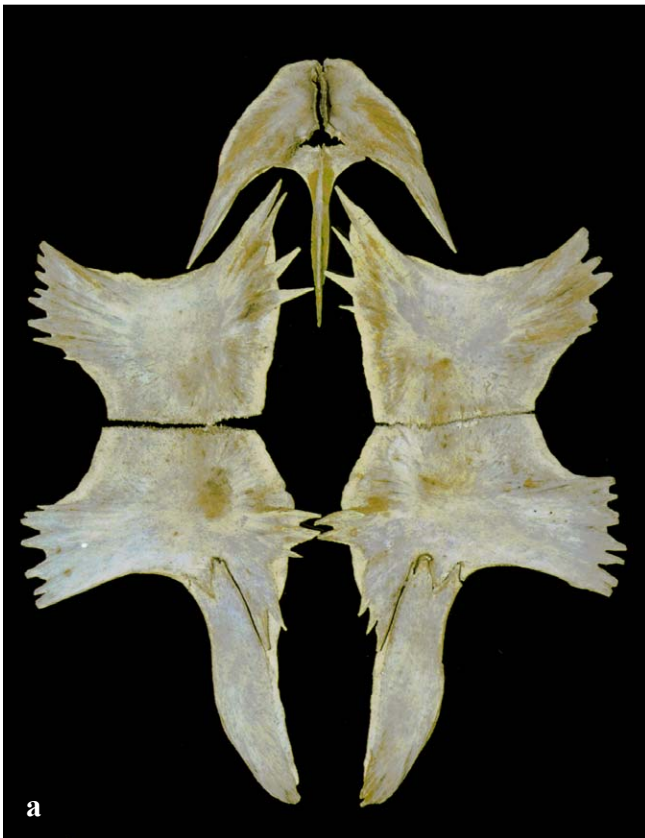

Fig. 96. *Immature loggerhead skeleton showing outgrowth of dermal bone to form the shell. The spaces between the ribs and the peripheral bones are the fontanelles. The pattern of the scutes is barely visible but hints at the lack of alignment with bony sutures. The distal parts of the flippers are cut off by the field of view in this CT image.*

The plastron is composed of 4 pairs of bones in sea turtles (from anterior to posterior: **epiplastron**, **hyoplastron**, **hypoplastron** and **xiphiplastron**) and

1 unpaired bone (**entoplastron**; Fig. 97). The shape of the entoplastron bone is sometimes used as a key characteristic (Fig. 98) for species identification.



Figs. 97a and 97b. *The plastron is composed of 9 bones that are separate in hatchlings but become*

fused in older turtles. Anterior is toward the top of the picture.

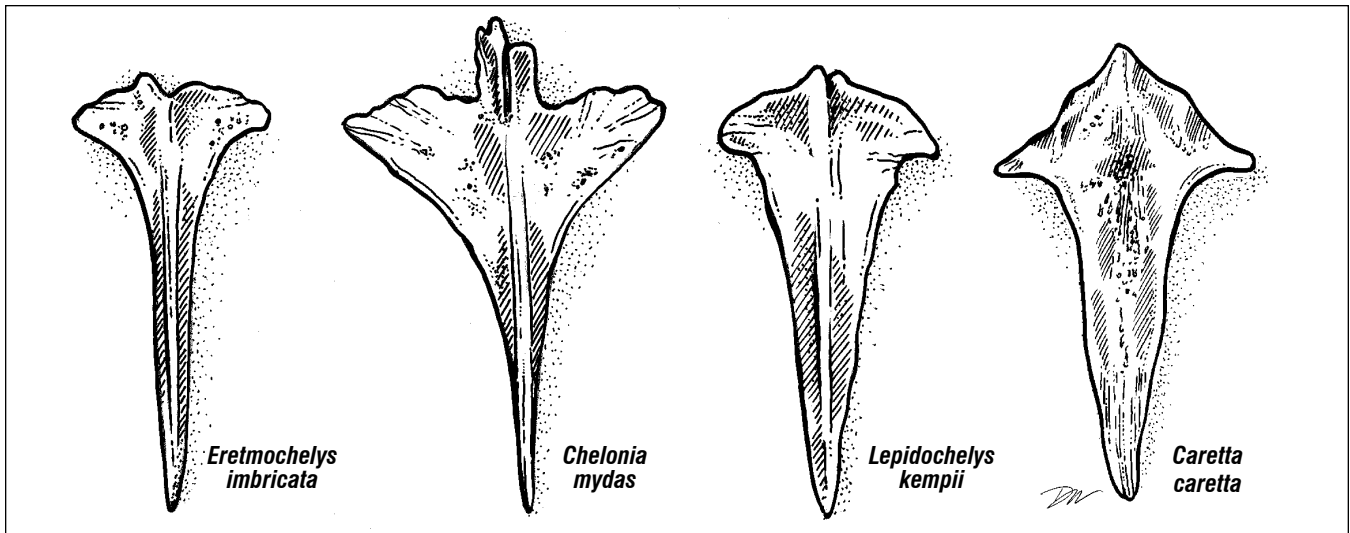


Fig. 98. The distinct shape of the entoplastron bones may serve as a key characteristic to distinguish some cheloniid species. In *E. imbricata* and *C. mydas* the elongated shaft is narrow. The bone is roughly T-shaped in hawksbills and the shaft narrows abruptly. It is arrow-shaped in green turtles; wide anteriorly with a shaft that narrows gradually. In *L. kempii* and *C. caretta*, the shaft is wide. The overall shape

is almost dagger-like in the Kemp's ridley as the shaft narrows gradually. The bone is cruciform in loggerheads; the lateral processes are distinct and the shaft tapers along its posterior half. The entoplastron has not been described diagnostically for the olive ridley. Entoplastron bones change shape during ontogeny, hence it is recommended that this characteristic be used only in adults.

In *Dermochelys*, there is no hypertrophy of bone between the ribs of the carapace. The bony carapace remains composed solely of an expanded nuchal, ribs, and vertebrae. Ventrally, the plastron is composed of a ring of reduced plastron bones. No entoplastron is present.

The anterior appendicular skeleton includes the flippers and pectoral girdles. The pectoral girdles are composed of two bones, the **scapula**, with its **acromion process**, and the **coracoid** (= procoracoid); these form a triradiate structure (Fig. 99).

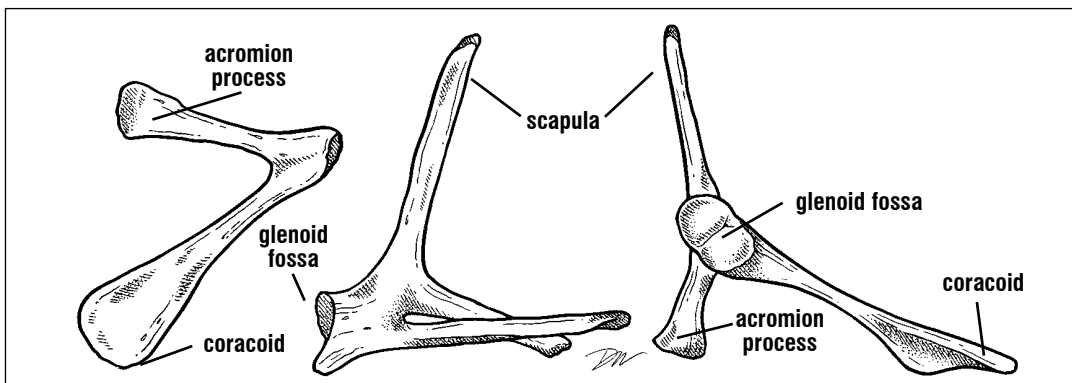


Fig. 99. The pectoral girdle, (left to right) in ventral, posterior, and anterior views, is composed of two bones and 3 parts that serve as a major site for attachment of the swimming musculature. The acromion process extends medially from the ventral part of the scapula. The coracoid a ventral bone, is flat and wide distally. The shoulder joint (glenoid fossa), is formed by the coracoid and the scapula. (After Wyneken, 1988).

The scapula is aligned dorsoventrally and attaches to the carapace near the first thoracic vertebra. Ventrolaterally it forms part of the shoulder joint, the **glenoid fossa** (Fig. 99). The acromion processes extend medially from each scapula to articulate with the entoplastron via ligaments. The coracoids form the remainder of the glenoid fossa and then extend posterior medially. Each terminates in a crescent-shaped coracoid cartilage. The **acromialcoracoid** ligament extends from the acromion to the coracoid. The majority of the flipper retractor and abductor muscles attach to the coracoid processes and the acromialcoracoid ligaments.

The forelimb is composed of the **humerus, radius** and **ulna, carpals, metacarpals**, and 5 **phalanges** (Figs. 100-103). The flipper blade is formed by widening and flattening of the wrist bones and elongation of the digits (Fig. 100). The humerus, which articulates with the shoulder at the glenoid fossa, is flattened with its head offset by $\sim 20^\circ$ from the bone's shaft (Fig. 101). There is a large bony **medial process** extending beyond the humeral

head to which flipper abductor and extensor muscles attach (Fig. 101). Distal to the head and almost diagonally opposite is the **lateral process** or deltoid crest to which attach flipper protractor muscles (Figs. 101-103). In *Dermochelys*, the humerus is extremely flattened. It is composed primarily of **cancellous** bone, relatively little **cortical** lamellar bone, and with thick vascular cartilage on its articular surfaces (Figs. 104-105). In prepared skeletons, the cartilage is often lost. The extensive vascular channels in the cartilage are indicative of chondro-osseous bone formation (Fig. 104). This is unlike the cheloniid bone, which is formed by deposition of relatively thick layers (lamellae) of cortical bone around a cellular bony core (cancellous bone; Fig. 105).

The flipper (Fig. 100) is composed of wrist elements (**radiale, ulnare, centrale, pisiform, distal carpals**) and elongated **metacarpals** and **phalanges** (Figs. 100, 102-103). The **radius** and **ulna** are short in sea turtles and, in adults, functionally fused by fibrous connective tissue.

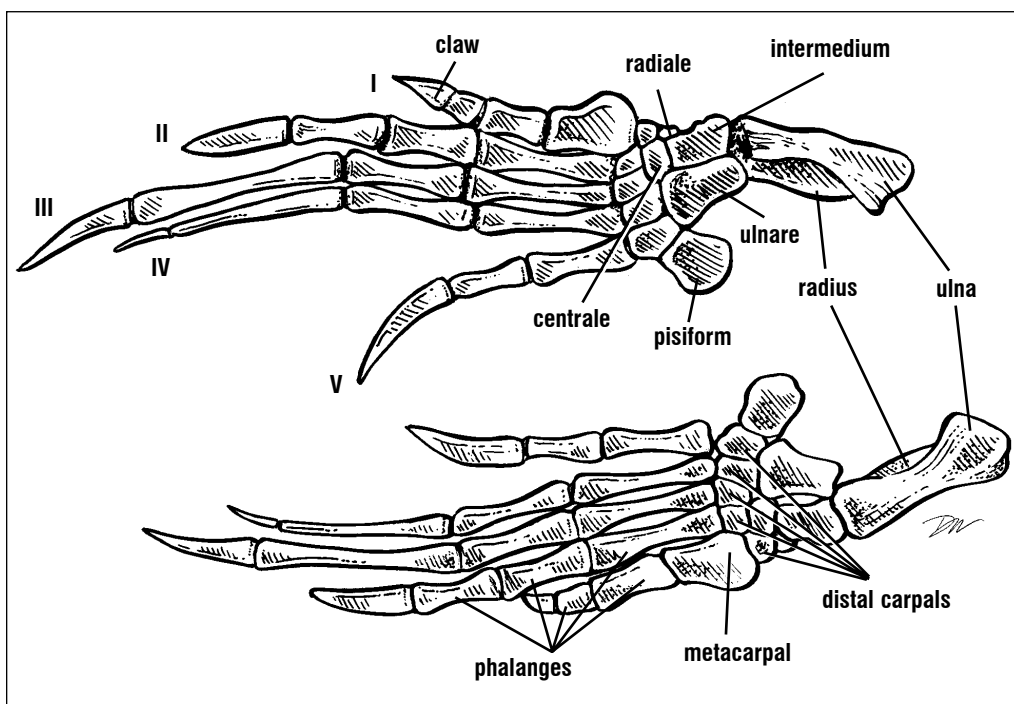


Fig. 100. *Skeletons of flippers (left and right) shown in dorsal view. Note the flat wide wrist and the elongated digits that form the flipper blade.*

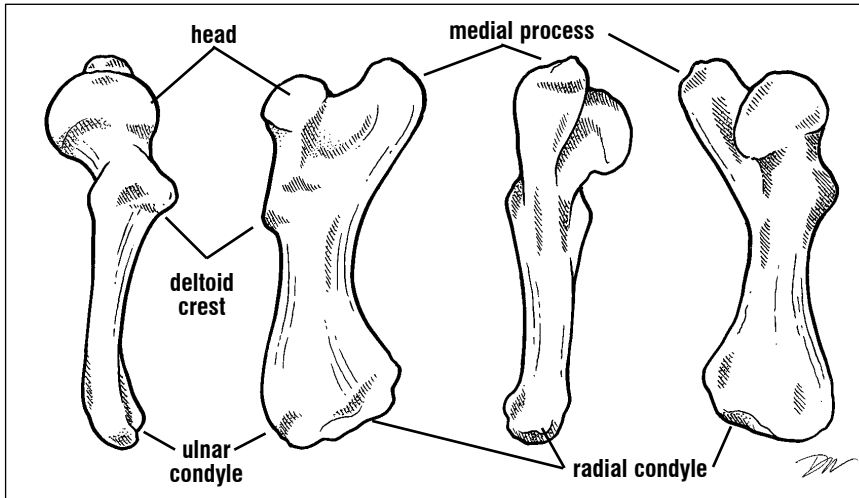
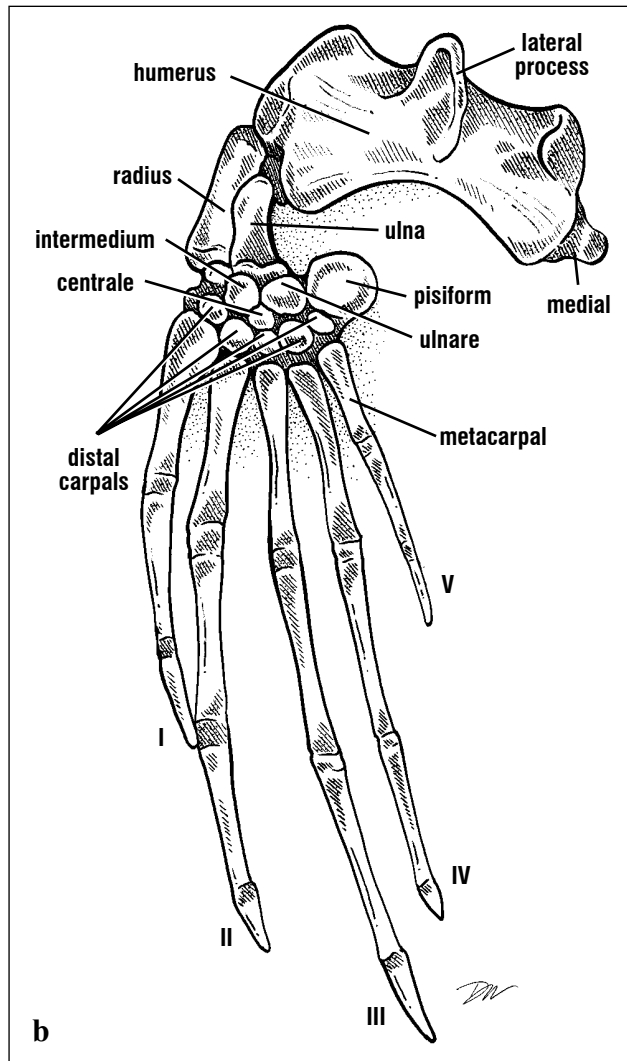
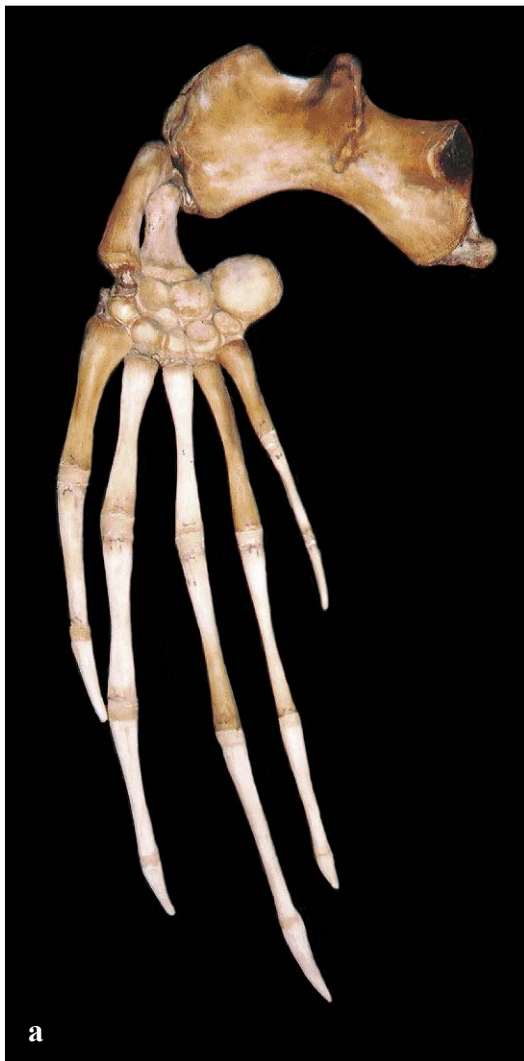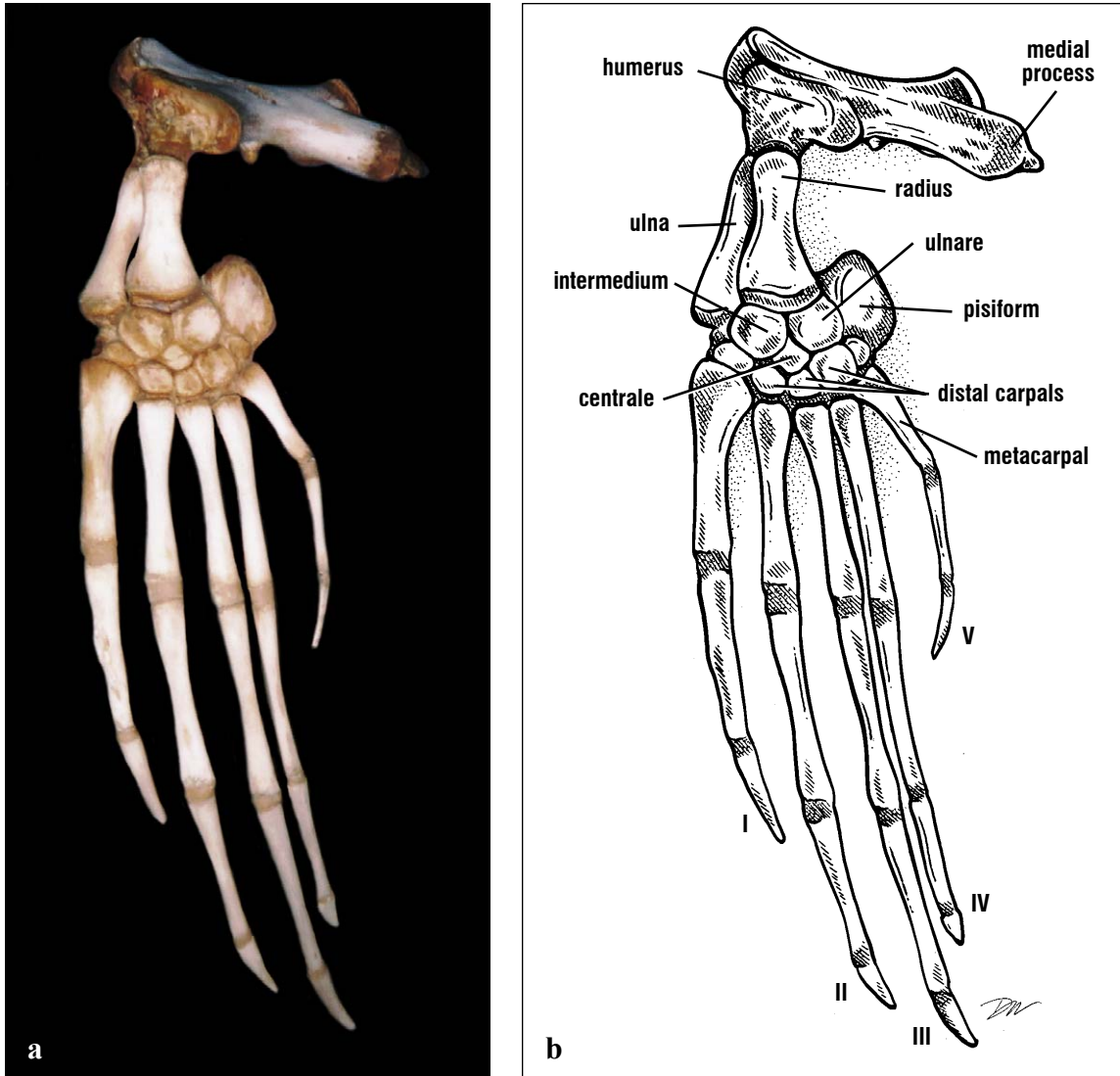


Fig. 101. *The cheloniid humerus is distinctive in its form with a slightly offset head and enlarged medial process. Almost opposite the medial process and just distal to the head is a U-shaped lateral process (deltoid crest) to which attaches the major ventral swimming muscles. (After Wyneken, 1988).*



Figs. 102a and 102b. *Dorsal view of a leatherback flipper.*



Figs. 103a and 103b. *Ventral view of the leatherback flipper. The articulated forelimbs of this leatherback shows some of the extensive cartilages at the bone ends and the extreme elongation of the digits. The large humerus has an almost primitive form with its flattened profile and extended medial process. The head and distal articulations to the radius and ulna are largely cartilaginous.*

The pelvis is composed of 3 pairs of bones; **pubis**, **ischium**, and **ilium**. The pubic bones and the ischia form the ventrally positioned part of the pelvis (Fig. 106). The two ilia are oriented dorsoventrally, articulate with the sacral vertebrae, and attach the pelvis to the carapace via ligaments. All 3 bones form the **acetabulum** (hip socket) on each side.

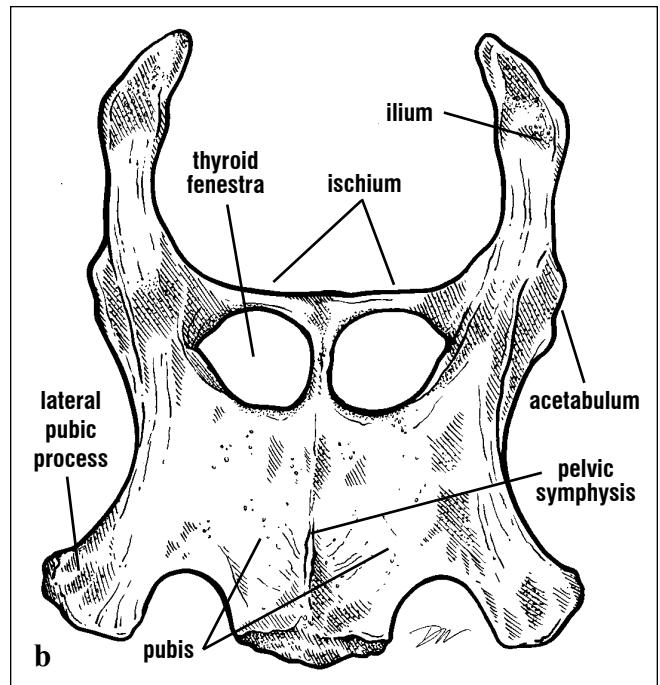
They are separate bones joined by cartilage in hatchlings but quickly ossify and fuse to form a single structure in older turtles. The pelvic bones of the leatherback, however, remain connected by cartilage throughout life (Fig. 107) and become separate elements when skeletons are prepared.

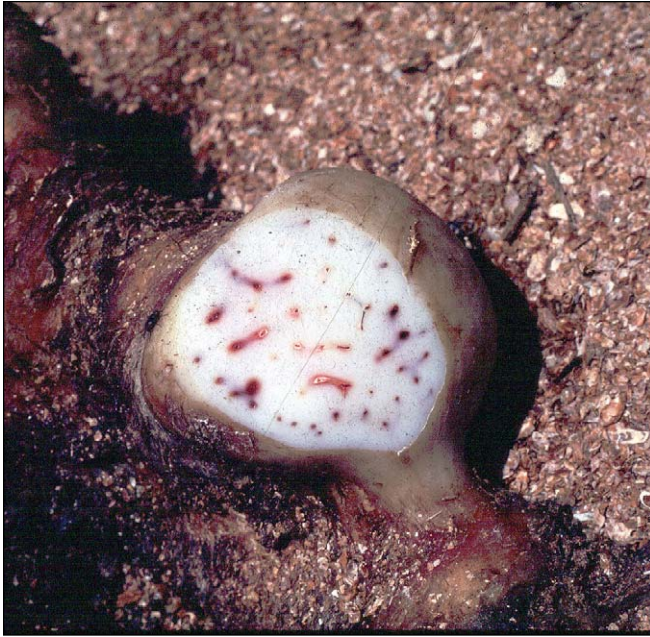

Fig. 104. Chondro-osseous bone formation. Vascular channels are seen in this cut end of a leatherback humerus.

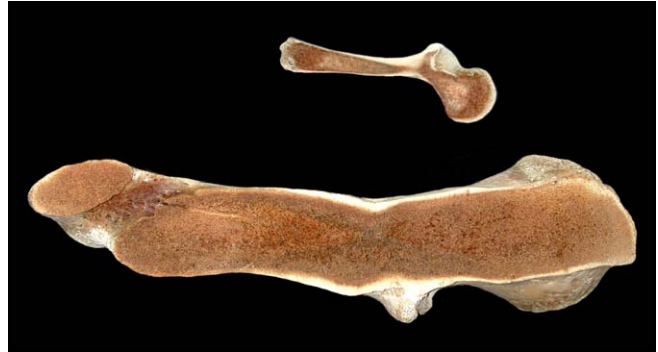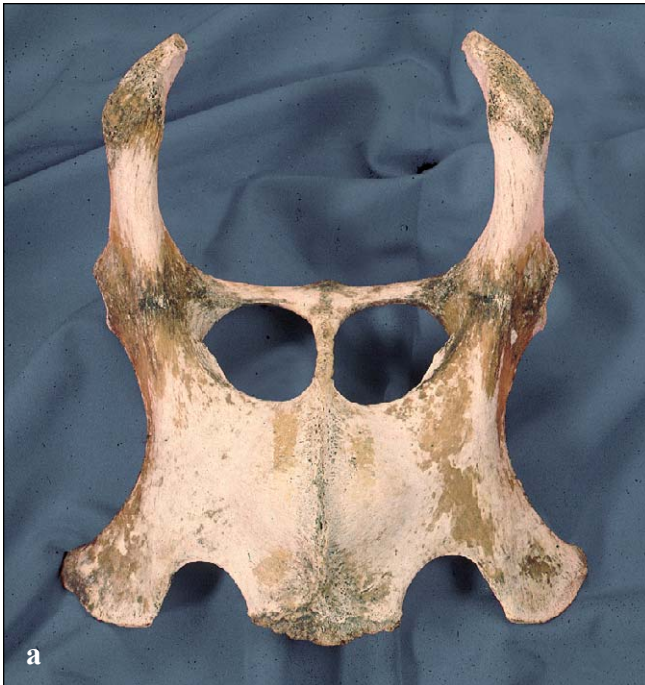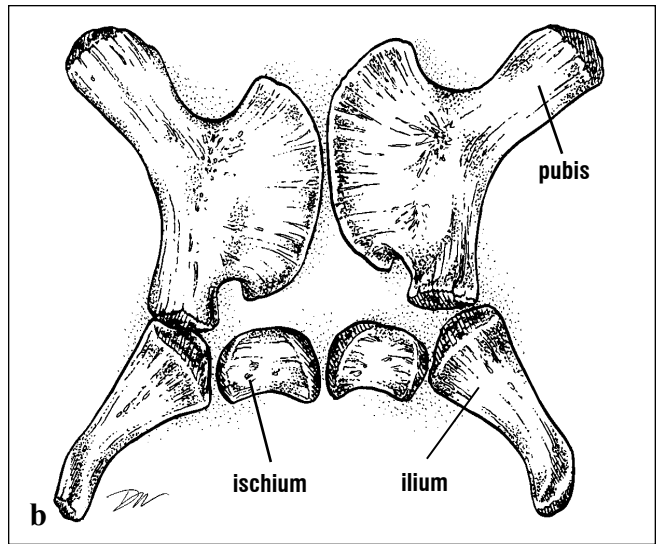


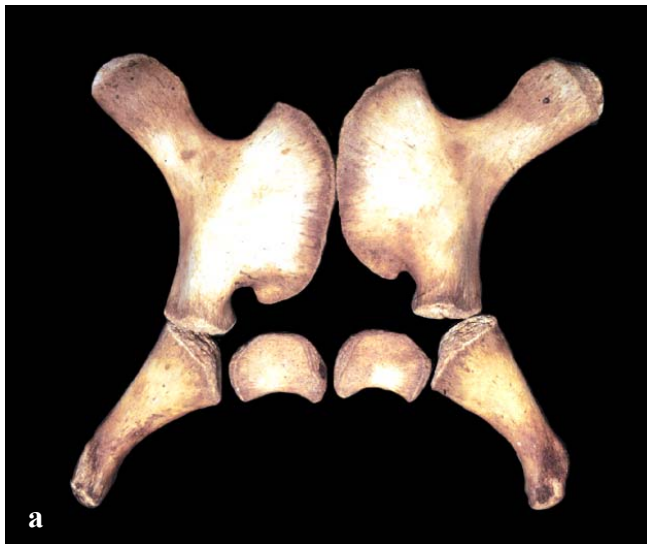Fig. 105. Longitudinal sections through humeri. The loggerhead humerus (top) has relatively more lamellar bone (light color) than in the leatherback humerus (bottom). The lamellar bone is deposited in layers in some cheloniid species and populations; in others, layers are not distinct.



Figs. 106a and 106b. This loggerhead pelvis, dorsal view, shows the 3 bones fused (pubis, ischium, and ilium) that form each side. The epipubic cartilages that would form the anterior edge of the

pelvis in life are missing from this preparation. The ilia articulate with the sacral vertebrae and carapace. Anterior is toward the bottom of the picture.



Figs. 107a and 107b. The pelvis of the leatherback is composed of both bone and cartilage throughout life. Hence, skeletal preparations of the pelvis

usually result in 3 pairs of bones which do not retain their spatial relationships. Anterior is toward the top of the picture.

The hind limb articulates with the pelvis via the head of the femur which fits in the acetabulum. The femur has a relatively straight shaft with a strongly offset head. There are **major** and **minor trochanters** distal to the head (Fig. 108); these are attachments for most of the thigh retractors and adductors,

respectively. The distal femur articulates with the tibia and fibula. The short ankle consists of the **calcaneum, astragalus, and distal tarsals**. There are five digits. The 1st and 5th metatarsals are wide and flat and the phalanges are extended adding breadth to the distal hind limb area (Figs. 109 - 110).

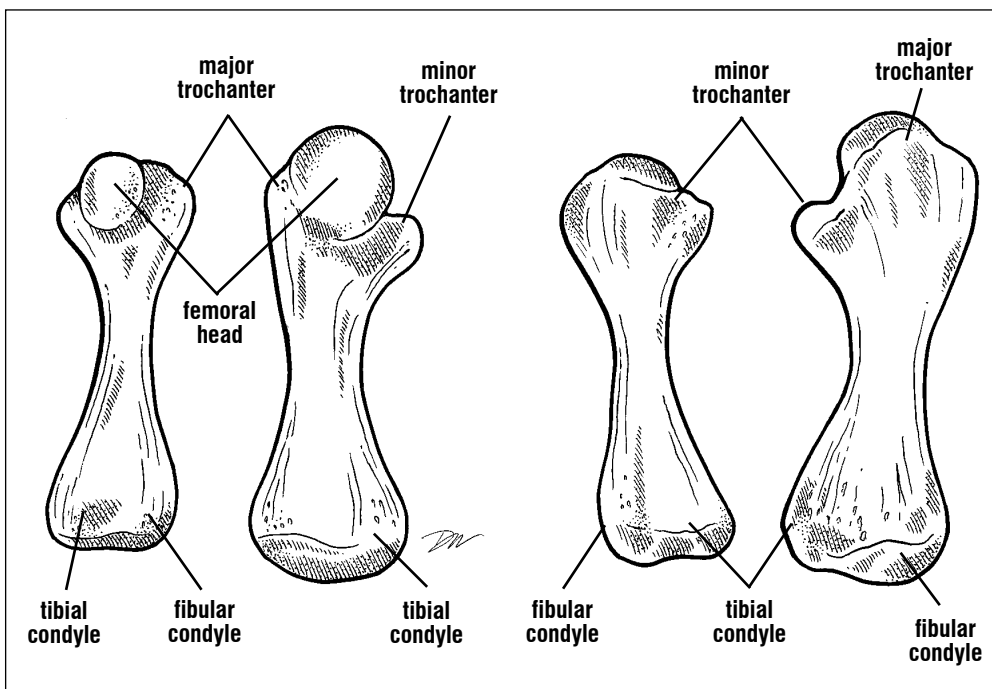
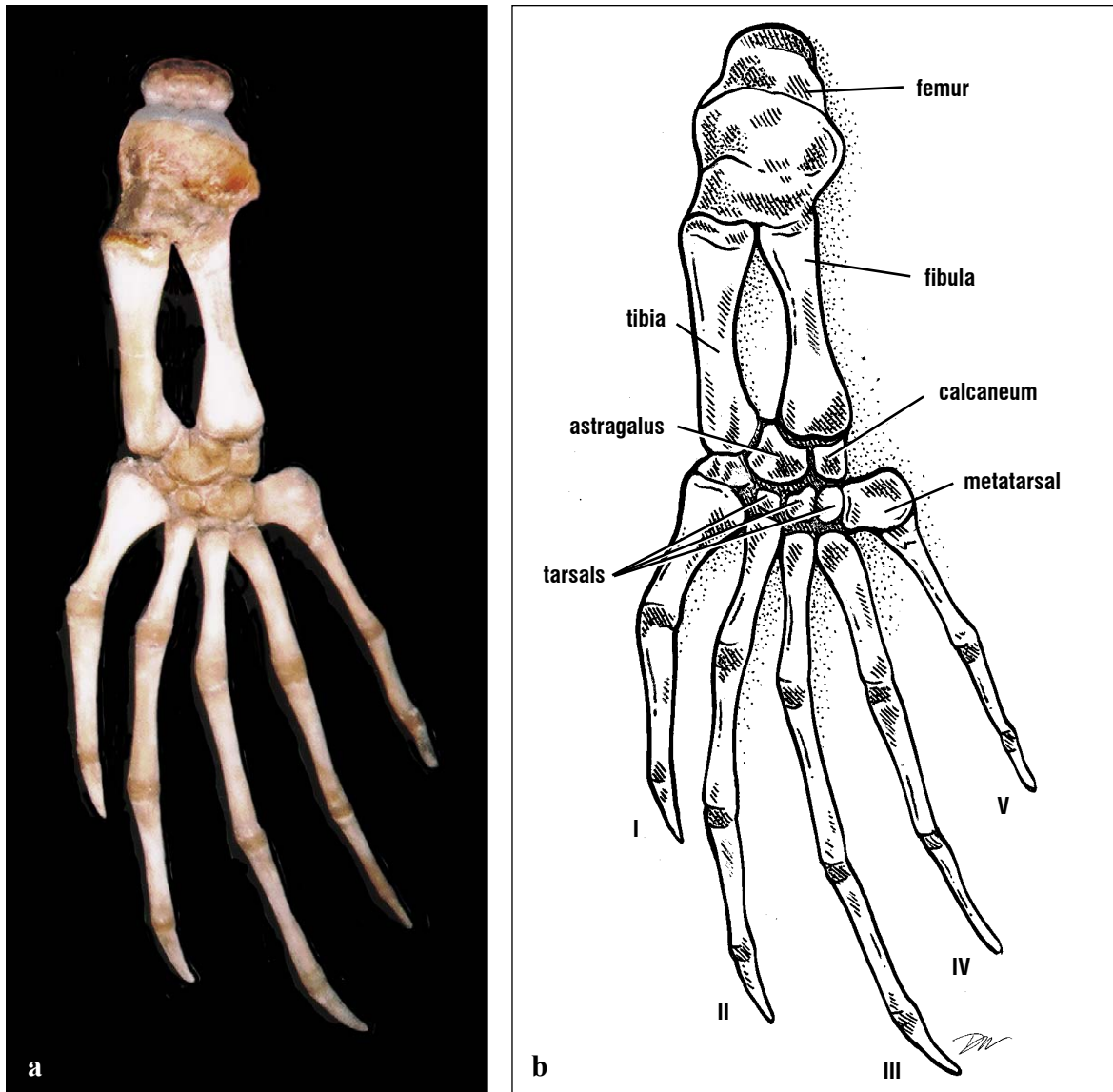
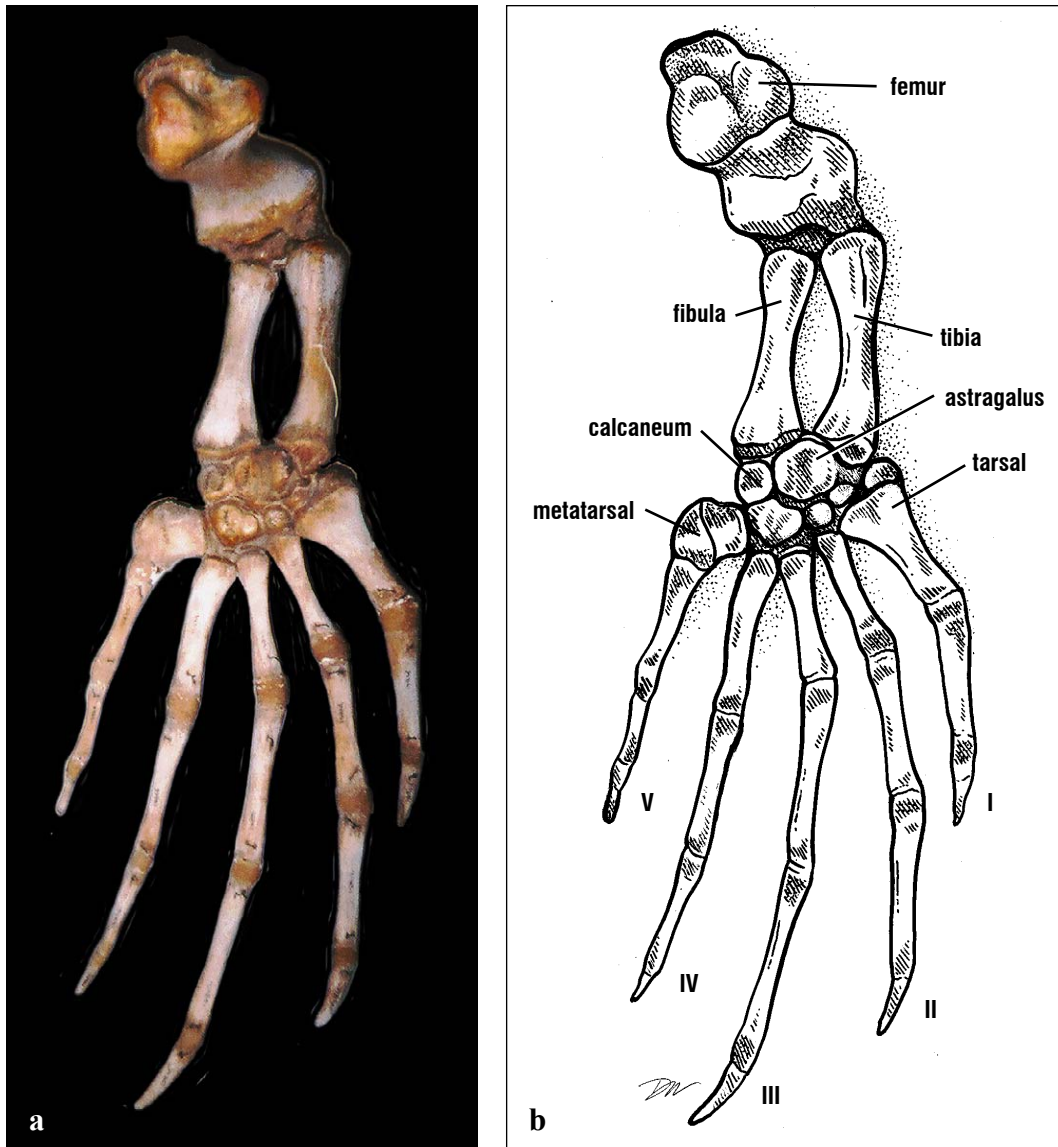


Fig. 108. Left and right femurs anterior view (left) immature turtle, posterior view (right) mature turtle. The femur, an hour glass-shaped bone, has an offset head. The trochanters become more pronounced as the turtles age.



Figs. 109a and 109b. Dorsal view of a leatherback hind limb. The articulated hind limb shows the extensive cartilages between bones that are typical of the leatherback skeleton. The hind foot is wide and the digits somewhat elongated. Digits are designated by numbers, with *I* being the digit on the tibial side and *V* on the fibular side.



Figs. 110a and 110b. *Ventral view of the leatherback hind limb. The femur is the bony element of the thigh, the tibia and fibula are the bony elements of the shank. The ends of these bones are cartilaginous. The ankle is somewhat flattened and laterally expanded, resulting in wide placement of the digits. This architecture contributes to the rudder-shape of the hind limb.*

Muscle Anatomy

The muscles are responsible for moving structures, modifying the function of other muscles, and stabilizing joints. Muscles originate and insert via tendons. The origin of a muscle is its fixed point while the insertion is typically the point that it moves. Muscles can attach via their tendons to bones, muscles, skin or eyes. Where known, the innervations of the muscles are reported. For reading ease, the designation of *M.*, prior to muscles names, has been omitted. Names and key concepts are given in bold the first time the muscle is discussed.

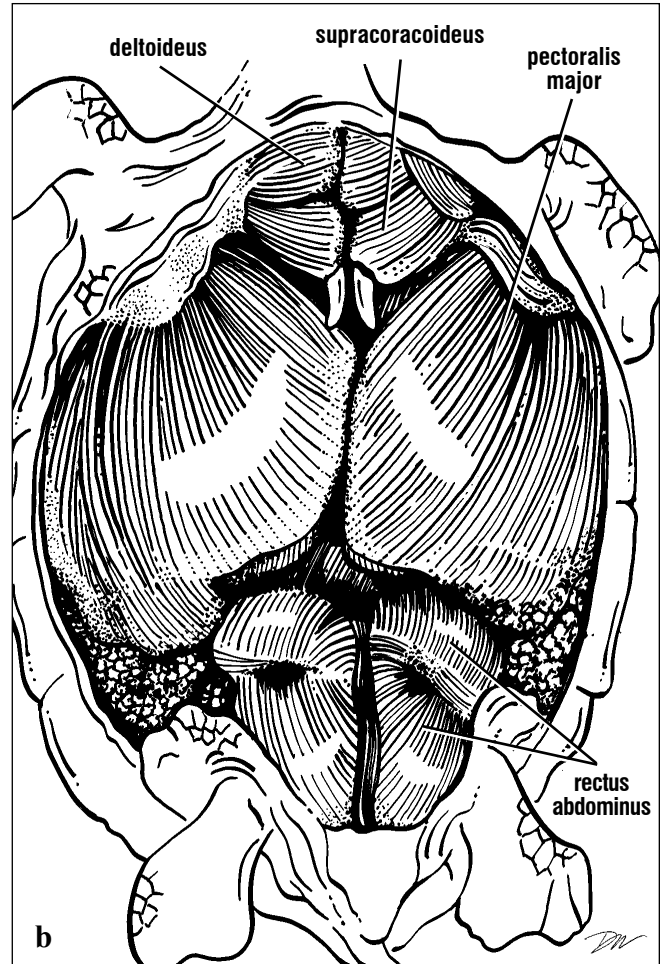
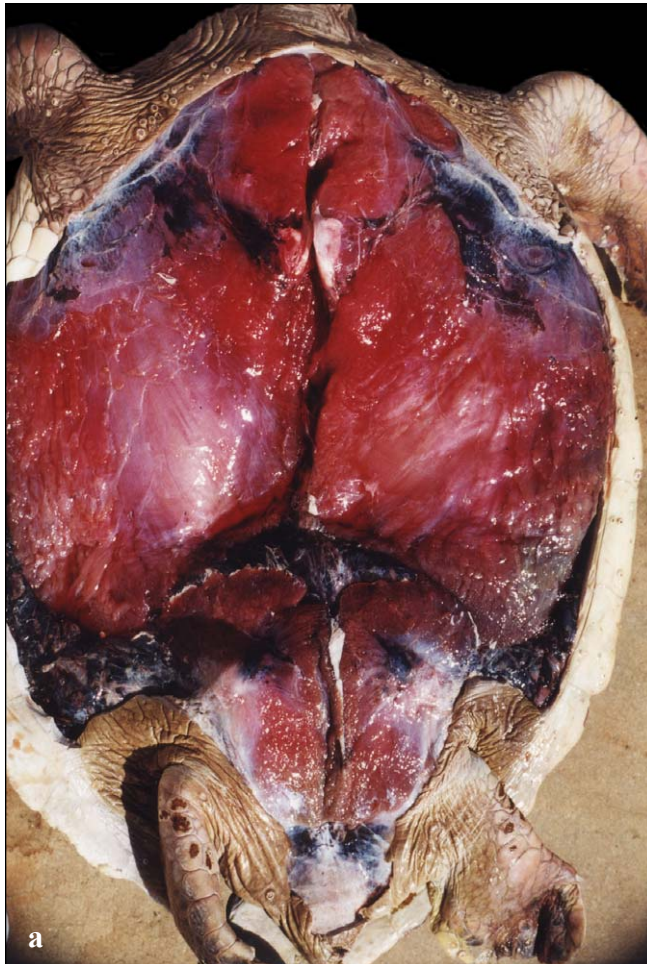Muscle functions are described with each figure. As they apply to sea turtles, these functions are as follows. **Flexion** bends one part relative to another at a joint; **extension** straightens those parts. **Protraction** moves one part (usually a limb) out and forward; **retraction** moves that part in and back. **Abduction** moves a part away from the ventral surface; **adduction** brings the part toward the body's ventral surface. **Rotation** turns a structure. **Depressor** muscles open (a special form of abduction) a structure, jaws in this case, while **levators** close jaws (a kind of adduction).

Muscle groups. The muscles described here are the major or large muscles (detailed discussion of most muscles can be found in the primary literature). For convenience, muscles are grouped by region; **axial** muscles, include the head muscles; **ventral** muscles include both proximal pectoral and pelvic muscles that are associated with the plastron; **forelimb** and **respiratory** muscles are those found on the flippers, carapace, and scapula involved in flipper movements and breathing. **Posterior** muscles are the large muscles of the hip, thigh, and lower leg. Muscles of the flipper blade and hind foot are not discussed or illustrated in detail here because they are obscured by extensive connective tissue and are difficult for most to identify, even with special dissection equipment and techniques.

Ventral Muscles. The massive ventral musculature is found after removing the plastron (Fig. 111). This musculature is dominated by a superficial muscle, the **pectoralis major**, which originates on the plastron and inserts on the lateral process and shaft of the humerus. Anterior to the pectoralis and ventral to the acromion processes are two muscles: the **deltoideus** (ventral part), which originates on the ventral scapula, acromion, and anterior plastron bones and the **supracoracoideus**, which has several subdivisions. Its anterior part originates on the acromion (Figs. 112-114). Both the deltoideus and the anterior part of the supracoracoideus insert on the lateral process of the humerus. These 3 ventral muscles function in swimming and respiration (by movement of the shoulders and plastron). Their innervations are via the supracoracoid nerve from the ventral portion of the **brachial plexus** (see Nervous System, Figs. 204-206).

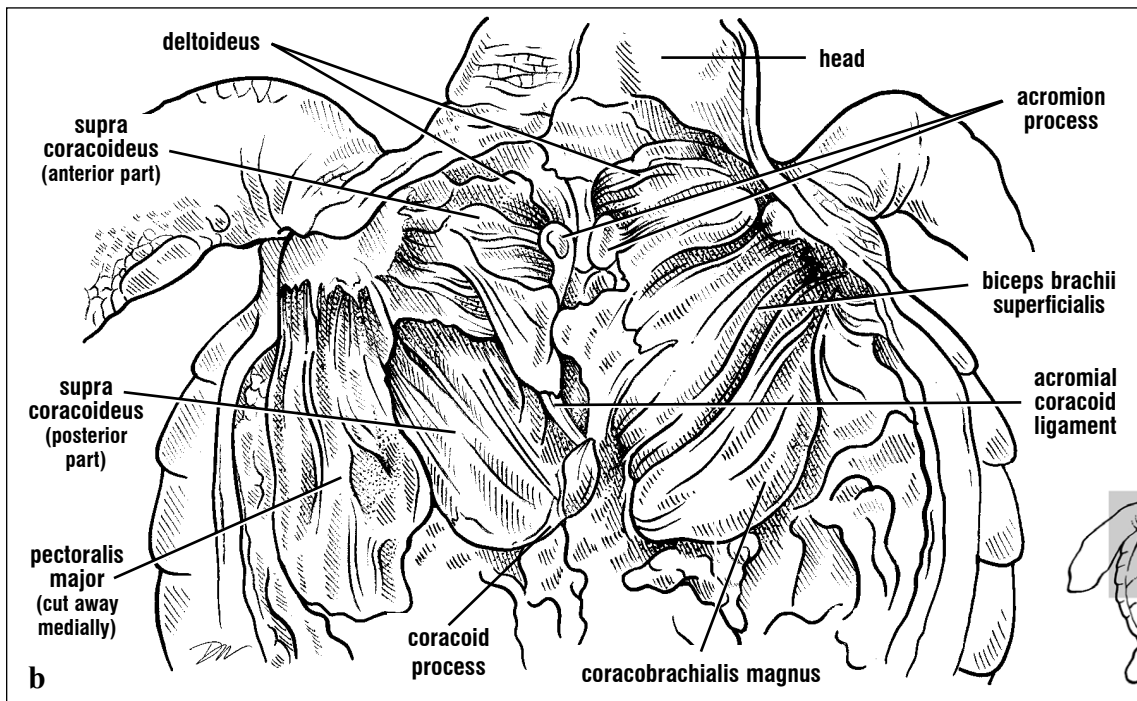
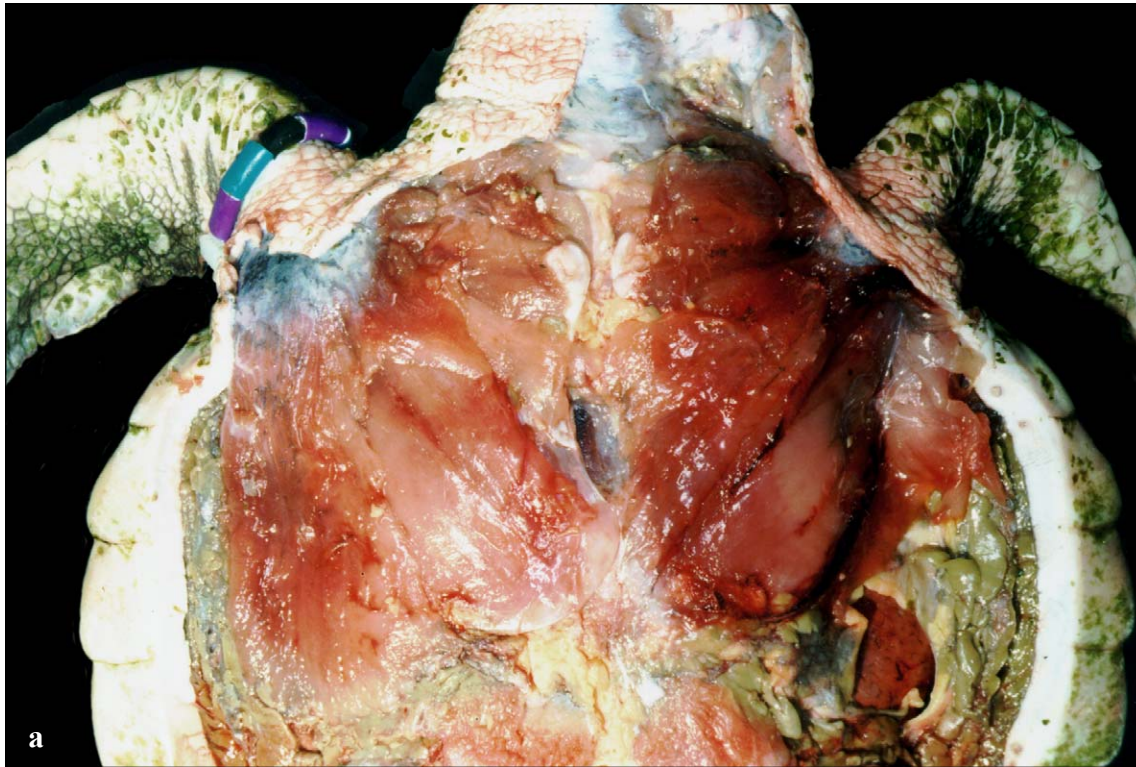
After removing the pectoralis major, deep locomotor muscles are found associated with the pectoral girdle (Figs. 112-114). The **biceps brachii** has several subdivisions, or heads, in sea turtles. The superficial head (Figs. 112-114) originates on the coracoid and extends via a long tendon to insert on the radius and ulna; the profundus head inserts on the humerus and radius. Innervation is via the inferior brachial flexor and median nerves. The **coracobrachialis magnus** originates on the dorsal side of coracoid process and inserts on the medial process of the humerus. The posterior part of the **supracoracoideus** (Fig. 112) originates on the coracoid and its cartilage and inserts in the lateral process of the humerus. These muscles are innervated by the supracoracoid nerve. There is an extensive series of arteries and veins running within and between these very active muscles (Fig. 114).

A pair of superficial posterior muscles, the left and right **rectus abdominis** (Fig. 111) are found ventrally. Each originates on the lateral pubis and inserts on the plastron. They stabilize the pelvis and may function in compressing the plastron during breathing.



Figs. 111a and 111b. Superficial ventral muscles of the pectoral and pelvic girdles. The large pectoralis major is a forelimb retractor and adductor. Both the deltoideus and the supracoracoideus protract

and abduct the humerus. The rectus abdominus is a pelvic stabilizer. Anterior is toward the top of the picture.



Figs. 112a and 112b. The deep pectoral muscles are exposed after removal of the pectoralis major. These forelimb retractors, separated on the animal's left (right in picture), are the biceps brachii superficialis and coracobrachialis magnus. The posterior part of the supracoracoideus both adducts and retracts the flipper.

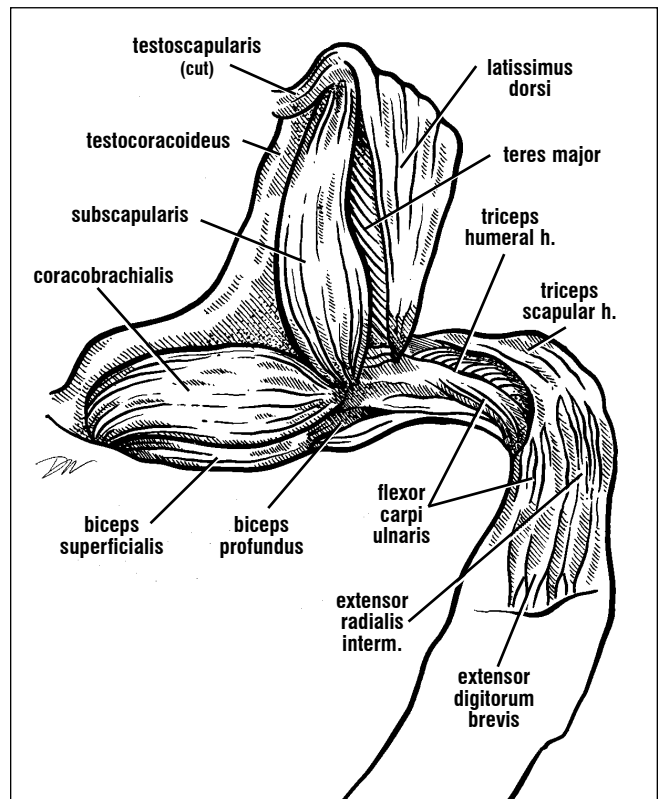
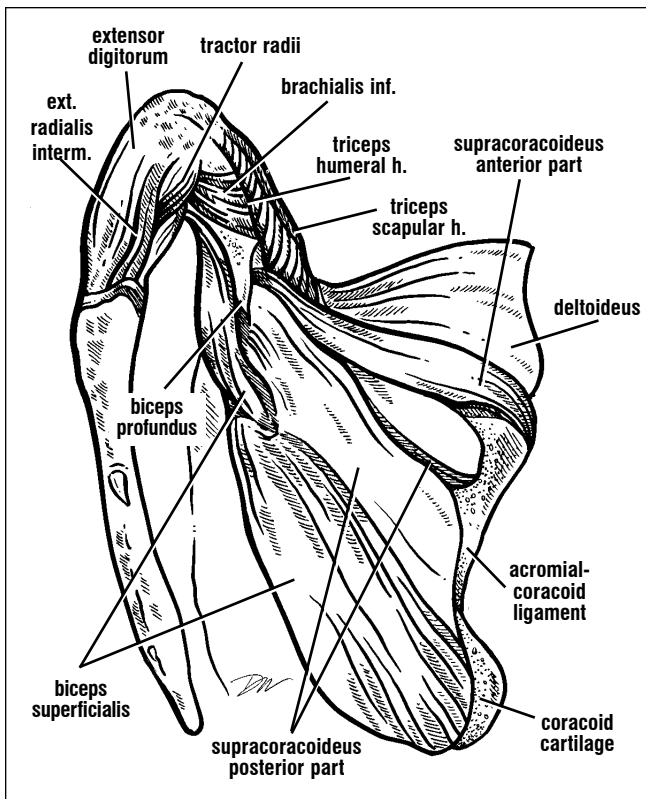
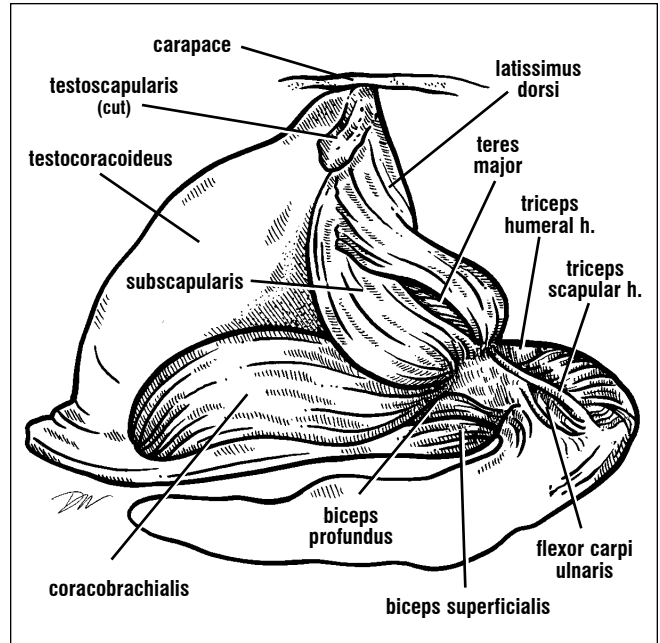
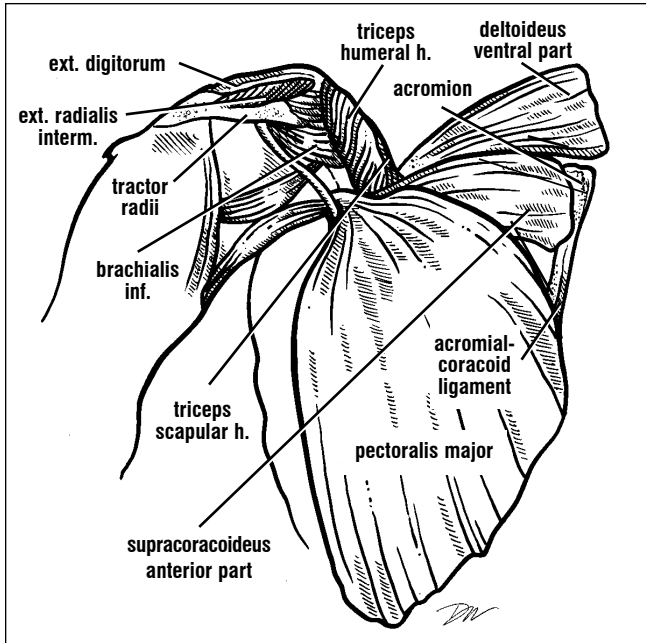
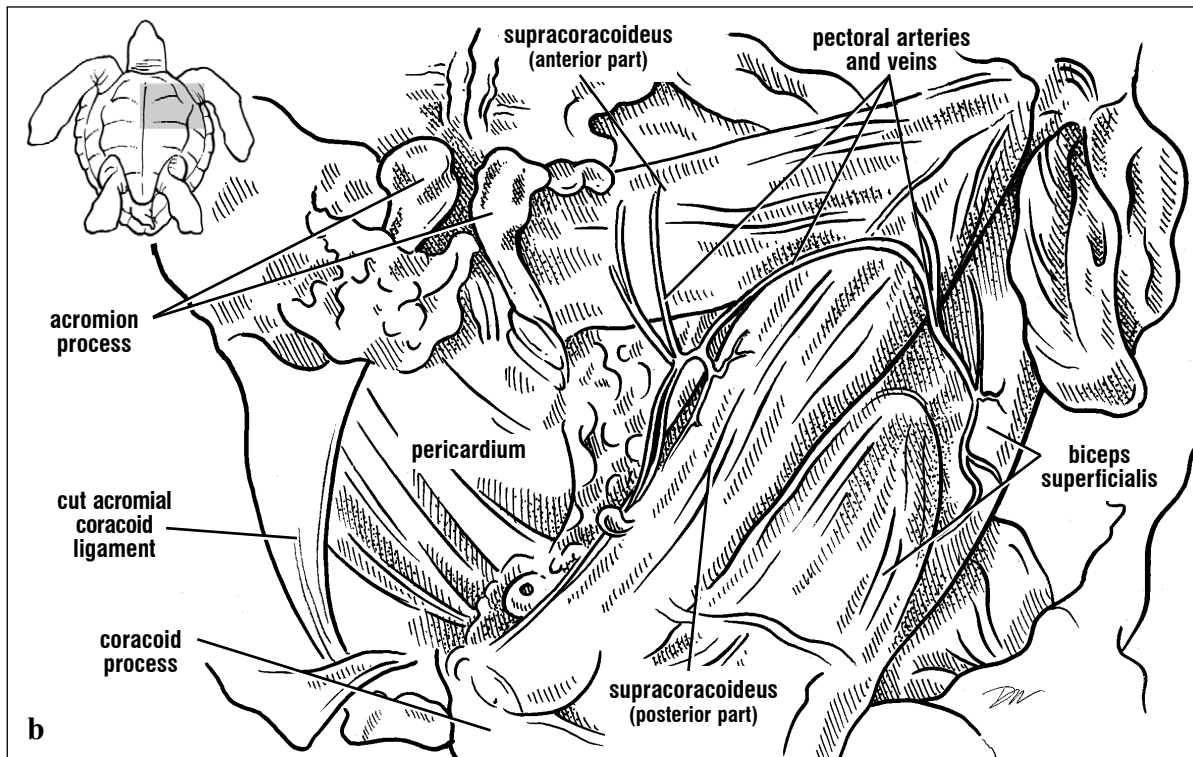
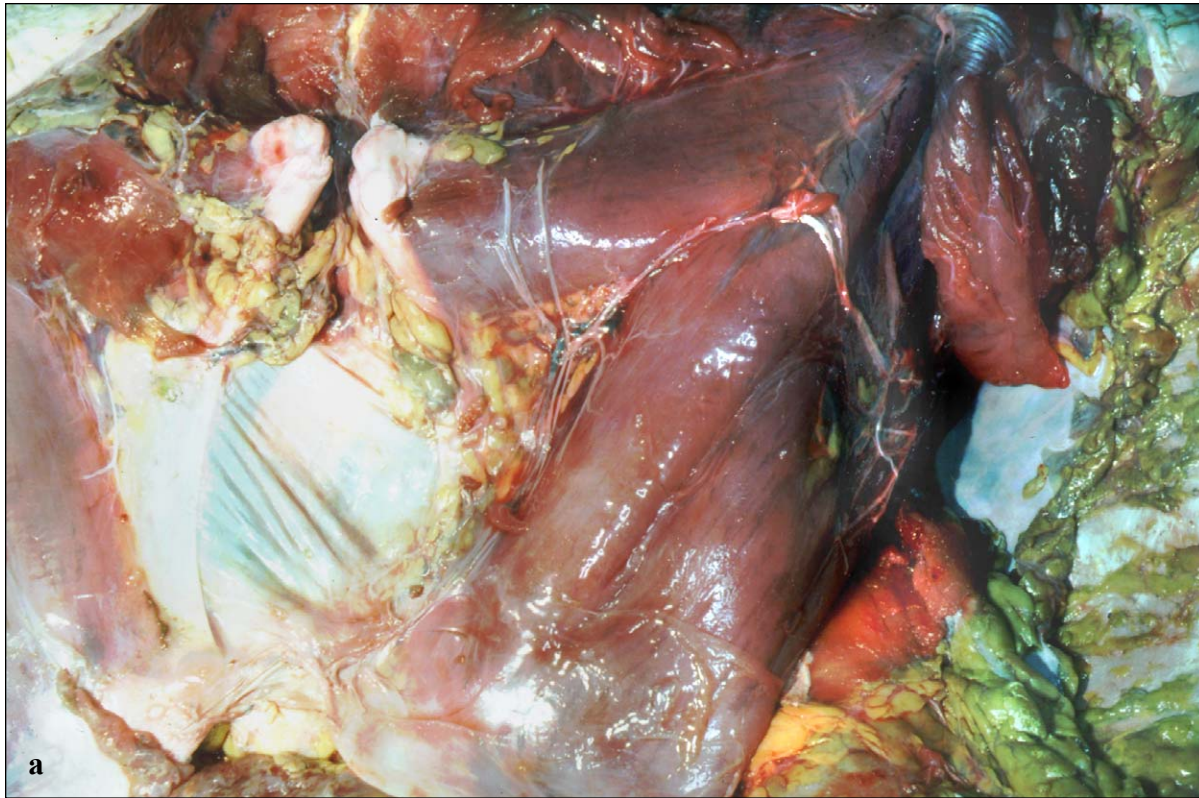


Fig. 113. Diagrams of cheloniid right shoulder muscles including locomotor and respiratory muscles. Superficial ventral muscles (top left), deep ventral muscles (bottom left), posterior muscles (bottom right), and lateral muscles (top

right). The extensor digitorum, extensor radialis intermedius, tractor radii, and flexor carpi all control the extension and flexion of the flipper blade. Ext.= extensor, h.= head, Inf.= inferior, Interm.= intermedialis. (After Wyneken, 1988)



Figs. 114a and 114b. The deep pectoral muscles of the animal's right side are shown in detail. The supracoracoideus has two parts: posterior, which protracts and anterior, which retracts the forelimb.

Forelimb and Respiratory Muscles. The **latissimus dorsi/teres major complex**, the scapular head of the **deltoideus**, and the **subscapularis** originate on the carapace and/or shoulder girdle and insert on the proximal humerus (Fig. 113). The latissimus dorsi and teres major together originate on the scapula and the carapace from the attachment point of the scapula, along the first pleural bone to the anterior peripheral bones. They insert via a common tendon just distal to the head of the humerus. The scapular head of the deltoideus arises from the anterior scapula and inserts on the lateral process and shaft of the humerus. The subscapularis muscle is very large, originates on the medial and posterior scapula, and inserts on the large medial

process and the shaft of the humerus. These muscles are innervated by the deltoid nerve (a branch of the brachial plexus).

There are two sheet-like respiratory muscles located dorsally, which are often destroyed when removing the pectoral girdles (Figs. 113 and 115). These are the **testocoracoideus** (origin: carapace near the anterior inframarginals; insertion: dorsal coracoid) and **testoscapularis** (origin: carapace posterior to the latissimus dorsi; insertion: dorsal scapula and the scapular attachment to the carapace). They are innervated by cervical spinal nerves.

The remaining dorsal shoulder muscle, the **triceps brachii** (= triceps superficialis) has two heads in cheloniid sea turtles (Figs. 113-116). The humeral head arises from the humerus, and the scapular head arises from the scapula. Both converge to form a common tendon inserting on the proximal ulna. This muscle may have only a humeral head in *Dermochelys*. The triceps is innervated by the superficial radial nerve (a branch from the superior brachial nerve of the brachial plexus).

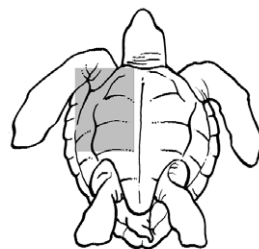
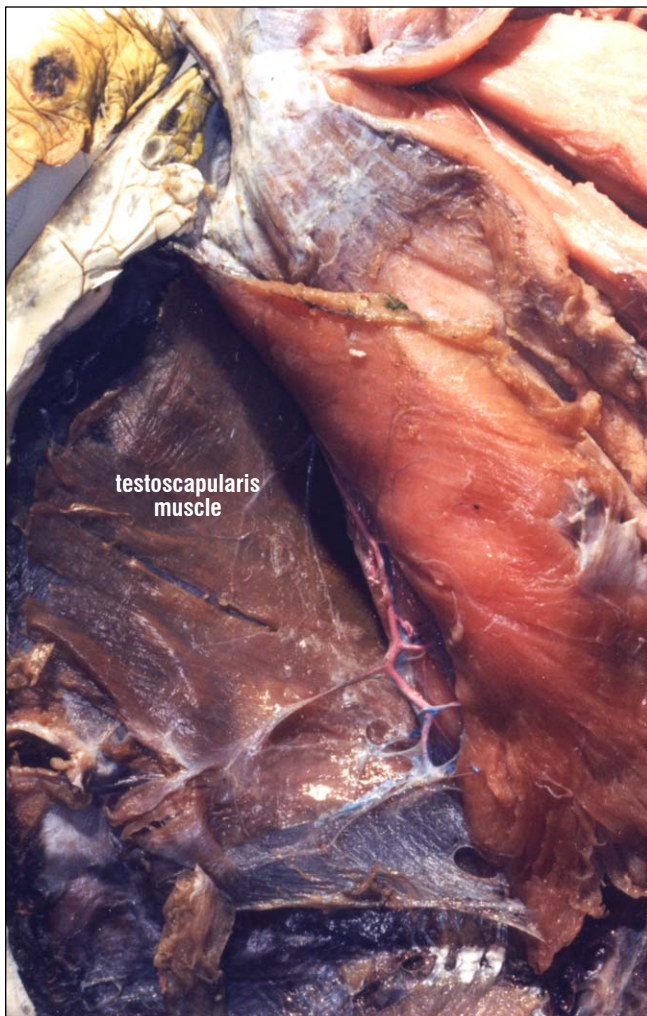


Fig. 115. Ventral pectoral muscles with arteries and veins. The pectoral artery is found running along the deep muscles of the shoulder. The testoscapularis, a respiratory muscle, is deep to the pectoralis. Other pectoral muscles originating on the coracoid are reflected medially (to the right) in this picture.

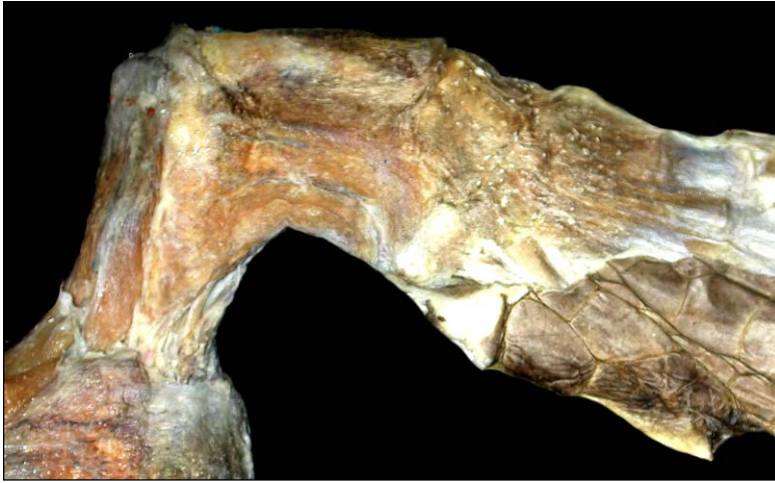

Fig. 116. Superficial dorsal forelimb muscles (right). The two heads of the triceps brachii, (triceps scapular head and triceps humeral head) are forelimb adductors, which twist the flipper. The more medial biceps and flexor carpi ulnaris muscles flex the flipper blade. The extensor digitorum muscle becomes diffuse in adults as fibrous connective tissue stiffens the flipper blade. Young turtles can extend the digits, somewhat mature turtles cannot.

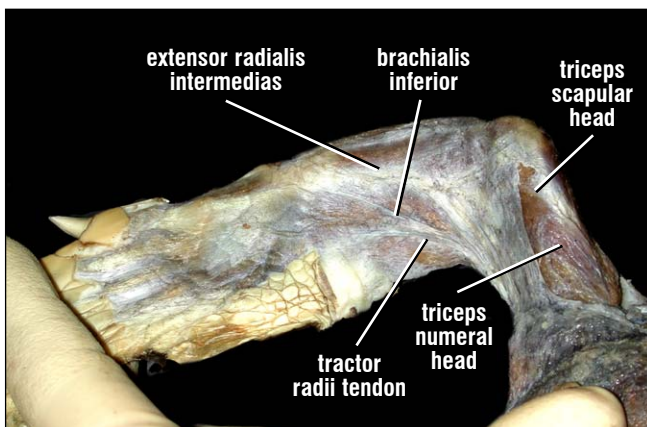
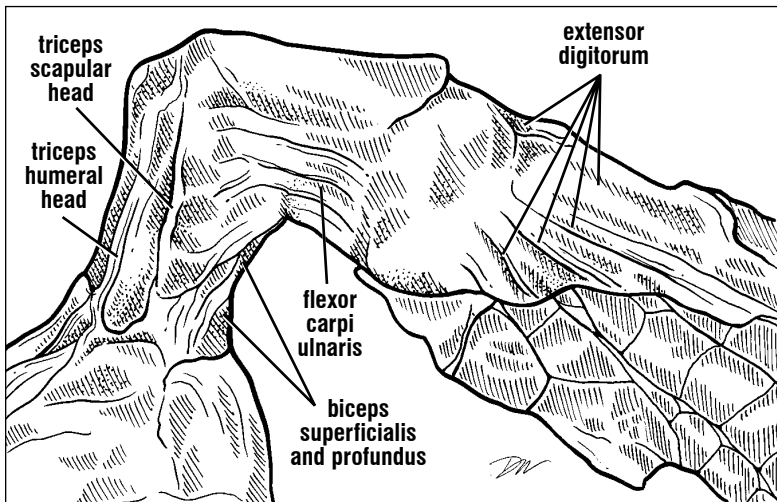


Fig. 117. Ventral forelimb muscles (right). Most of the ventral muscles flex the flipper blade relative to the upper arm. The extensor radialis extends the flipper. The scapular head of the triceps may twist the flipper blade along its axis, or abduct the forearm.

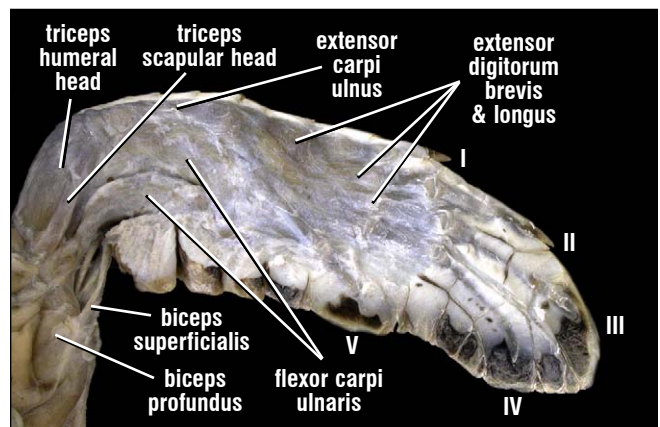
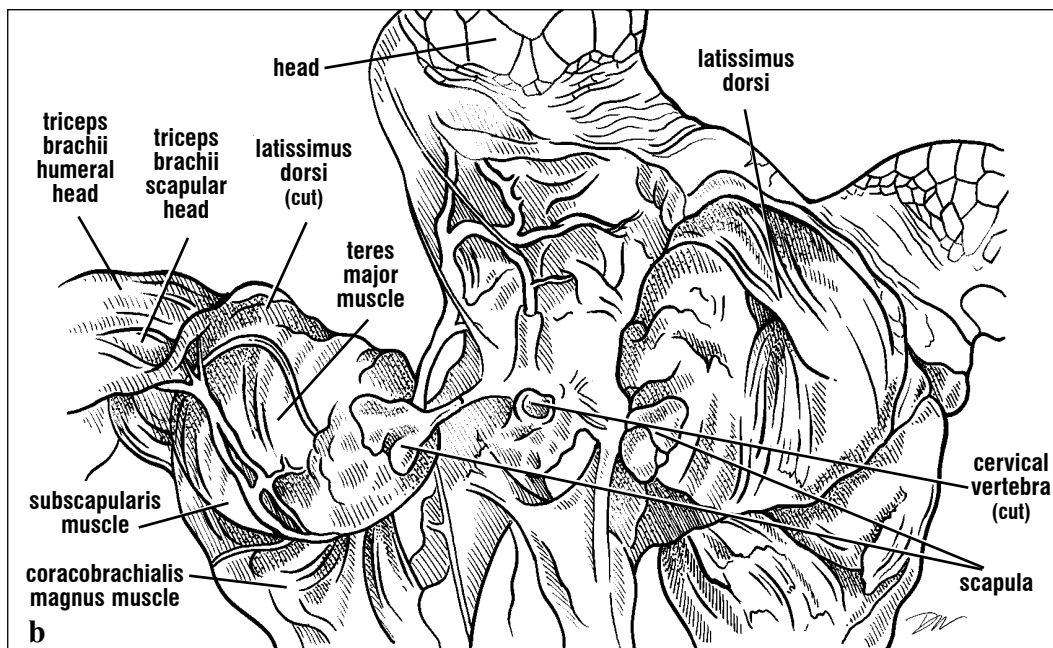
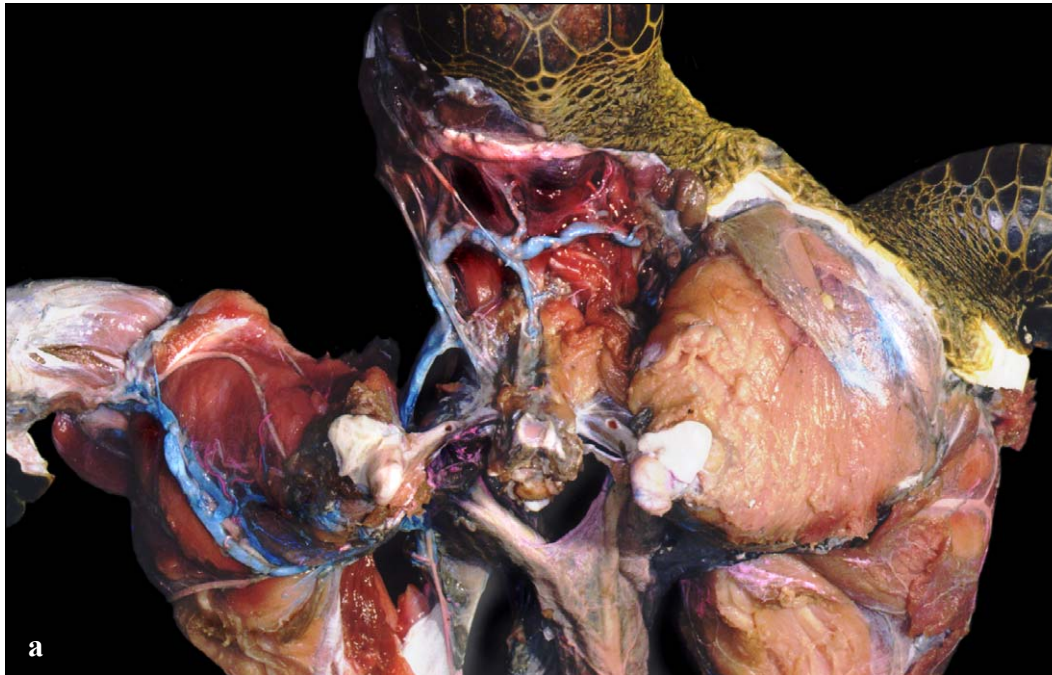


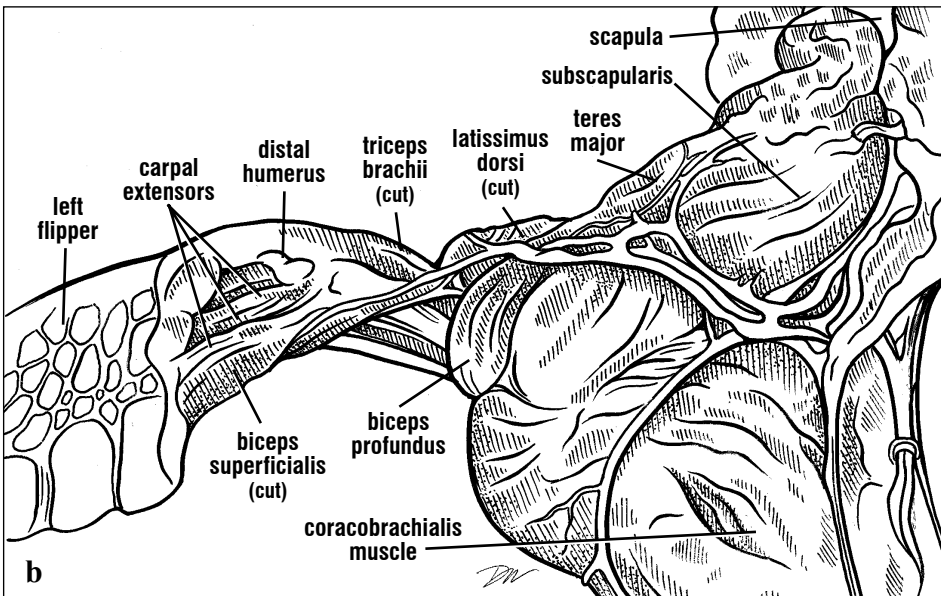
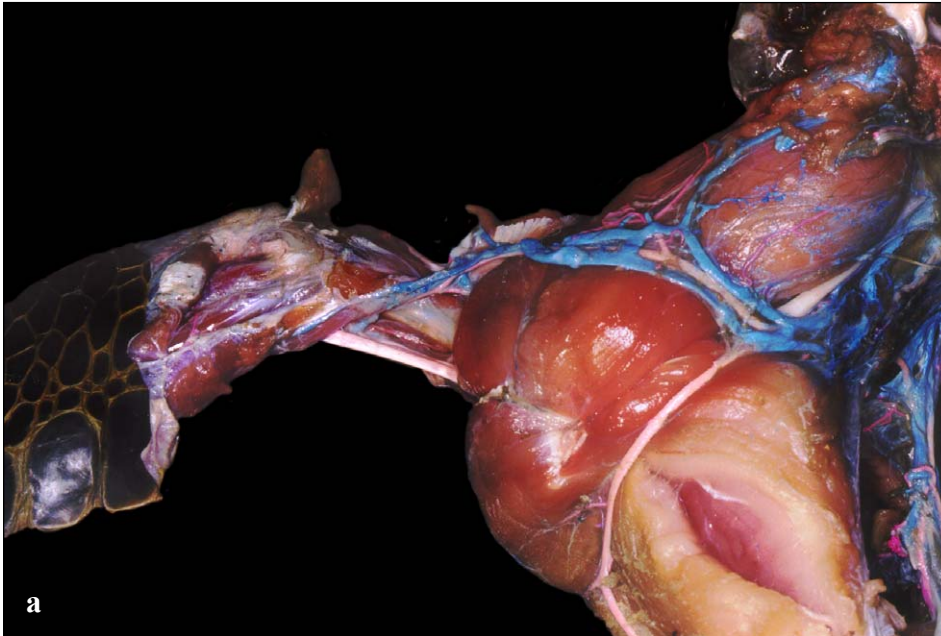
Fig. 118. Dorsal forelimb muscles of an immature hawksbill. In young animals, the muscle divisions of the forearm and the flipper, particularly, are more obvious than in older animals. Less connective tissue is present and the digits can flex and extend to a limited extent.



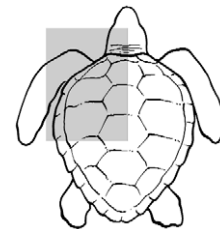
Figs. 119a and 119b. Dorsal view of the pectoral musculature. The carapace, skin and fat have been removed (from left). The head, cut cervical vertebra, and scapular ends provide landmarks for orientation. The latissimus dorsi, a large sheet-like muscle, is shown intact (animal's right) and cut (animal's left). It, plus the teres major and deltoideus (scapular head, not shown), abduct and sometimes protract the flipper. The large subscapularis is a strong flipper protractor. The coracobrachialis, a ventral muscle, is seen extending from the shoulder posteriorly, toward its origin, the coracoid.

The biceps muscle may have one or two parts (Figs. 112 and 114). When two heads are present, the **biceps superficialis** arises from the coracoid and inserts on the pisiform of the wrist. The muscle has two bellies in series, with a short tendon in the middle. The second and most prominent head, the

biceps profundus, also originates on the posterior coracoid, but ventral to the biceps superficialis and inserts via a tendon with the **brachialis** on the ulna (Fig. 114). In *Dermochelys* and *Lepidochelys*, often there is just a single head inserting on the radius and ulna.



Figs. 120a and 120b. *The pectoral muscles of the left shoulder, arm and flipper. The large subscapularis covers most of the scapula. The large coracobrachialis is seen ventrally, covering much of the coracoid. The biceps muscle has one or two heads (varying among species and among individuals). The biceps superficialis extends from the shoulder (mostly the coracoid) to the pisiform bone of the wrist, and probably helps control the twist or rotation of the flipper blade. The biceps profundus (seen only as a partial separation here) acts as a flipper retractor and a flexor of the flipper blade at the elbow.*



Axial Muscles. Most axial muscles are associated with the neck and tail of sea turtles. The majority of the neck muscles are illustrated with the neck circulation (Figs. 131, 141, 143-153). These include the transverse cervical muscles, and the biventer cervical muscle. Here, the superficial muscles of the throat and the jaw muscles are described. The tail musculature is not discussed because it has not been studied in any detail.

The major deep muscles of the neck are the **longus colli** and **retrahens colli**. The longus colli muscles are short, segmentally arranged, and travel obliquely between successive cervical vertebrae; they serve to extend the neck. The retrahens colli originate on the cervical vertebrae and extend posteriorly to insert on the dorsal vertebral elements of the carapace. They are neck flexors and retractors, to the extent that marine turtles extend and retract the neck.

Head Muscles. Just beneath the skin of the throat is a thin layer of muscle, the **intermandibularis**,

which has fibers running between the two dentary bones. It inserts on a flat midline tendon (raphe) that runs the length of the throat (Fig. 121). The intermandibularis becomes the **constrictor colli** posterior to the jaw joint (Fig. 121), originating on a dorsolateral cervical tendon. Just deep to the intermandibularis are muscles running obliquely between the jaws and inserting on the hyoid, the **geniohyoideus**. Posterior to the geniohyoideus is a pair of strap-like muscles, the **coracohyoideus** that extend to the hyoid apparatus from the coracoid (Figs. 122-123). These muscles assist in depressing the jaw, swallowing, and pumping the throat (gular flutter). They are innervated by the facial nerve. Muscles of the tongue, innervated by the hypoglossal nerve, and the glossopharyngeal nerve are not described here.

The jaw muscles of turtles are mostly located inside the skull. Because of these deep positions, most are described but not illustrated. Unlike mammals, turtles lack a **mandibularis** muscle; instead they have an **adductor mandibulae** with several heads. The heads originate on the parietal, supraoccipital, quadrate, prootic, and opisthotic bones (Fig. 31) and converge on a tendon that inserts primarily on the lower jaw (dentary, with small insertions on the squamosal bone posterior to the jaw joint). Medial to the adductor mandibulae complex is a pair of connected muscles. The intermandibularis muscle runs from the lower jaw to the tendon of the **pseudotemporalis** muscle which itself continues to the parietal bone. These jaw closing muscles are all innervated by the **trigeminal nerve**. The jaws

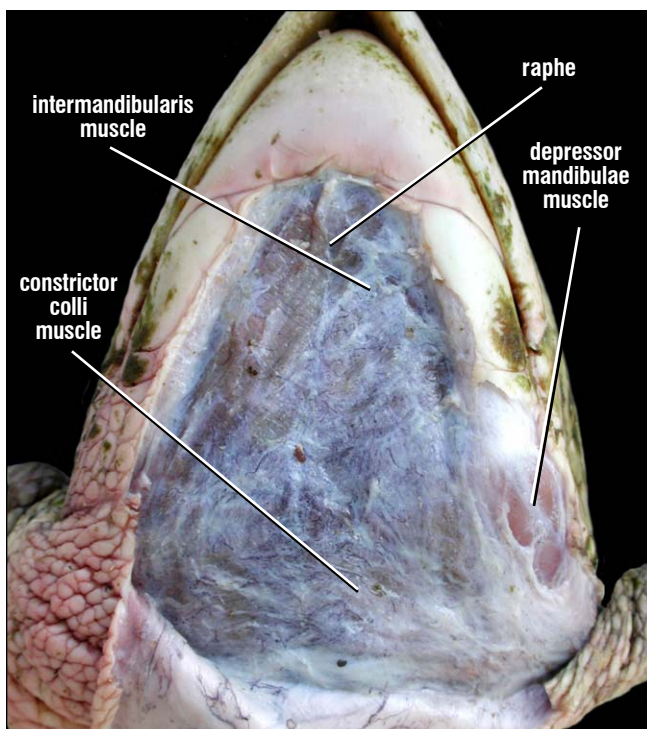
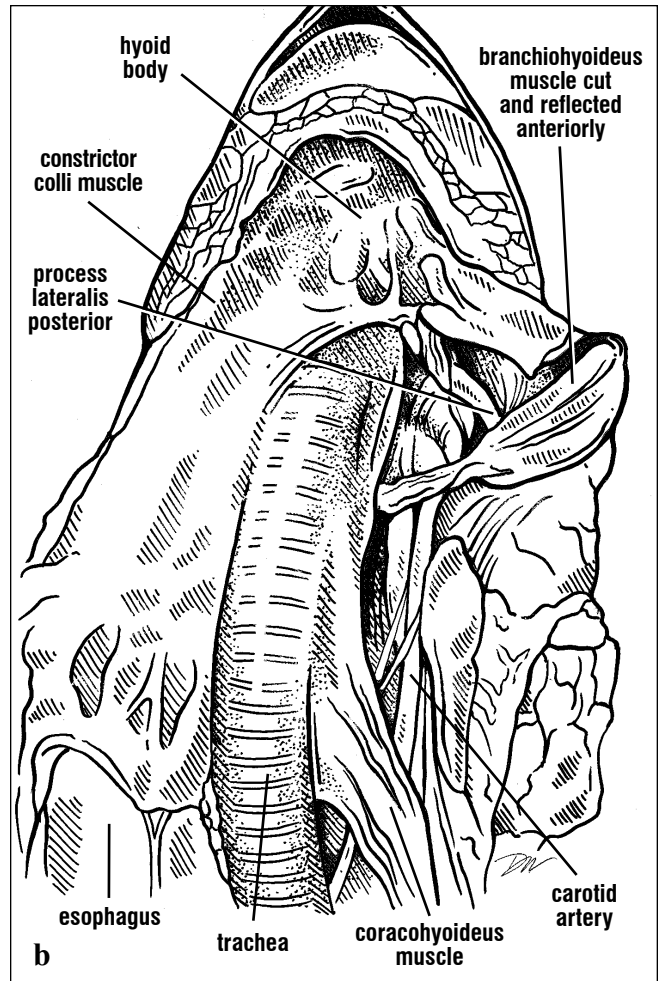
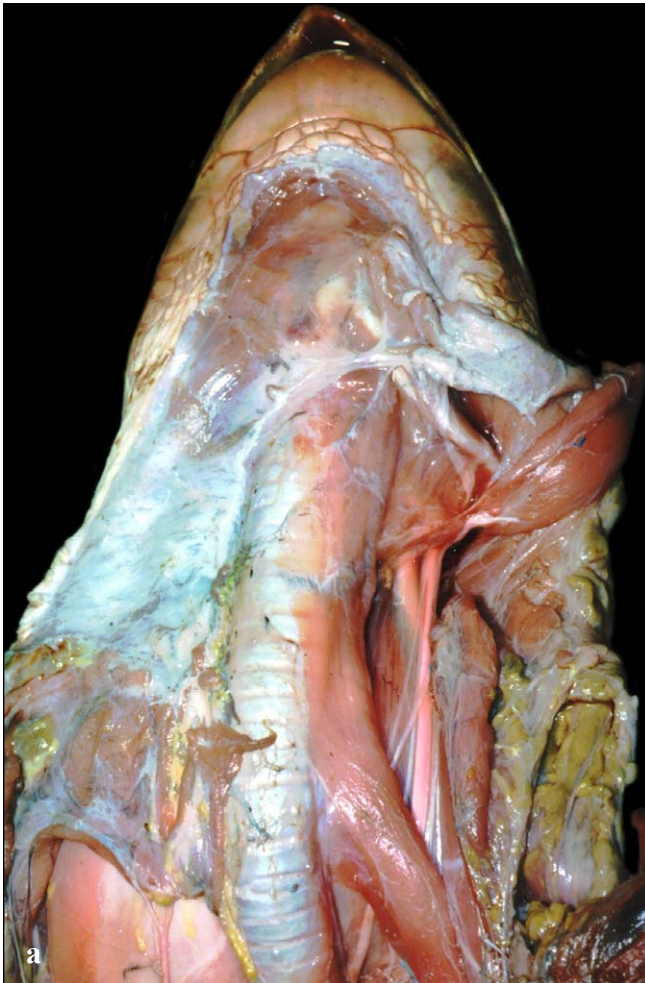


Fig. 121. *Ventral and superficial neck muscles. The constrictor colli muscle of the ventral neck is exposed lateral to and overlying the trachea. Connective tissue that loosely attached the muscle to the skin is still present on the turtle's anterior neck. The midline raphe (tendon) is visible along the anterior half of the muscle.*

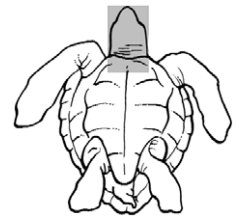
MUSCLE ANATOMY

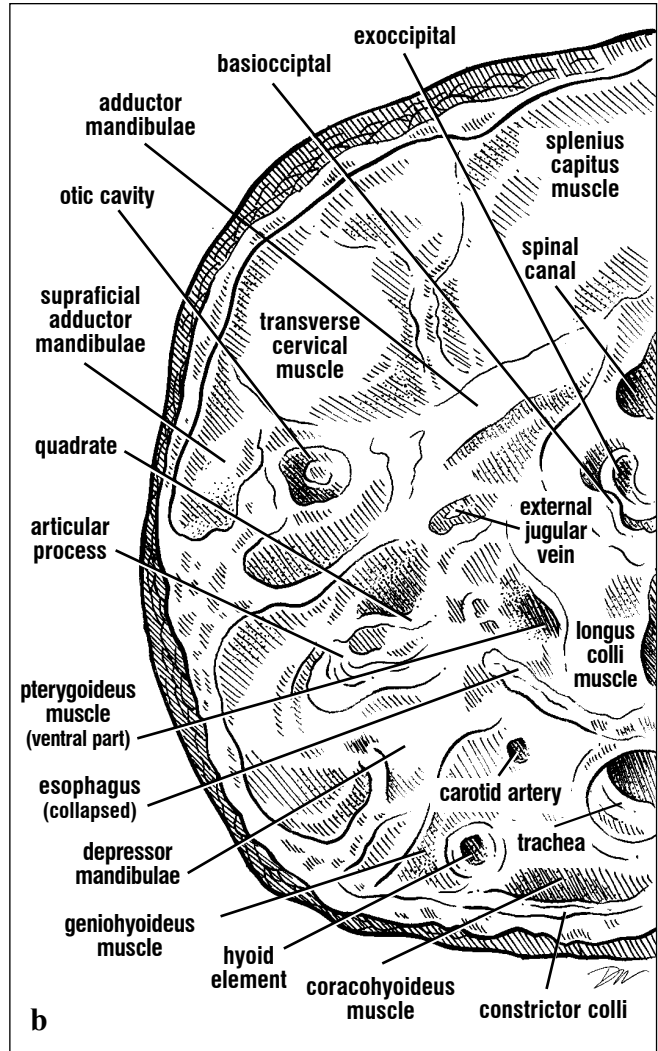
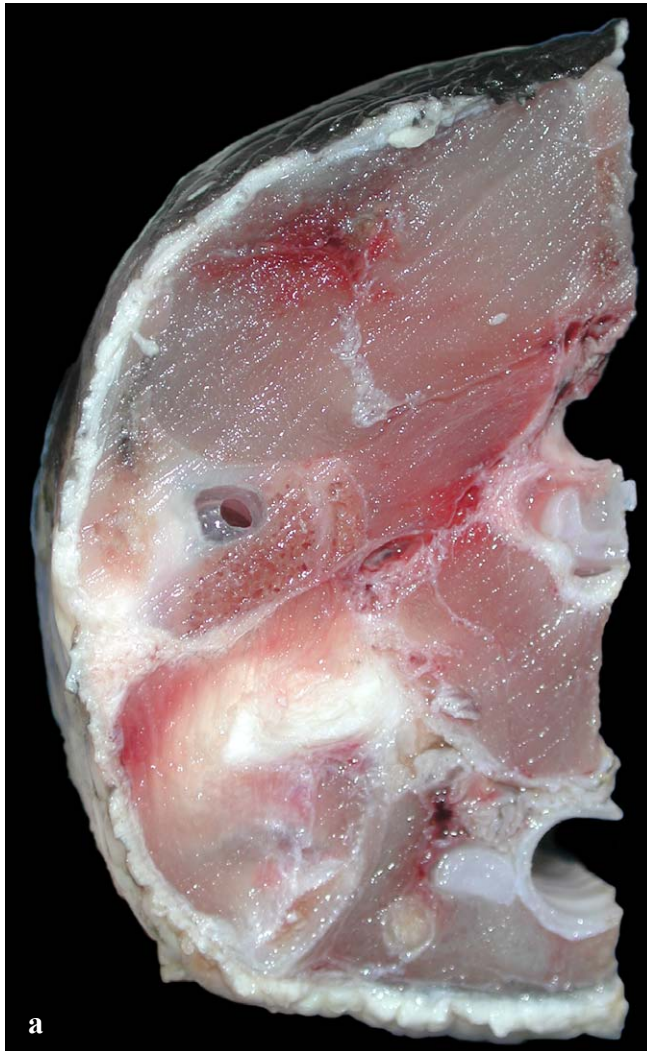are opened by the **depressor mandibulae** muscle, which has several parts. The depressor mandibulae arises from the quadrate, quadratojugal, and squamosal bones and inserts on the articular of the

lower jaw; in *Dermochelys* a portion also inserts on the auditory tube. These parts are innervated by the facial nerve.

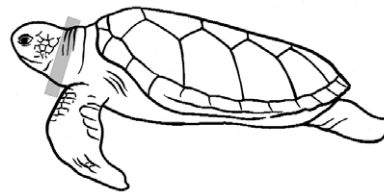


Figs. 122a and 122b. Dissection of the ventral neck muscles, showing the deep muscles (right in picture) and superficial muscles (left). The parallel fibers of the intermandibularis arise from the lower jaw, and terminate in the cut raphe (found overlying the hyoid body and anterior trachea). The branchiohyoideus is cut between the hyoid body and the hyoid process (process lateralis posterior) on the turtle's left. The coracohyoideus travels along the trachea to the hyoid. The carotid artery lies deep to these muscles.





Figs. 123a and 123b. This oblique axial section through the neck of a hawksbill, is just posterior to the jaw joint ventrally and supraoccipital crest dorsally. The muscles, major blood vessels, trachea, and esophagus can be identified. Their relative positions and extent are seen in this dissection.



Posterior Muscles. The major posterior muscles can be identified after removing the rectus abdominus and the skin covering the hind legs and tail. Ventrally, these are the **puboischiofemorales externus** and **internus**, the **pubotibialis**, the **flexor tibialis** complex and the **ambiens** (Figs. 125-126; see also Nervous System). These ventral hip muscles are innervated by the obturator and tibial nerves of the sacral (=lumbosacral) plexus. The puboischiofemorales externus, a thigh adductor, covers much of the ventral pelvis, and arises from the ventral pubis, ischium, and membrane covering the thyroid fenestrae (Fig. 106); it inserts on the femur's minor trochanter. Different parts of this muscle can either protract or retract the leg. The puboischiofemorales internus is large in cheloniids and has both superficial and deep components. It may be absent in *Dermochelys* and replaced in function and position by the **iliofemorales**. When present, it originates on the dorsolateral pubis, ilium, and the sacral vertebrae. It inserts on the femur's major trochanter.

The **pubotibialis**, part of the flexor tibialis complex, is found in cheloniids but is absent in *Dermochelys*. This muscle originates on the pubic symphysis and lateral pubis; it inserts on the tibia with the **flexor tibialis internus**. The flexor tibialis internus, a Y-shaped muscle, originates on the sacral and postsacral vertebrae dorsally, and ventrally on the pelvic symphysis and lateral pubis. It passes distally and wraps around the **gastrocnemius** muscle to insert on the tibia. The **flexor tibialis externus** has two heads (Figs. 125-126) and is somewhat medial to the internus. The dorsal head arises from the ilium and the ventral head from the posterior ischium. Both converge to insert, via a single tendon, on the tibia and the gastrocnemius muscle of the shank; some fibers insert on the skin and connective tissues of the shank.

The **adductor femoris** (Fig. 126) originates on the lateral ischium and inserts on the posterior femoral shaft. The **ischiotrochantericus** (not shown), a leg retractor, originates on the anterior pubis and pubic symphysis. It inserts on the major trochanter of the

femur. The dorsal hip and thigh muscles (illustrated in Circulatory Anatomy; Figs. 156-157 and Nervous System; Fig. 207), include the hip abductors: **iliotibialis**, **femorotibialis**, and **ambiens**. The ventrally positioned ambiens (Fig. 125) originates on the puboischial ligament, and inserts on the "patellar" tendon across the knee to the anterior tibia. The **iliotibialis** originates on the dorsal ilium and inserts with the ambiens on the patellar tendon. Deep to these two muscles, the **femorotibialis** (see Nervous System, Fig. 207), arises from the dorsal and anteroventral surfaces of the femur, and inserts with the iliotibialis and ambiens. The **peroneal** and **femoral** nerves of the **sacral plexus** innervate most of these dorsal hip muscles.

The hind foot extensors (Fig. 124) are large sheet-like muscles originating on the dorsal and lateral femur and inserting on the dorsal and anterior fibula and digits. They flex the lower leg or extend the digits.

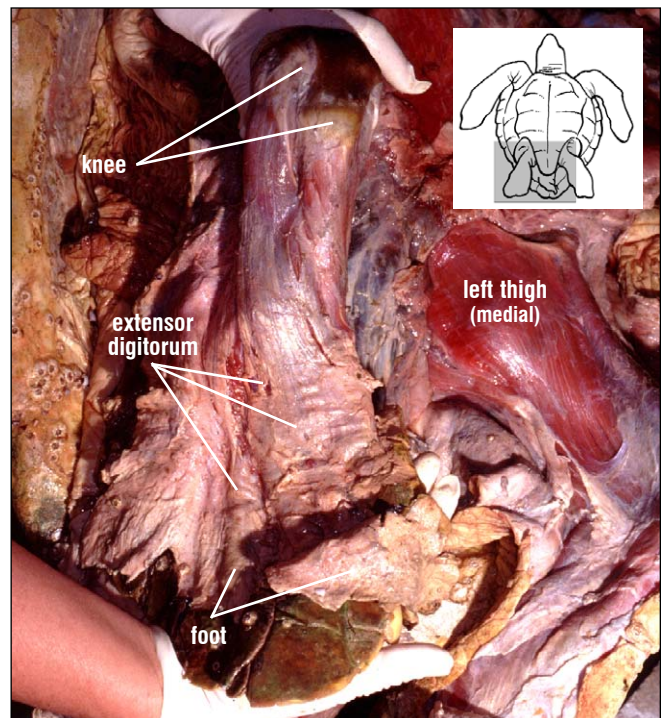
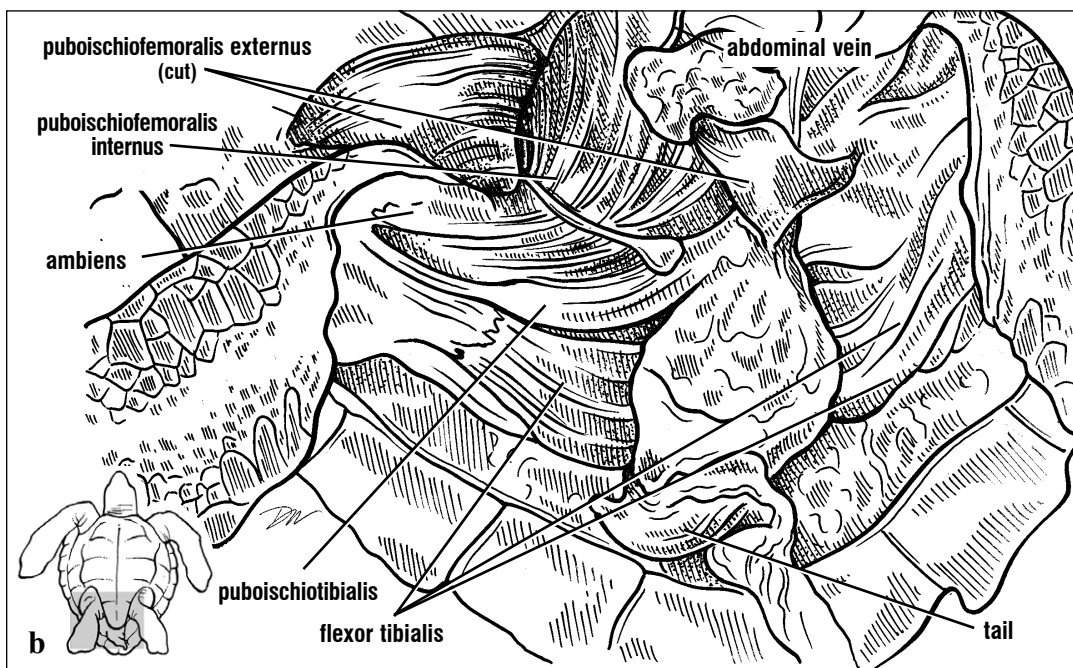
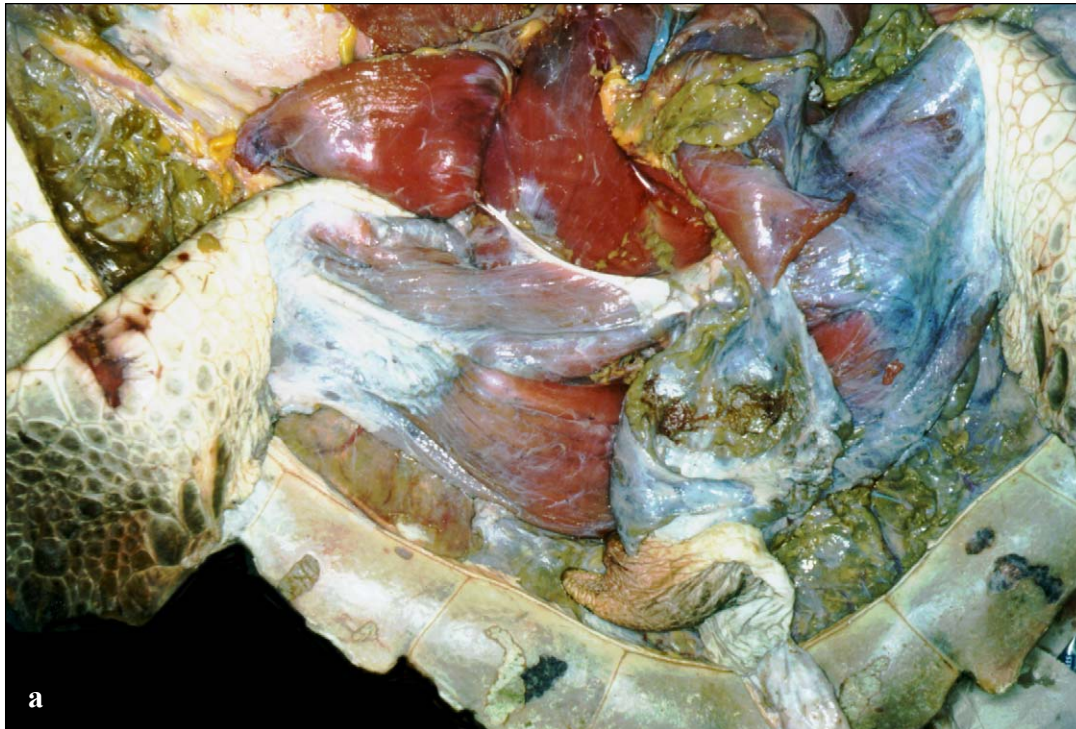
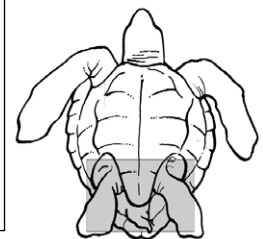
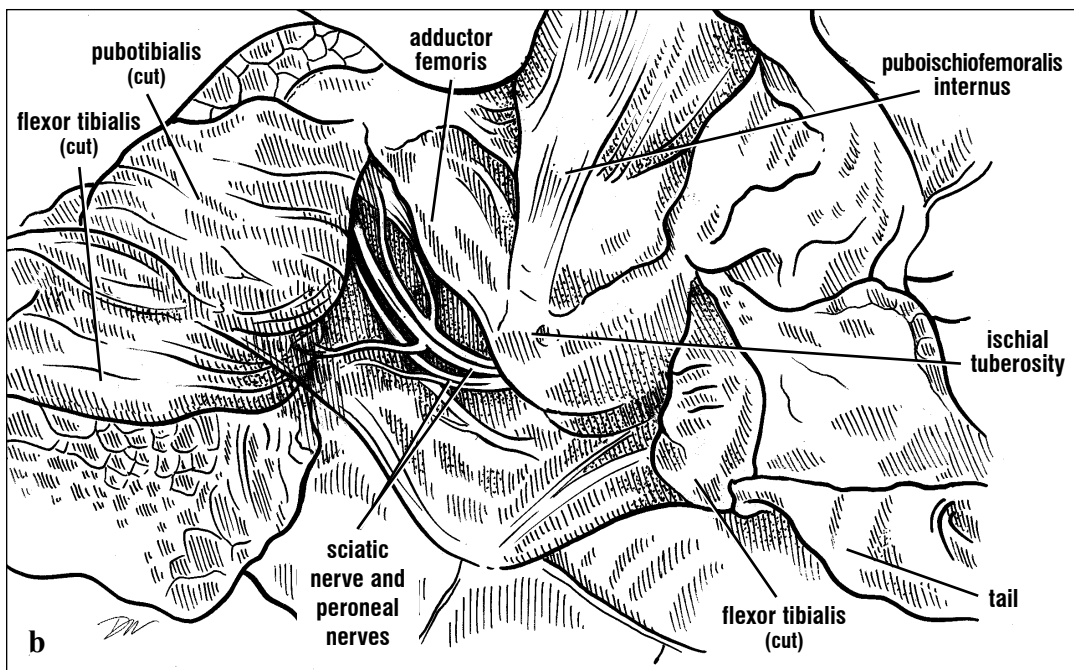
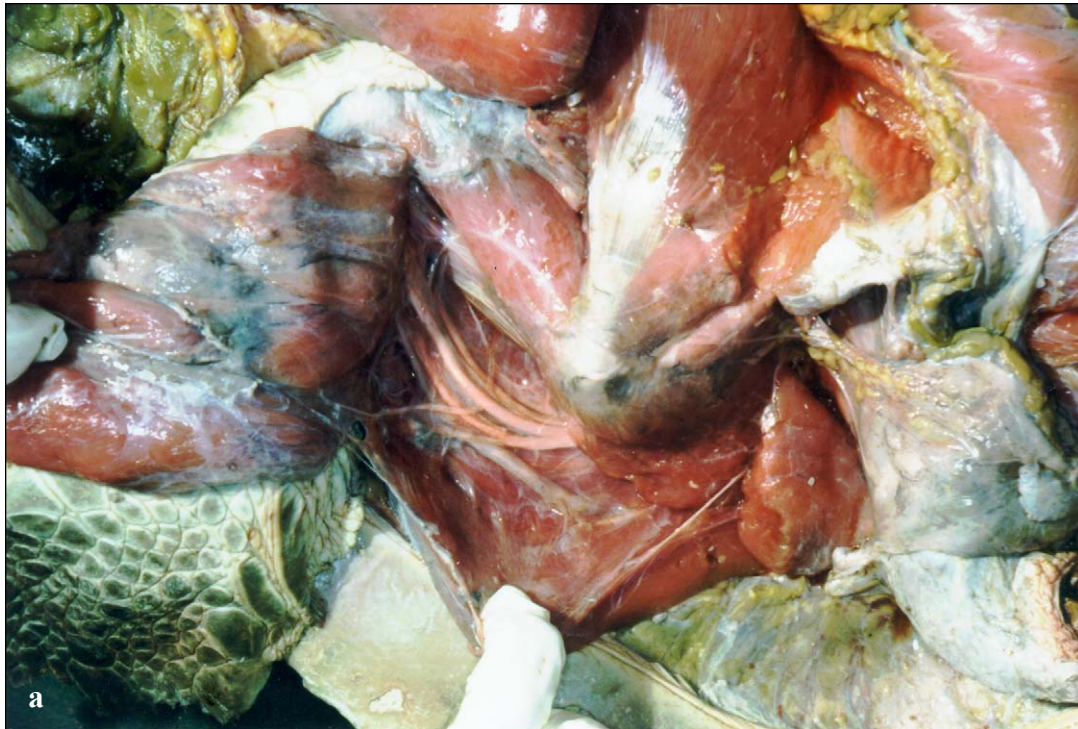

Fig. 124. Anterior and dorsal foot extensors of a loggerhead right hind limb. The leg is abducted and flexed at the knee. The foot extensors flex the lower leg or extend and spread the digits.



Figs. 125a and 125b. *The superficial ventral hip muscles. The puboischiofemoralis externus is an adductor of the leg. The puboischiofemoralis internus (the anterior ventral portion is seen here) is a protractor and abductor of the leg. The flexor tibialis complex, including the pubotibialis, flexes and retracts the leg and controls the shape of the trailing edge of the foot, perhaps during steering. More anteriorly, the ambiens is a weak adductor and protractor of the hind leg and can extend the shank.*



Figs. 126a and 126b. The deeper ventral hip muscles are shown after removing the superficial limb retractors. The adductor femoris and puboischiofemorales internus are antagonistic muscles, with the former adducting the thigh and the later abducting it.

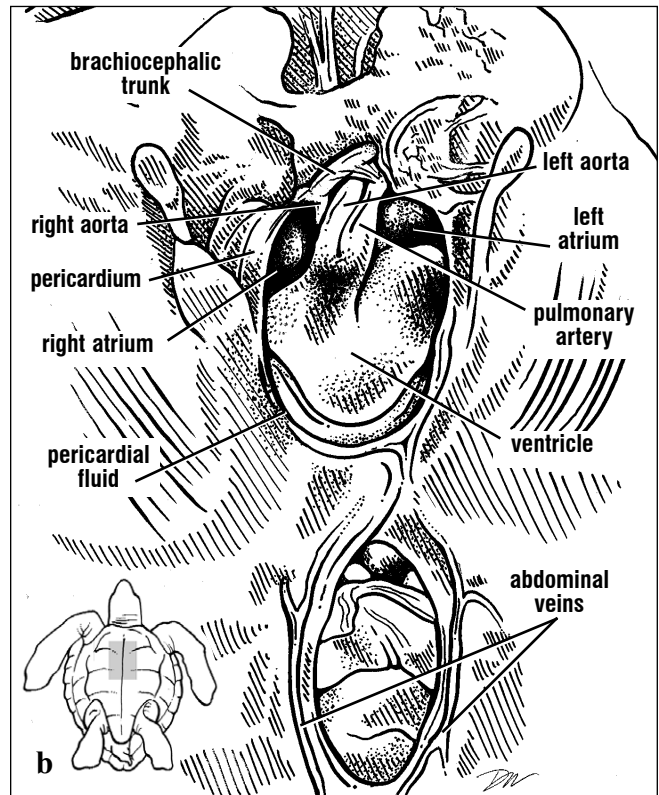
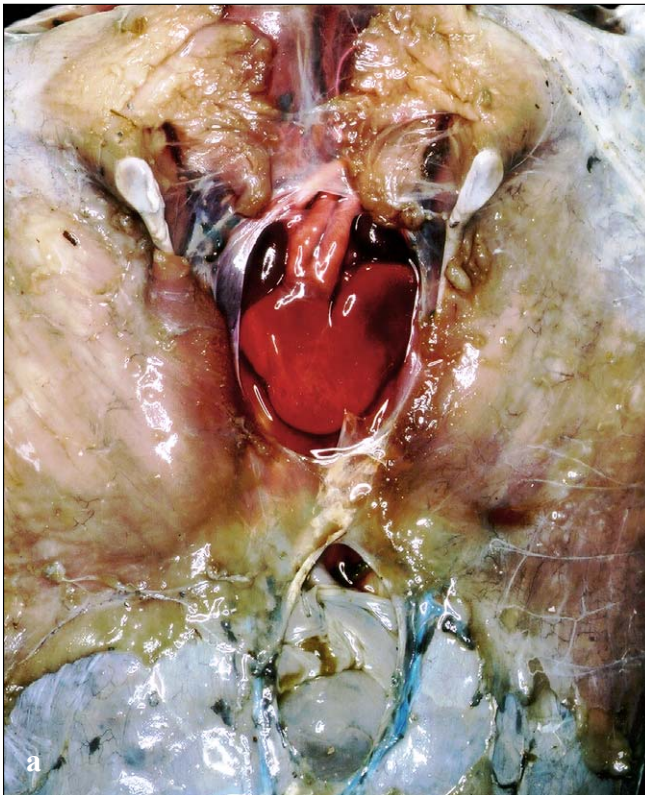
Circulatory Anatomy

The circulatory anatomy includes the heart, arteries, veins, and lymphatic vessels. The heart is multichambered and serves as the main pump. Arteries have thick walls of muscles and elastic fibers; they carry blood away from the heart. Veins carry blood to the heart; they have thinner layers of muscle and elastic tissues and tend to collapse in dead animals. Most veins contain valves. The lymphatic vessels transport tissue fluid from outside the circulatory system back to the blood. The lymphatic vessels are very thin walled and difficult to photograph. They surround the arteries and veins like sheaths.

Heart. The heart is located within the pericardium and bordered ventrally by the acromion and coracoid processes (Figs. 127-129). Dorsally it is bordered by

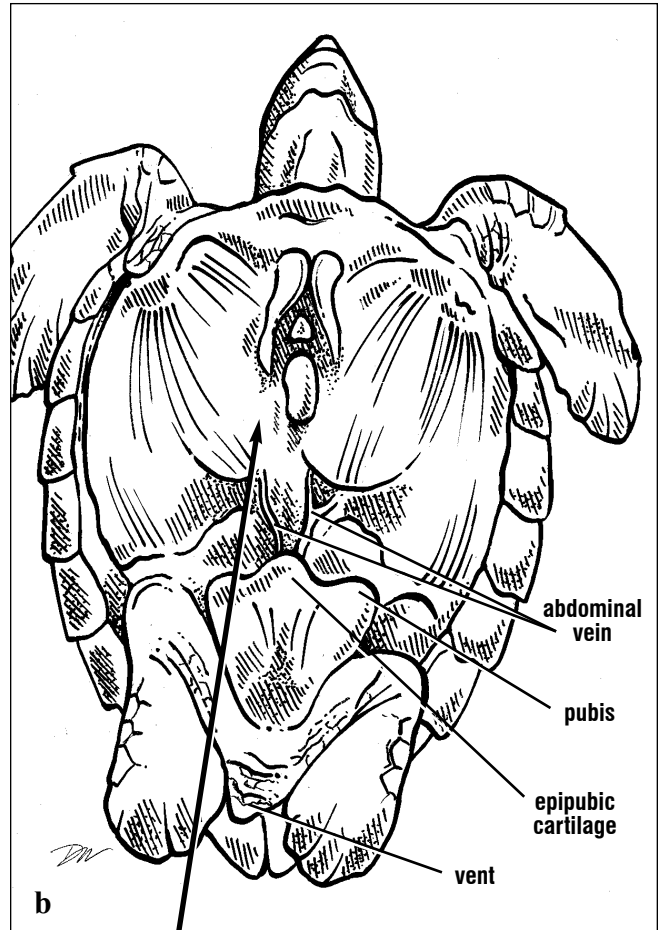
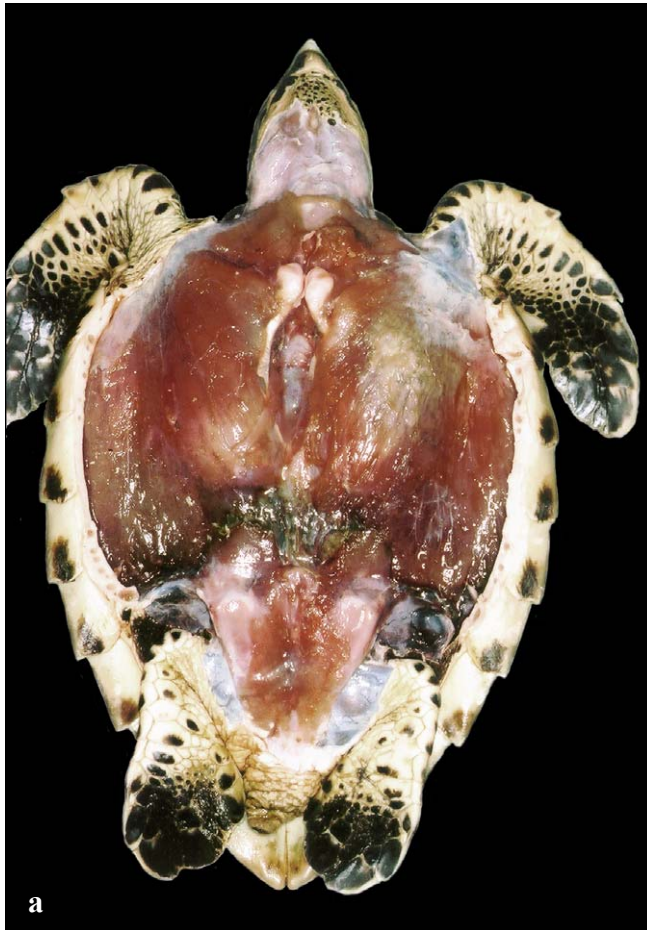
the lungs and laterally by the lobes of the liver. Within the pericardial sac, the heart is bathed with clear, colorless to slightly yellow pericardial fluid. All turtle hearts have four parts or chambers (Fig. 127): a **sinus venosus**, two large **atria** and a **ventricle**. The ventricle is thick-walled and internally subdivided into three compartments, the **cavum venosum**, **cavum arteriosum** and **cavum pulmonae** (not shown). These three ventricular compartments are separated only partially from one another.

The posterior part of the pericardium and ventricle apex are attached to the peritoneum by the gubernaculum cordis (Fig. 129). This structure anchors the heart during ventricular contraction.

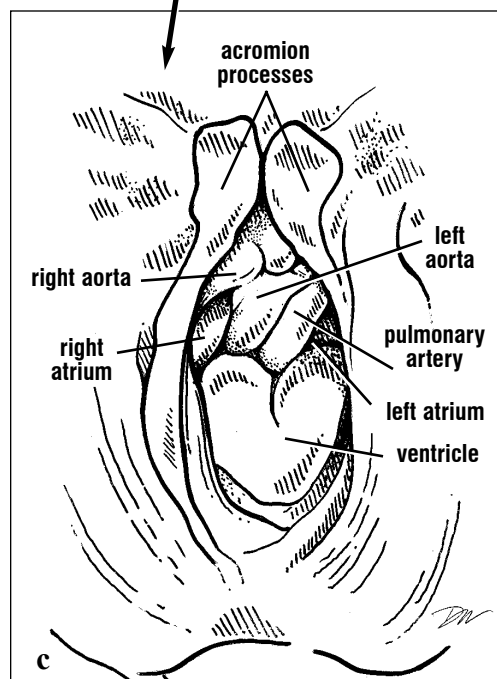


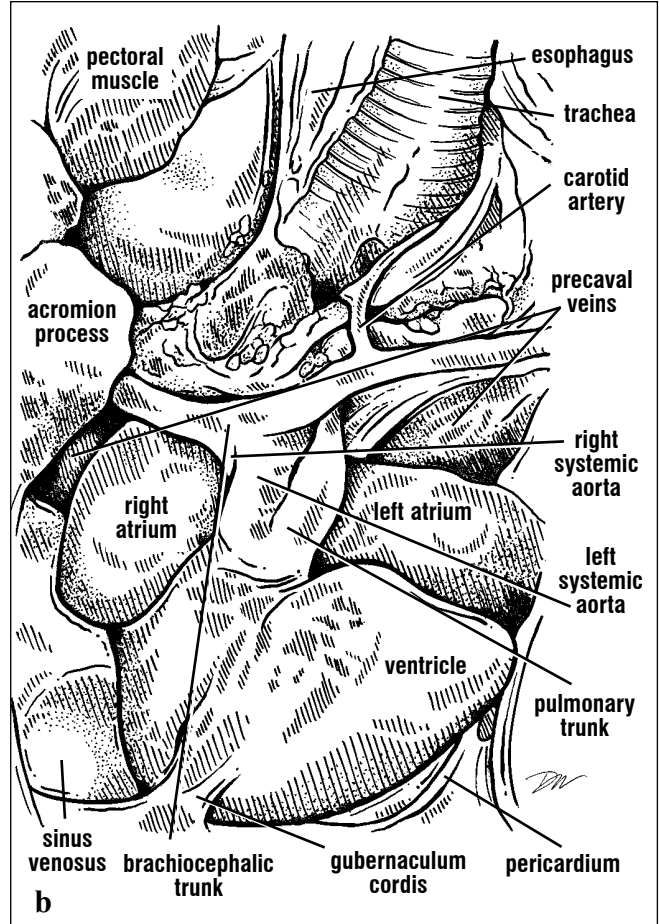
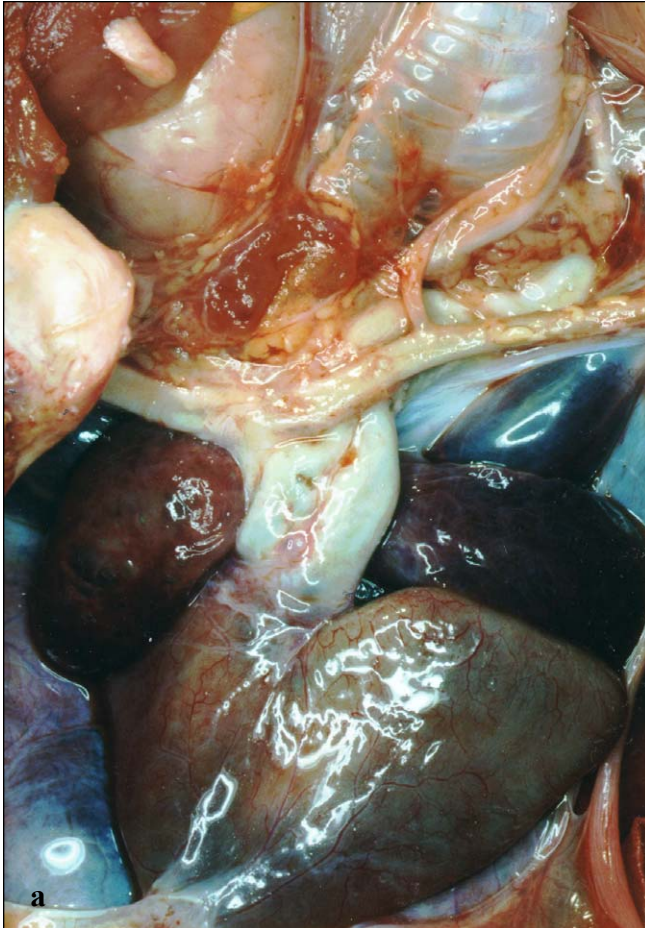Figs. 127a and 127b. Ventral heart. The heart is exposed after removing the pericardium. The more dorsal sinus venosus is not visible. Both aortas turn dorsally and are obscured partially by the

brachiocephalic trunk. The pulmonary arteries arise from a common base, the pulmonary trunk. The abdominal veins from the posterior muscles are exposed posterior to the heart.



Figs. 128a, 128b, and 128c. Landmarks for location of the heart after removal of the plastron. The two acromion processes and acromial-coracoid ligaments frame the pericardium ventrally. When the plastron is removed carefully, the paired abdominal veins are preserved. They drain the ventral pelvic muscles; blood flows anteriorly returning toward the two lobes of the liver. View c shows a close-up of the heart after removal of the ventral pericardium.





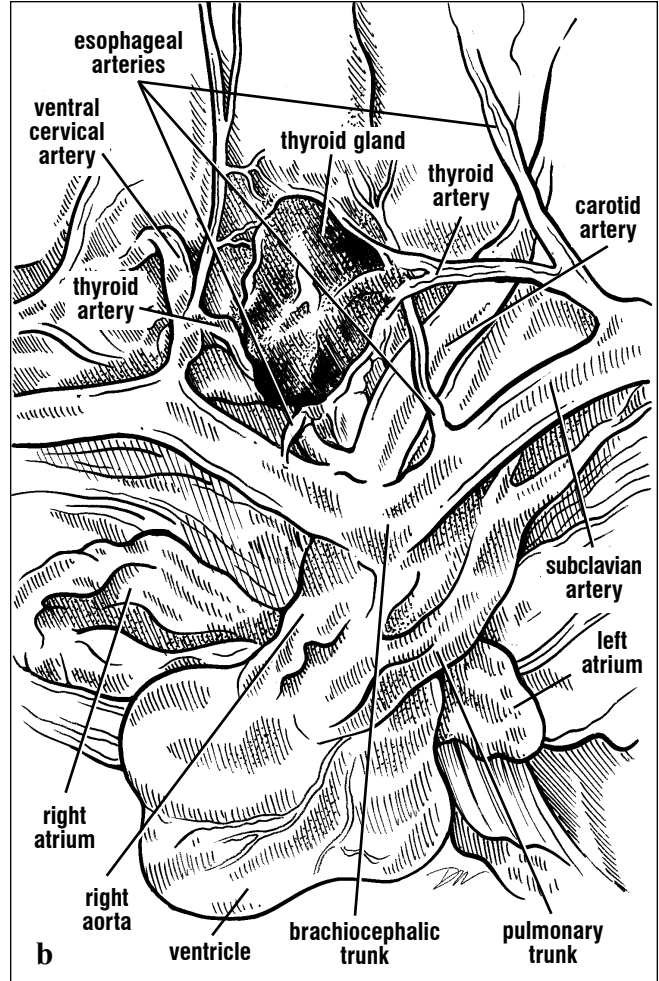
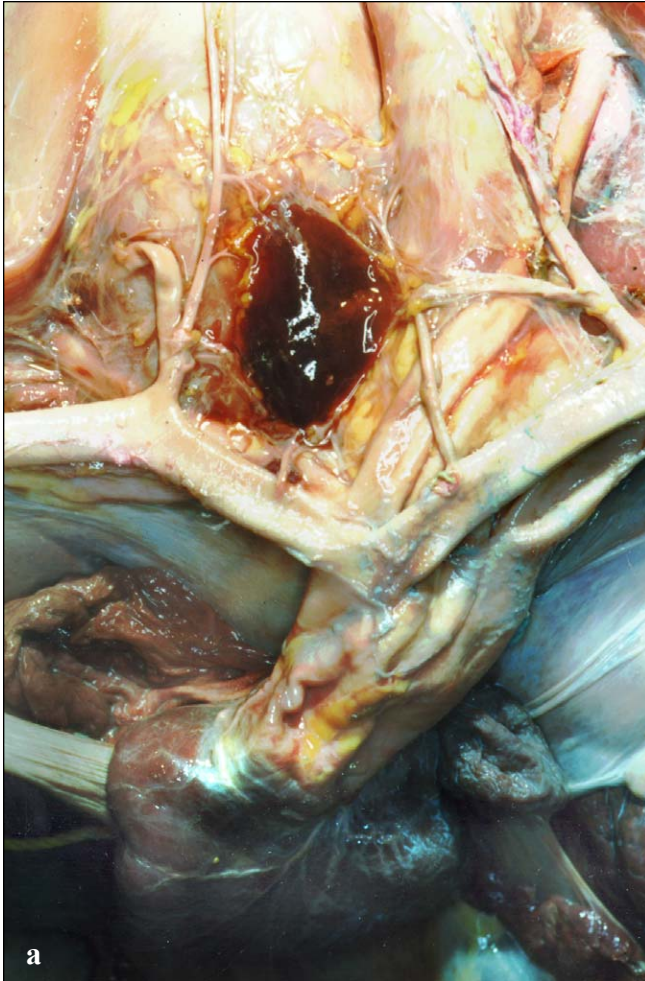
Figs. 129a and 129b. The four chambers of the heart can be identified in this ventral view. The ventral pericardium has been trimmed away to show both the heart and its great vessels. The apex

of the ventricle is anchored to the pericardium and peritoneum posteriorly. The venous drainage from the anterior body to the precaval veins can just be seen lateral and anterior to the left atrium.

Arteries. Arising from the anterior and ventral part of the heart are the **great vessels**: two aortas and a pulmonary trunk (Fig. 129). The **right aorta** supplies blood to the head, limbs, and lower body, the **left aorta** to the viscera. The pulmonary trunk divides into the right and left **pulmonary arteries** taking the blood to the right and left lungs, respectively.

aorta gives off a branch right away called the **brachiocephalic trunk** and then continues posteriorly to the lower body where it joins the left aorta. The brachiocephalic trunk bifurcates; each branch produces a small **thyroid artery** to the thyroid gland anteromedially (Fig. 130). The branches of the brachiocephalic continue laterally as **subclavian arteries** (Figs. 129-130). The brachiocephalic trunk acts as a landmark for locating the thyroid and thymus glands (Glands; Figs. 159-160).

The branches of the major vessels are good landmarks for locating organs and hence can serve like a map to locate specific structures. The right



Figs. 130a and 130b. Anterodorsal view of the heart and its major arteries. The great vessels emerge as three large vessels. The right aorta gives rise to the brachiocephalic trunk before it bends posteriorly. The thyroid arteries arise from

the brachiocephalic trunk shortly after it bifurcates, (or, in this case, from the carotid arteries). It then gives rise to the left and right subclavian arteries. The right carotid is not dissected free of its connective tissue.

The **carotid** arteries (Figs. 129-130), then the **ventral cervical arteries**, arise from either the brachiocephalic trunk or the subclavian arteries lateral to the thyroid arteries (Fig. 130). The carotids (often termed common carotids) supply blood to the head. They bifurcate near the skull to form the **external** and **internal carotid arteries**. The **ventral cervical arteries** travel anteriorly then bifurcate to supply branches to the esophagus. The subclavian arteries continue laterally towards the flippers; near the junction of the scapula and

coracoid they become the **axillary arteries**. There, branches to the scapular musculature arise (**anterior subscapular artery**). The axillary artery gives off both a branch to the carapace just prior to entering the forelimb, the **marginocostal artery** which travels posteriorly along the lateral aspect of the shell, and a branch to the ventral pectoral muscles, the **pectoral artery** (Fig. 131). As the axillary artery crosses the humerus, it becomes the **brachial artery** supplying radial, ulnar, then distally the digital arteries of the flipper.

CIRCULATORY ANATOMY

The major arterial and venous paths are summarized diagrammatically in Figs. 131-132. These diagrams show the most common routes taken by vessels. However, the circulatory system

is among the most variable of all organ systems and hence, sometimes vessels branch in unique and unexpected manners.

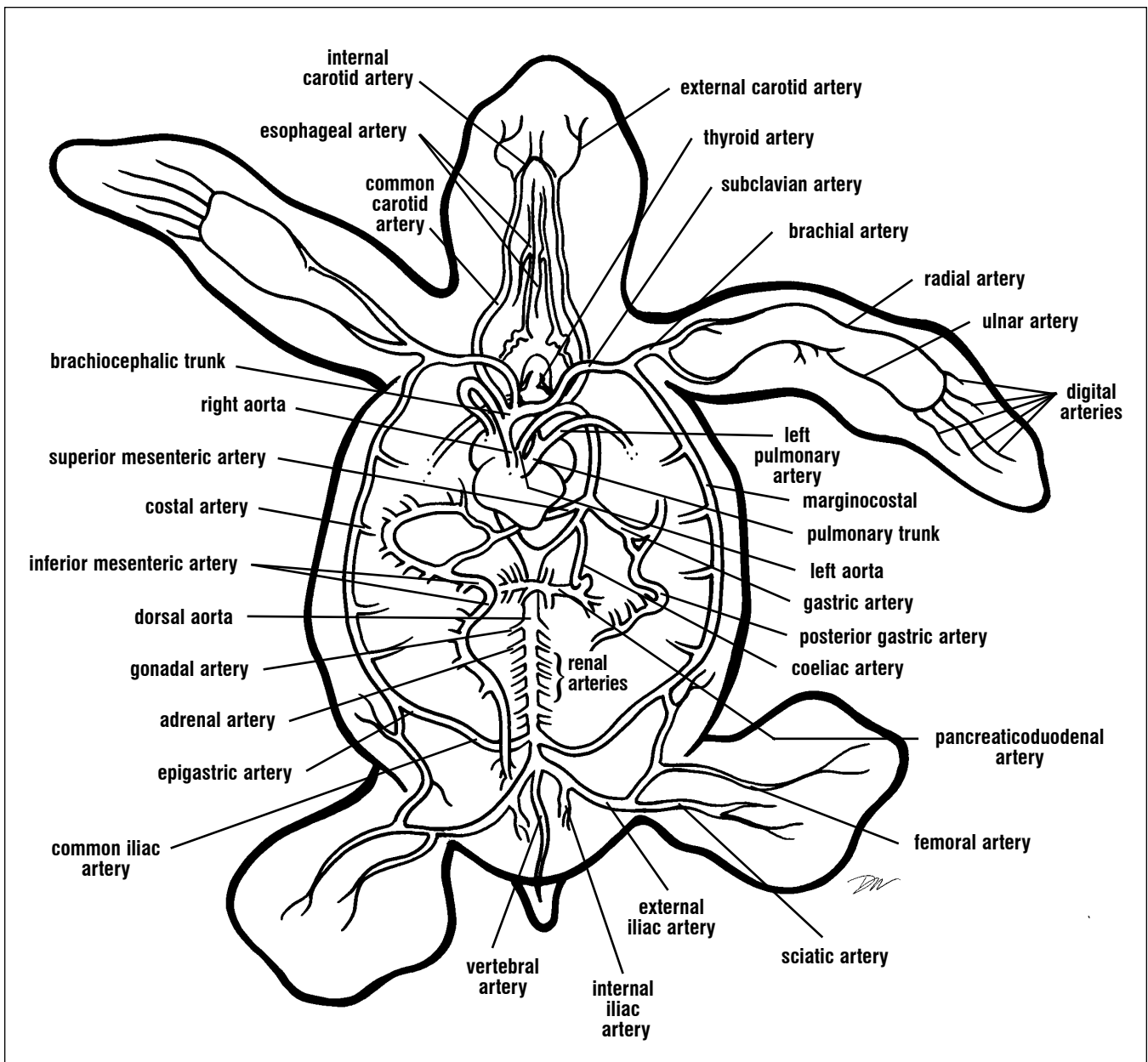


Fig. 131. Major arteries, ventral view. The major arteries are shown diagrammatically. Some subdivisions are not labeled for diagram clarity.

These include the ventral cervical, axillary, anterior scapular, pectoral, anterior pancreaticoduodenal, and haemorrhoidal arteries.

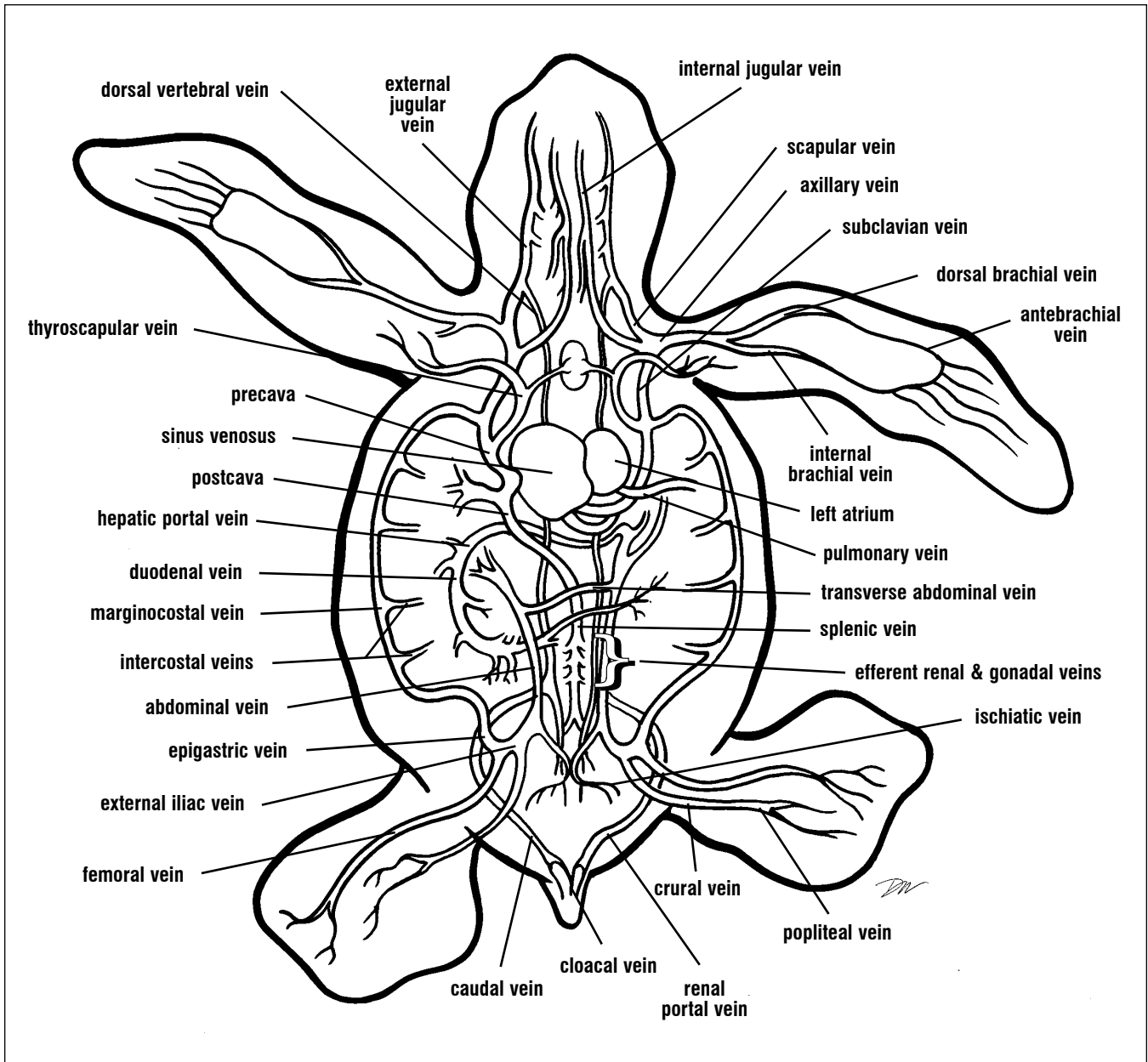


Fig. 132. Major veins, ventral view. Note that all branches are not shown or labeled to minimize diagram complexity. These include the azygos, transverse and central vertebral, eosophageal,

hepatic, pectoral, pericardial, vesicular, pelvic, lipoidal, hypogastric, gastric, anterior and posterior pancreatic, mesenteric, common mesenteric, and inferior mesenteric.

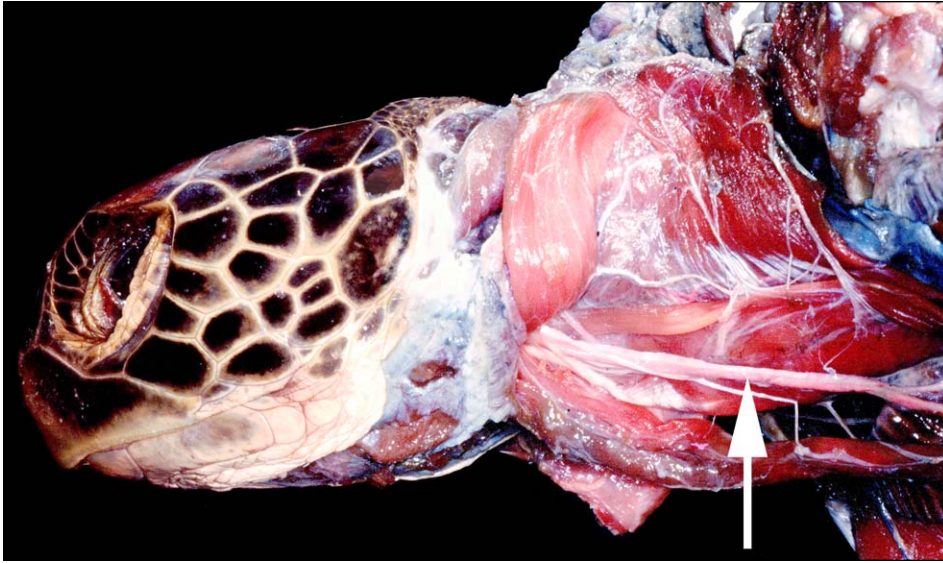


Fig. 133. *This lateral view of a green turtle has all superficial neck muscles cut and reflected dorsally. The arteries and veins were injected with latex to provide contrast. The carotid artery (at arrow) is deep and lies adjacent to the longus colli muscles of the cervical vertebrae.*

The left aorta, the middle of the three great vessels, turns dorsolaterally and passes the level of the stomach before producing three branches: the **gastric artery**, the **coeliac artery** and the **superior mesenteric artery**. The gastric artery bifurcates

quickly and sends branches to the greater (lateral aspect) and lesser (medial aspect) curvatures of the stomach (Figs. 135-136). The coeliac artery branches shortly after leaving the left aorta and forms the **anterior pancreaticoduodenal artery** to the pancreas, duodenum and stomach and the **posterior pancreaticoduodenal artery** to the distal pancreas, duodenum, liver, and gallbladder (Fig. 136). The superior (or anterior) mesenteric artery gives off many branches that fan out through the intestinal mesenteries and supply the small intestines. After giving off the superior mesenteric artery, the left aorta continues posteriorly where it joins the right aorta (typically) to form a single dorsal aorta. The position where the two join is variable, but generally is within the middle third of the body.

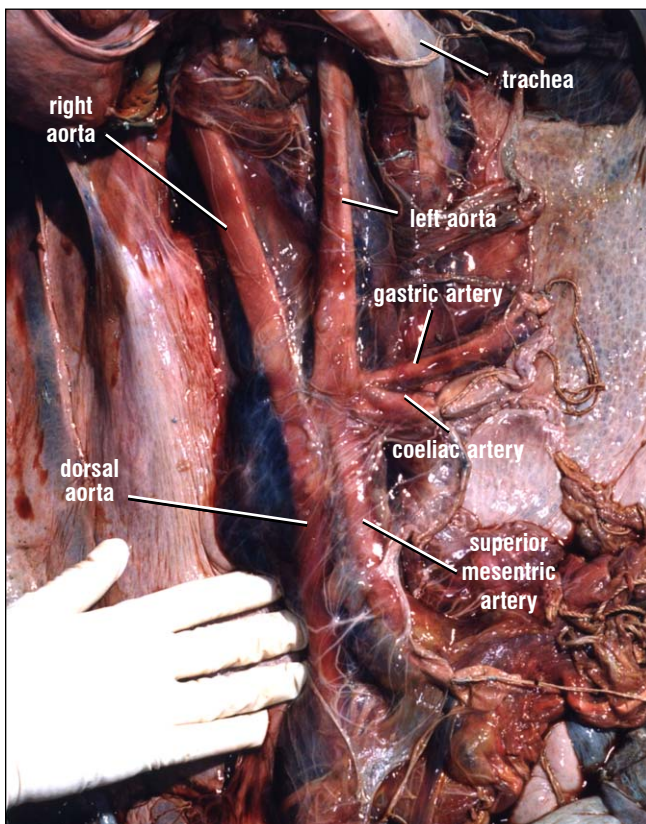
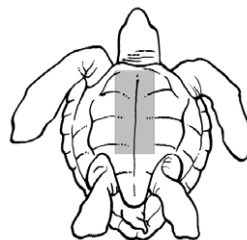
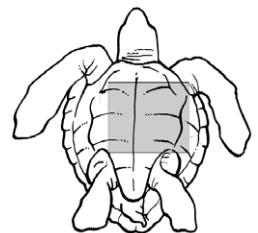
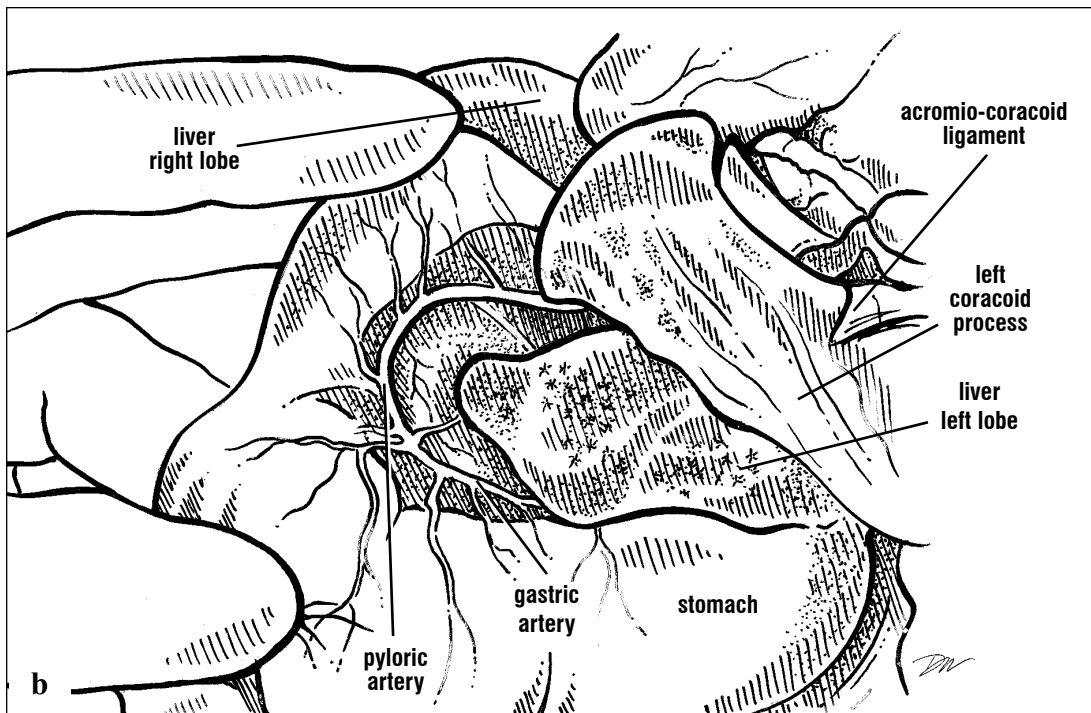
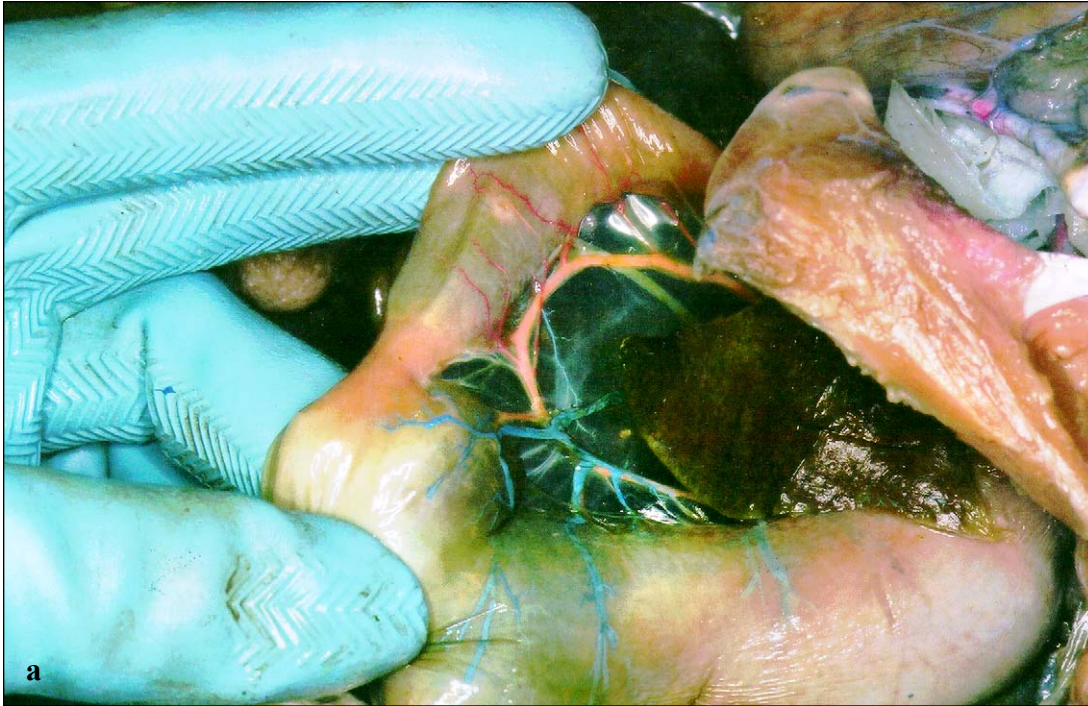
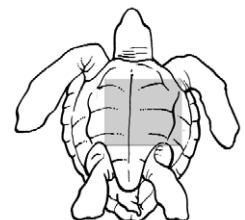
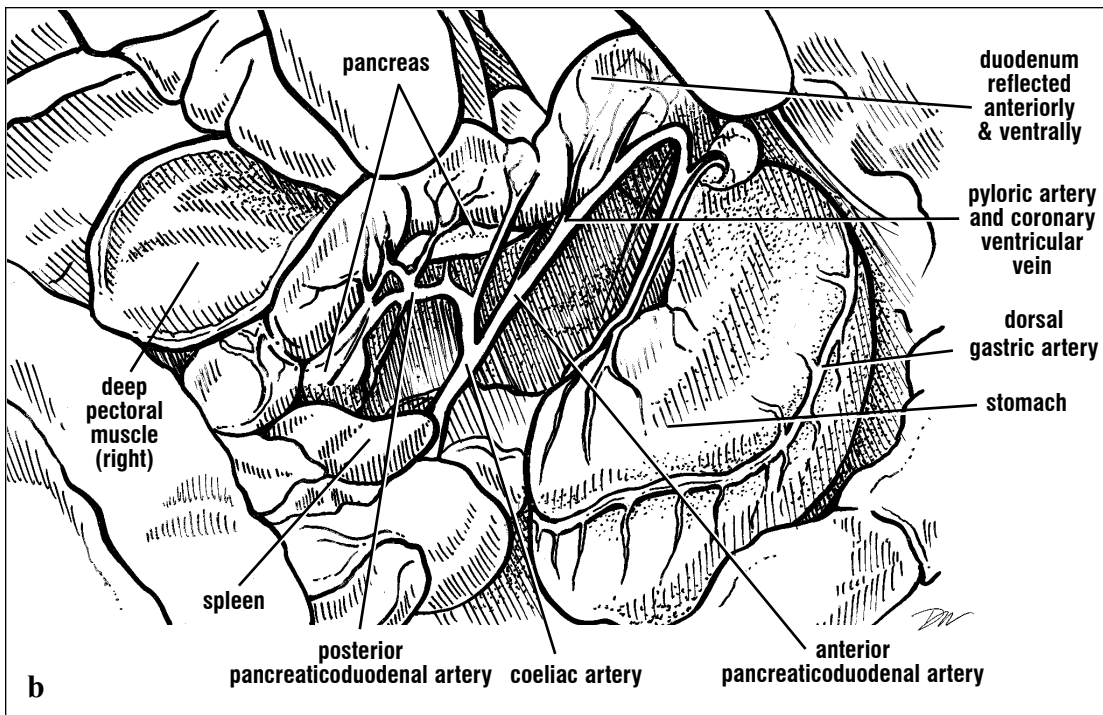
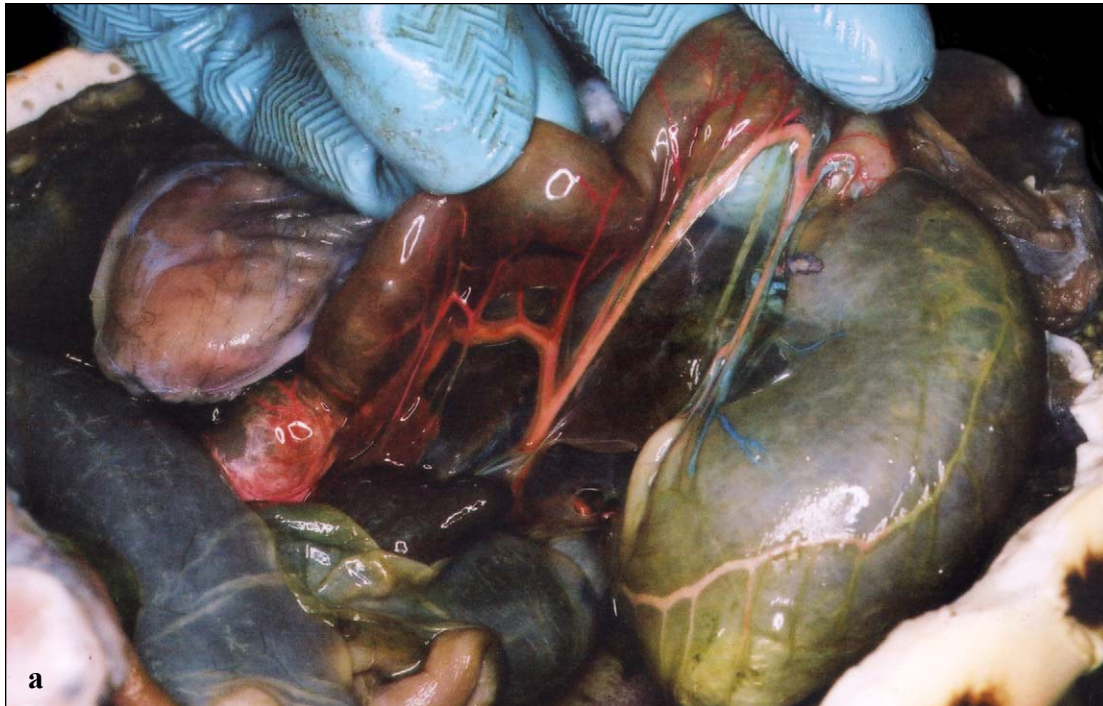

Fig. 134. *The ventral view of the left aorta and its major branches in a loggerhead after removal of the heart and viscera. Anterior is toward the top of the picture. The right aorta joins the left aorta very early in this loggerhead, just posterior to the origin of the superior mesenteric artery.*





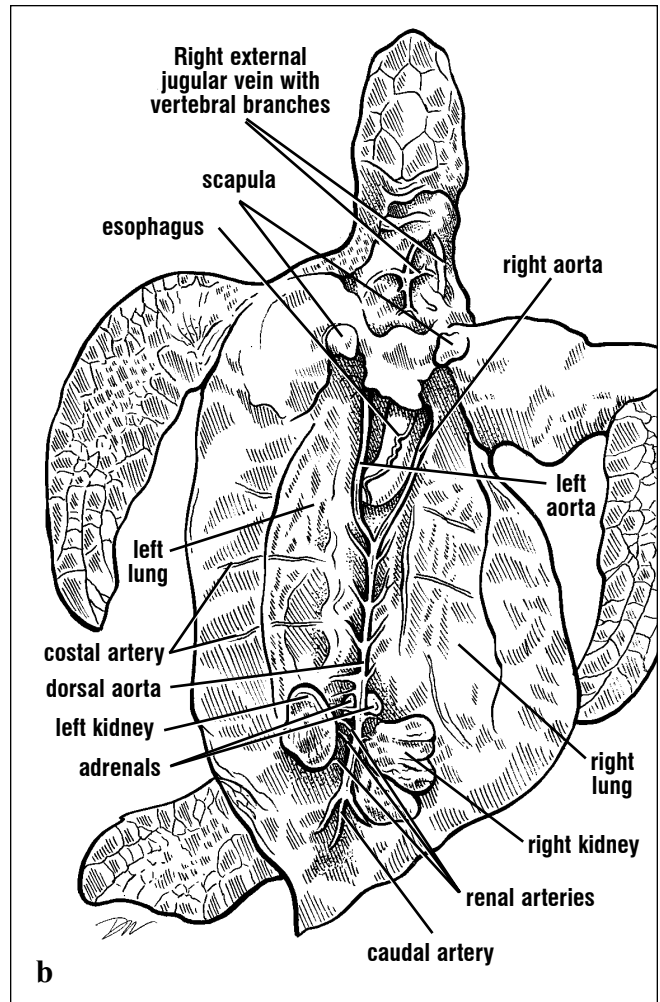
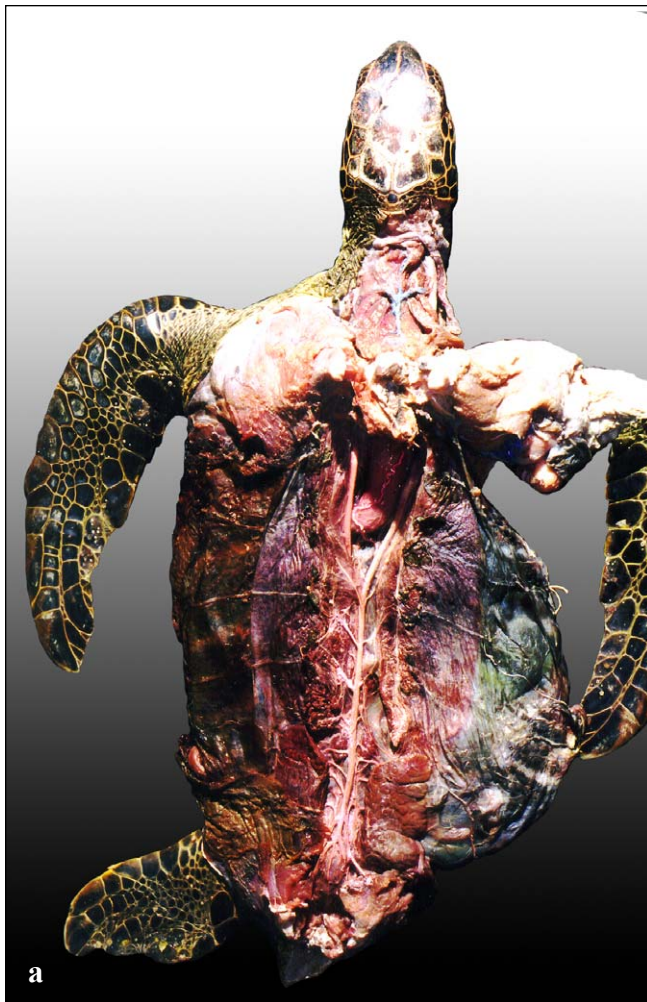Figs. 135a and 135b. Circulation of the stomach. The ventral gastric artery drains to the lesser curvature of the stomach. It becomes the pyloric artery at the level of the pyloric sphincter.



Figs. 136a and 136b. Arteries and veins of the stomach, pancreas, and duodenum. The dorsal gastric artery drains to the greater curvature of the stomach. The coeliac artery, the second artery arising from the left aorta, supplies these branches to the duodenum, the stomach near the pylorus, and to the pancreas.

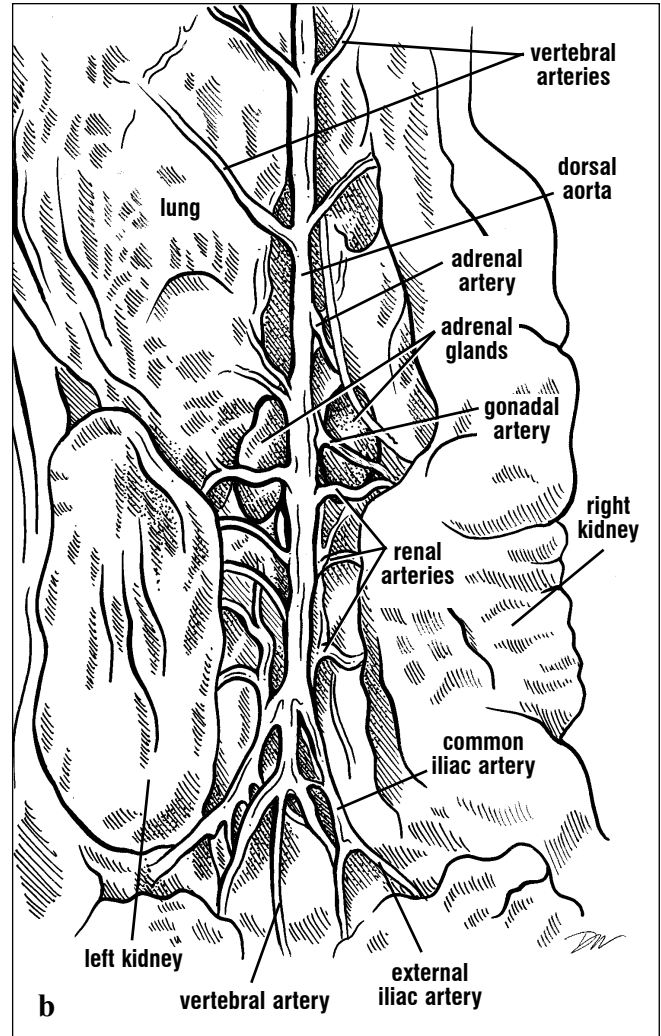
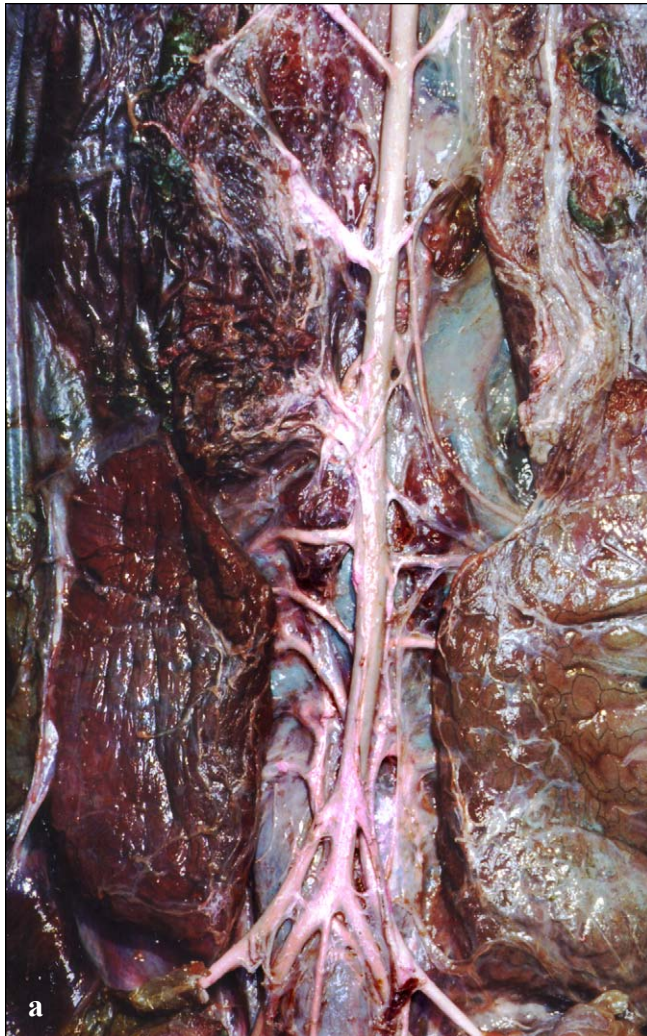The **dorsal aorta** (Figs. 134, 137-138) continues posteriorly and gives off paired branches, the **costal arteries** of the carapace, **gonadal arteries** to the ovaries or testes (there may be more than one per gonad), a pair of **adrenal arteries**, and

three or more **renal arteries** to each kidney (Figs. 137-138). A pair of **epigastric arteries** branches off the dorsal aorta at the level of the kidneys; they travel laterally to join the marginocostal artery of the carapace.



Figs. 137a and 137b. The carapace has been removed from this green turtle and the arteries injected with latex. The right and left aortas join along the middle third of the body. Costal (intercostal) branches extend anteriorly and across

the body. Branches to the gonads, adrenals, kidneys, and hind limbs arise, then the caudal artery continues posteriorly along the midline to the tail and cloaca. This animal was missing its right hind limb.



Figs. 138a and 138b. The carapace has been removed from this green turtle. The arteries are injected with latex to show the arterial branches to the gonads, adrenal glands, and kidneys. Variability is common in the circulatory system and is shown here. In this animal, the right gonadal artery is long and crosses dorsal and to the right adrenal gland, rather than extending lateral or anterior to it. There are 3 asymmetric (rather than symmetric) pairs of renal arteries

supplying the kidneys. The epigastric arteries do not arise in the typical manner from the dorsal aorta, but instead from the left common iliac. The common iliacs continue as the external iliacs then divide to form the femoral and sciatic arteries. The internal iliacs arise directly from the dorsal aorta, in this case, turn ventrally, and supply blood to the bladder and large intestine. The caudal (vertebral) artery continues posteriorly along the midline.

The arteries to the pelvic limbs, the **external** and **internal iliac arteries**, may leave the dorsal aorta on each side via paired trunks (common iliacs), or they may branch off separately (Figs. 138-139). The external iliac supplies the **femoral** and **sciatic arteries** to the hind leg (Fig. 130). The internal iliac provides branches to the bladder and gonadal ducts, and the **haemorrhoidal artery** to the large intestine. The dorsal aorta then extends to the tail as the **vertebral (caudal) artery** (Figs. 131, 138-139).

Pulmonary Trunk. The pulmonary trunk divides shortly after leaving the heart and supplies the right and left pulmonary arteries to the lungs (Figs. 129-130). The pulmonary arteries enter the lungs along the dorsal side of the bronchus, and travel posteriorly with the bronchi giving off multiple branches throughout the lung. The pulmonary artery walls are thickened as a muscular sphincter near the lungs. The lumen of each of the great vessels near the heart should be roughly uniform in thickness, except for the pulmonary arteries as they approach the lungs.

Pulmonary Veins. Capillaries, venules (small veins), and veins within the lung coalesce into branches that drain into the **pulmonary veins** (not shown). The pulmonary veins travel along the ventral surface of each bronchus, then exit the lung anteriorly and arch medially. They enter the left atrium dorsolaterally.

Systemic Veins. The venous circulation is described by tracing the veins away from the heart. However, it should be remembered that venous blood typically flows toward the heart. (It is noteworthy that flow direction can reverse in some

veins.) Multiple terms are used to describe the major veins. The synonyms are given to clarify terminology. Venous blood from the body drains into the **sinus venosus** from 4 major veins: the **left precava** (= left common cardinal, = left superior vena cava), the **right precava** (= right common cardinal, = right superior vena cava), the **left hepatic vein**, and the **postcava** (= posterior vena cava, = right hepatic vein; Fig. 132). The left and right precaval veins each drain the anterior body. Each precava receives branches from the **subclavian** and **azygos veins** and anteriorly from the internal and external jugular veins. The azygos vein is narrow and supplies the deep pectoral muscles (Fig. 140). The subclavian vein extends laterally. It receives the **thyroscapular vein** with thyroid branches from the thyroid gland and the scapular musculature, the **scapular, transverse scapular, and subscapular veins**. The transverse scapular vein supplies drainage for the **cephalic vein** from the dorsal arm and the posterior and ventral flipper (Fig. 132). After receiving the thyroscapular branch, the subclavian vein extends laterally and forms the **axillary vein** in the axilla (armpit). Many branches arise in the axillary as the venous component of the rete system. The axillary components rejoin as the **brachial vein** in the upper arm, and then bifurcate as the **internal brachial vein** to the posterior flipper and the **dorsal brachial vein** to the anterodorsal flipper. As in the arterial system, a vascular circumflex forms near or just distal to the wrist, and receives drainage from the interdigital veins found medial to each digit. Because of the extensive connective tissue layers in the forearm and flipper blade, these vessels were traced by destructive dissection and so are illustrated diagrammatically (Fig. 132).

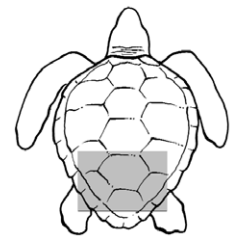
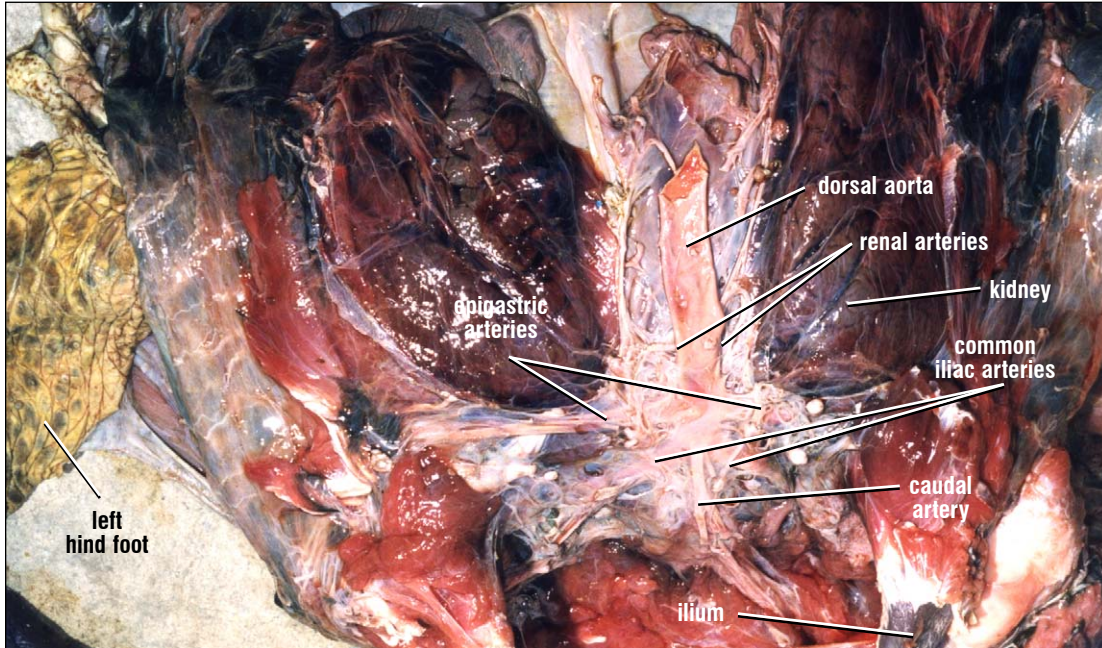


Fig. 139. Dorsal arteries to the posterior musculature and kidneys of a loggerhead.

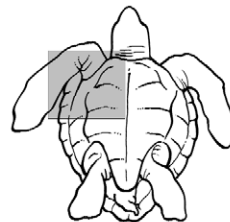
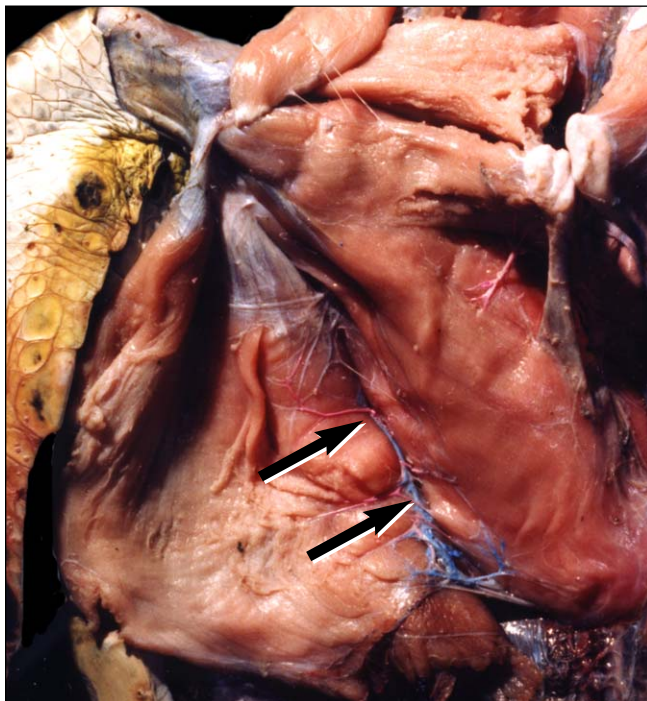
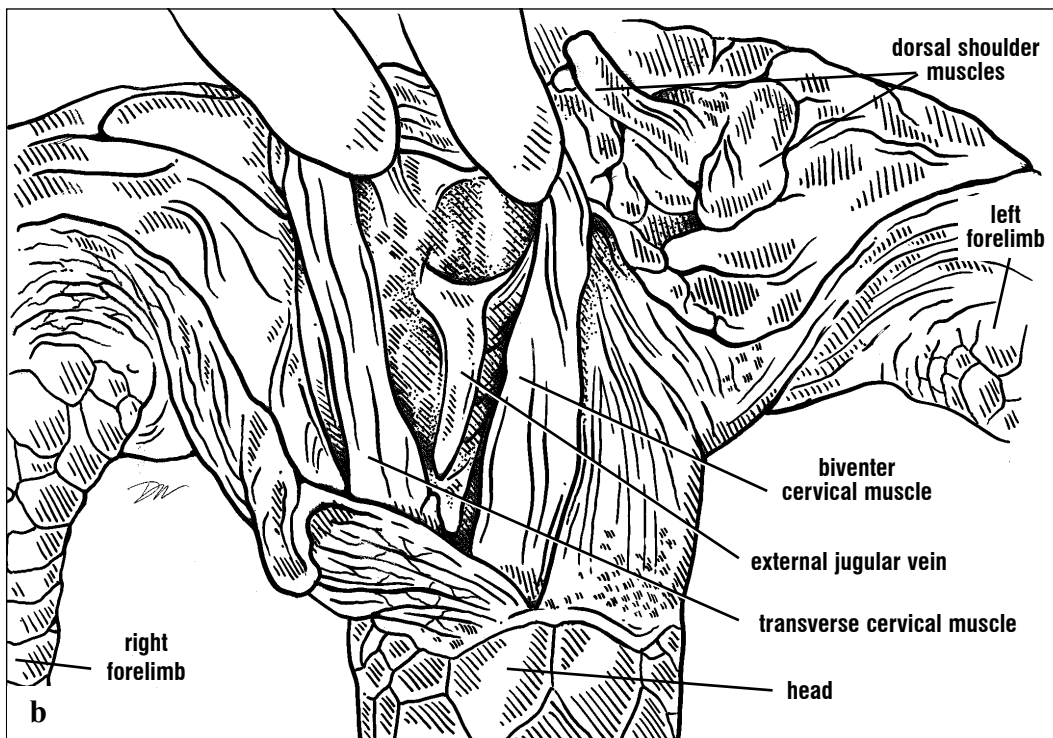
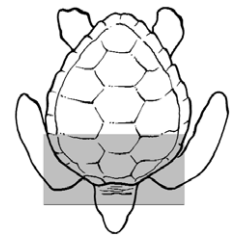
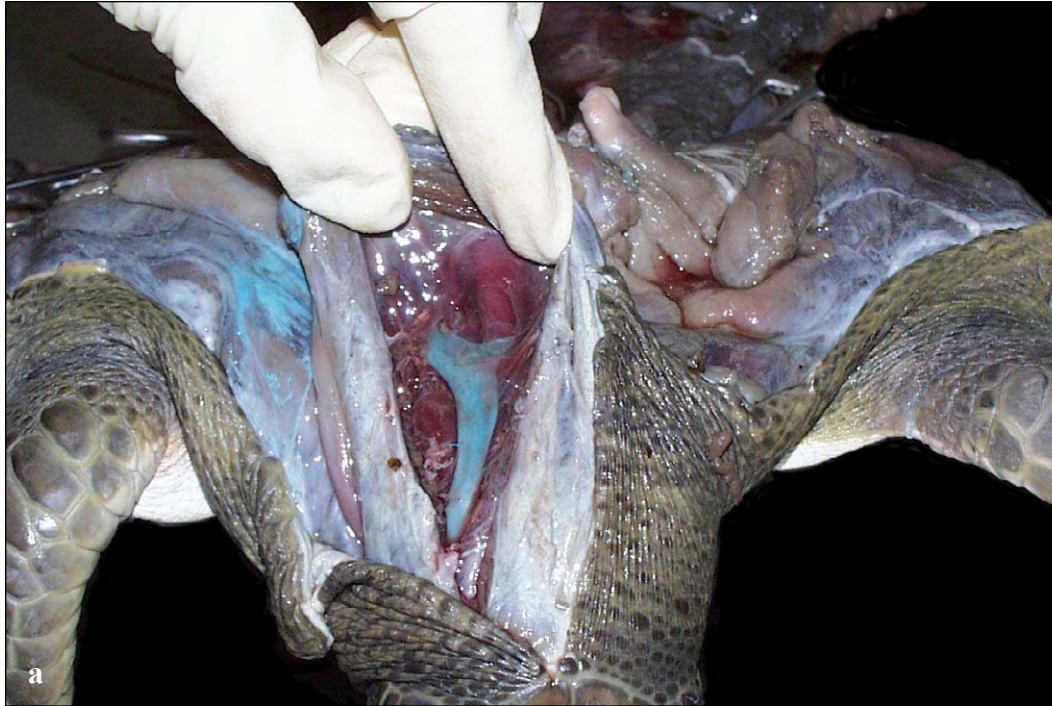


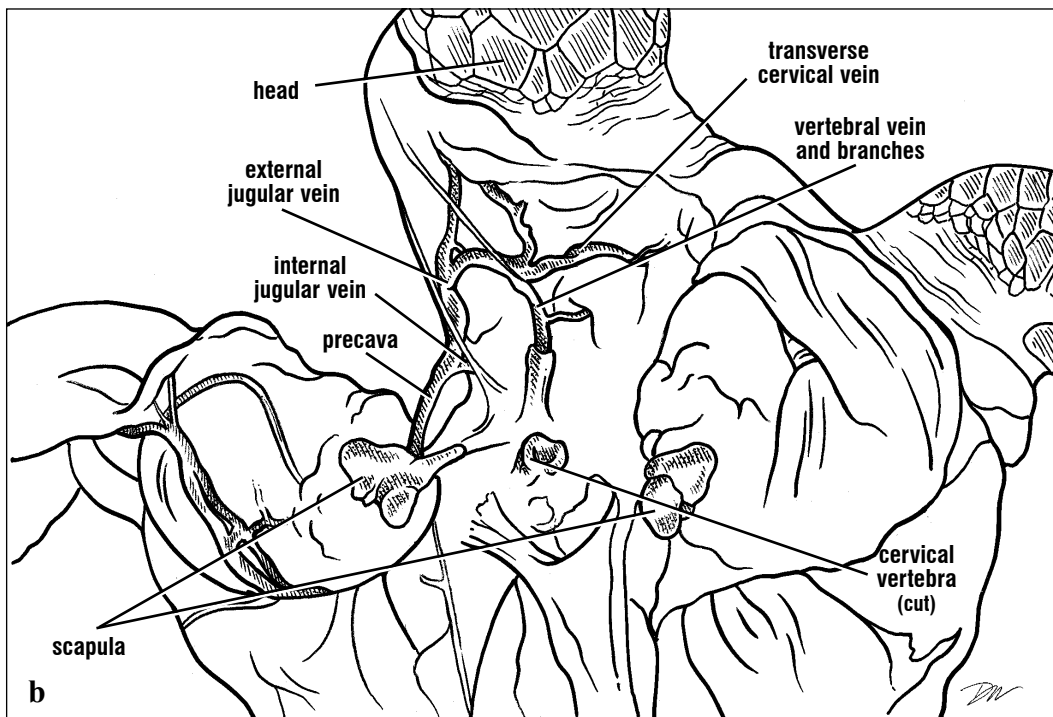
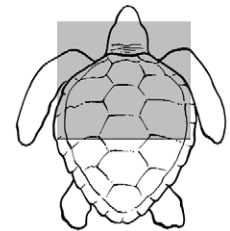
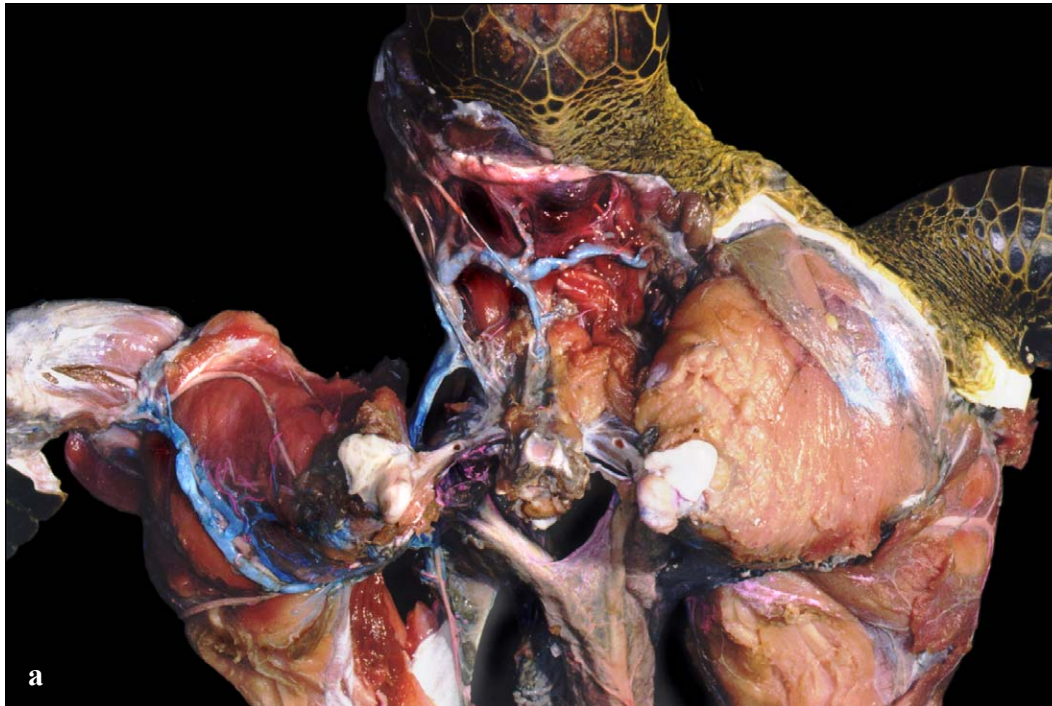
Fig. 140. The azygos artery and veins and branches of the pectoral vein supply the deep pectoral musculature. Here the pectoralis major has been reflected anteriorly to expose the azygos vessels (at arrows) supplying the coracobrachialis-anterior and -posterior parts, as well as branches to the biceps profundus.

The external jugular vein is located relatively dorsal and superficial in the neck. The **biventer cervical** (= splenius capitus) and **transverse cervical** muscles are good dorsal landmarks for the external jugular. These muscles are obvious

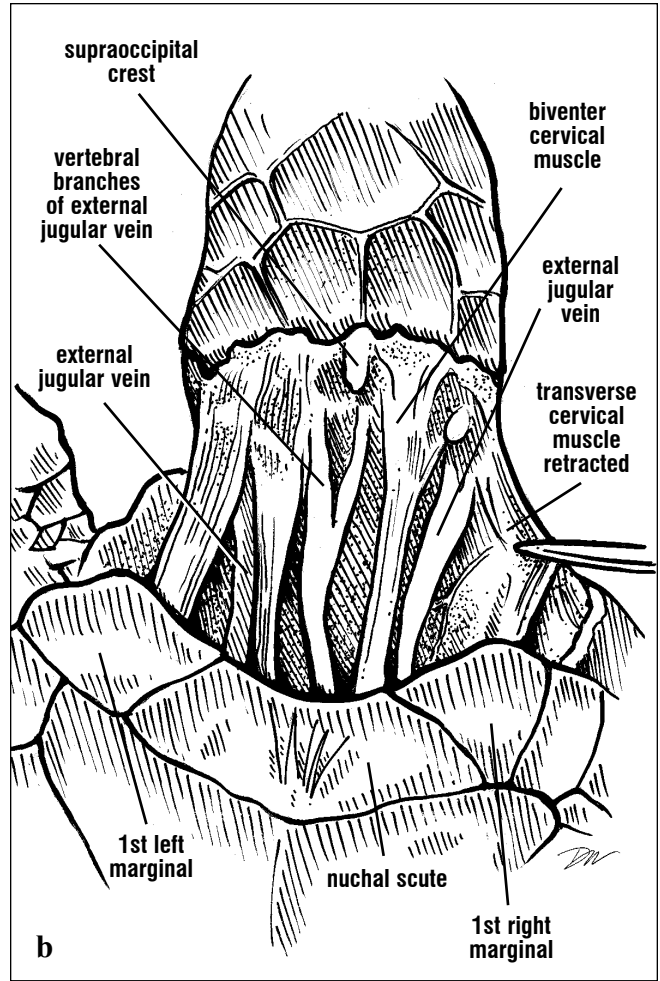
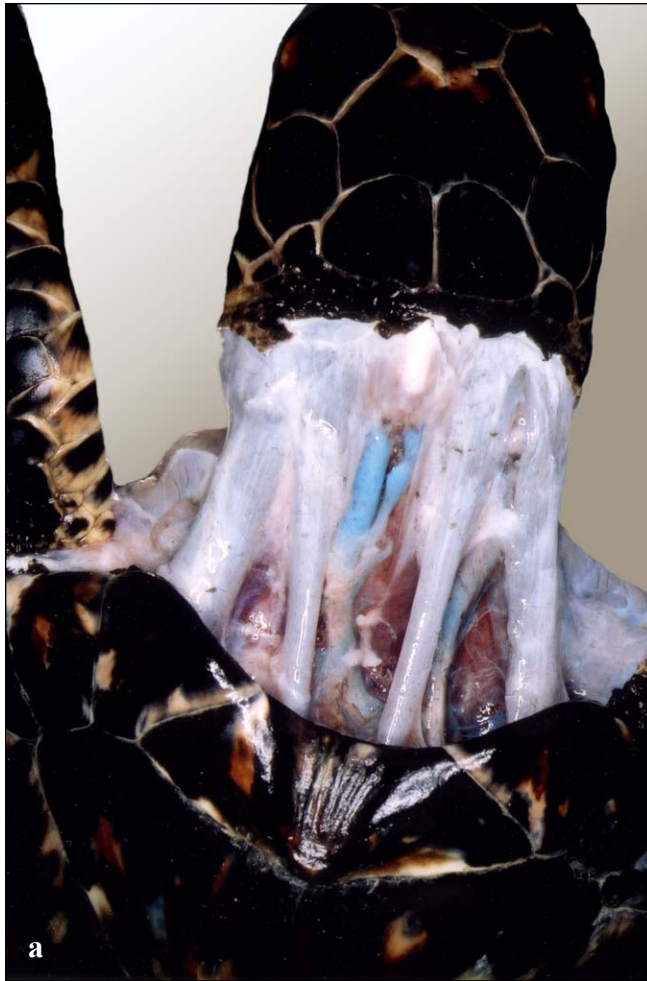from the exterior and are to either side of the vessels; the external jugular is located deep and between them (Figs. 141-142), and medial to the transverse cervical muscle.



Figs. 141a and 141b. *Green turtle cervical circulation.* The external jugular vein was dissected free on the turtle's right and injected to provide contrast. It shows the transverse cervical branch extending medially into the muscle.

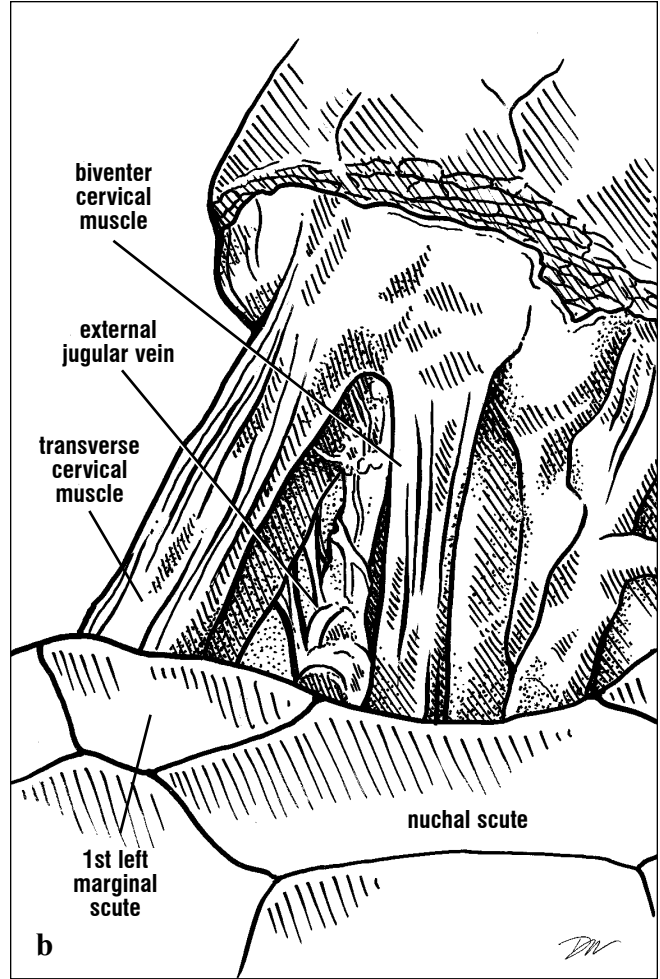
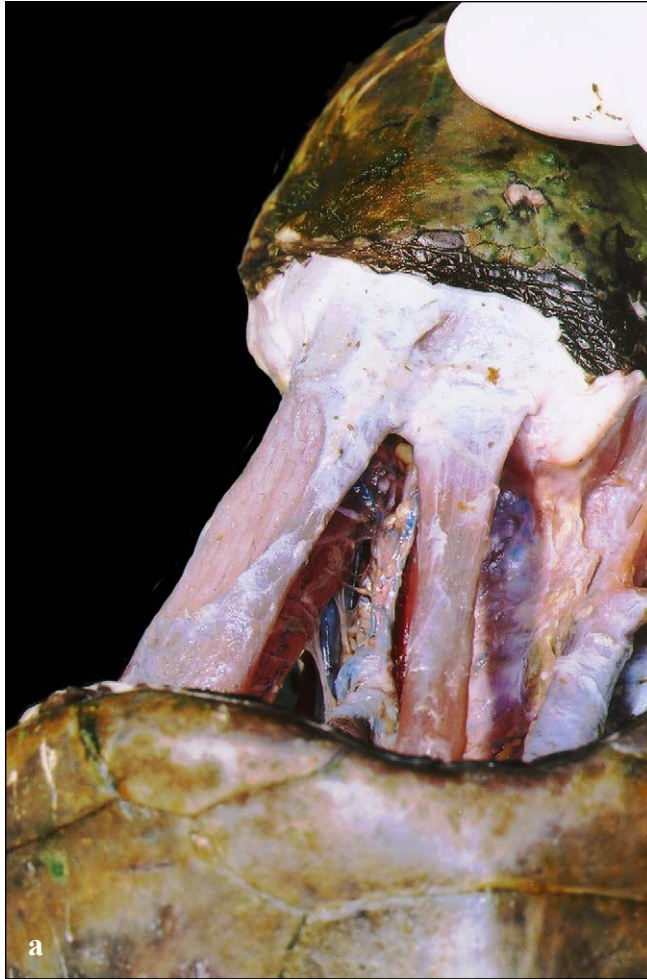

Figs. 142a and 142b. Dorsal view of the neck of a green turtle with the carapace removed. The precava (superior vena cava) receives blood from the subclavian veins. The relatively small external jugular vein of green turtles receives relatively few branches when compared with the anatomy in other cheloniids.



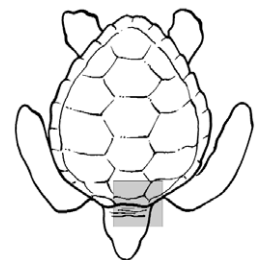
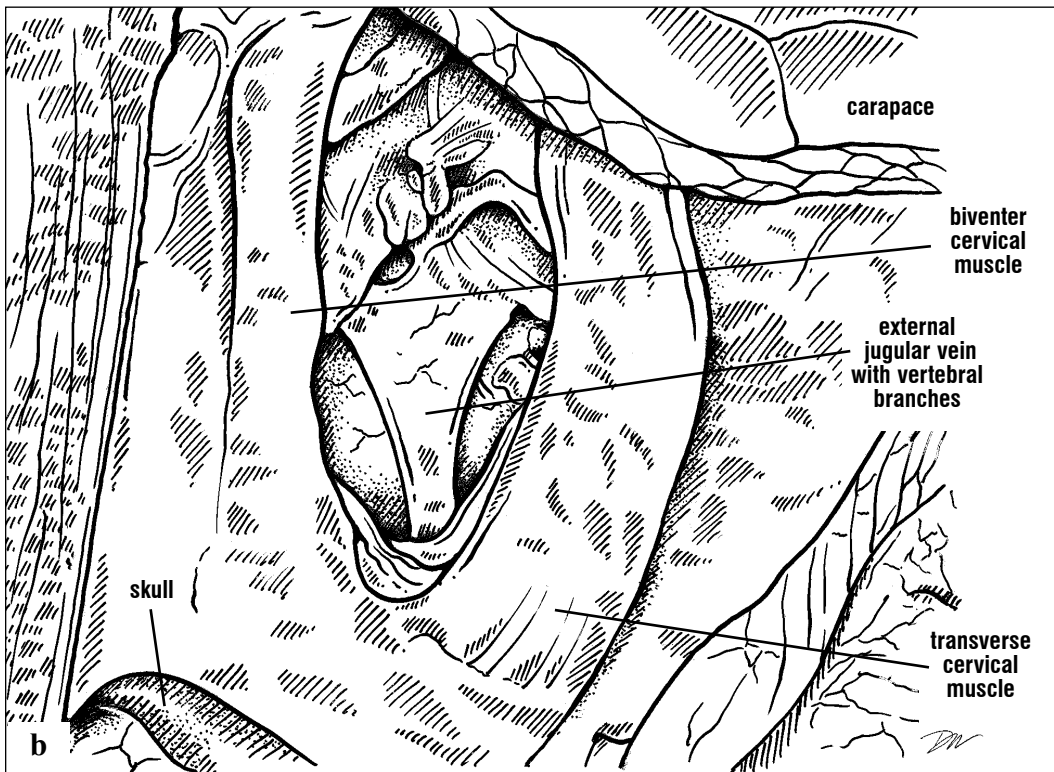
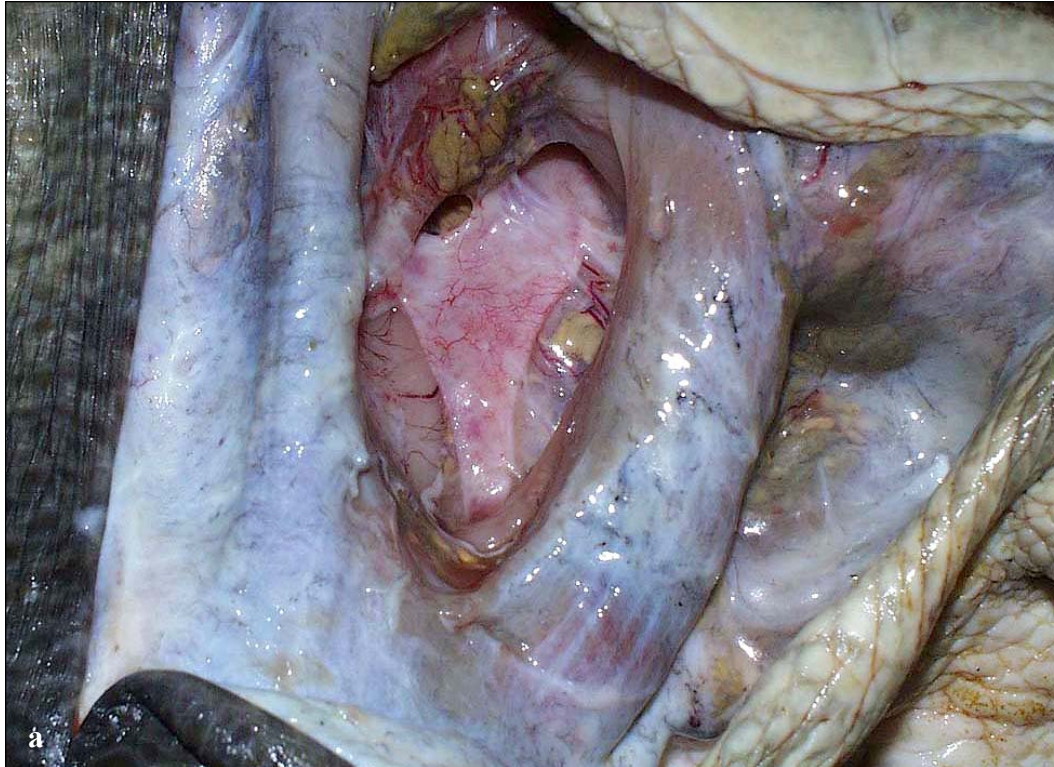
Figs. 143a and 143b. Dorsal view of the external jugular veins and the vertebral vein. In this turtle the transverse veins are not obvious. There is an anterior bifurcation of the vertebral vein at the level of the neck rather than at the skull in this

individual. The external jugular vein of this hawkbill receives dorsal and ventral vertebral branches from the cervical musculature proximally and distally. However, there are no branches along most of the intervening length.

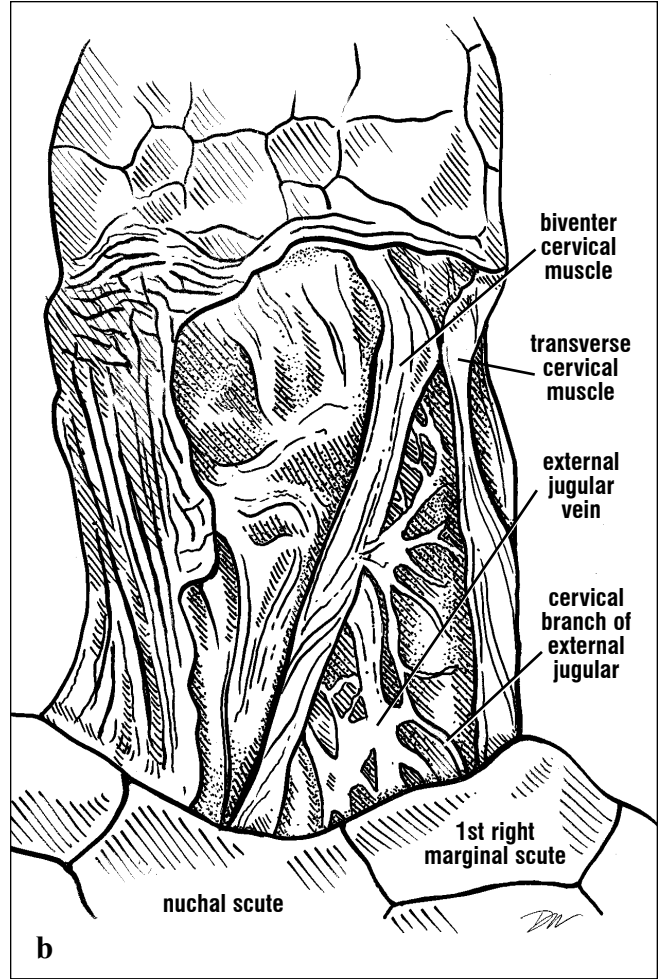
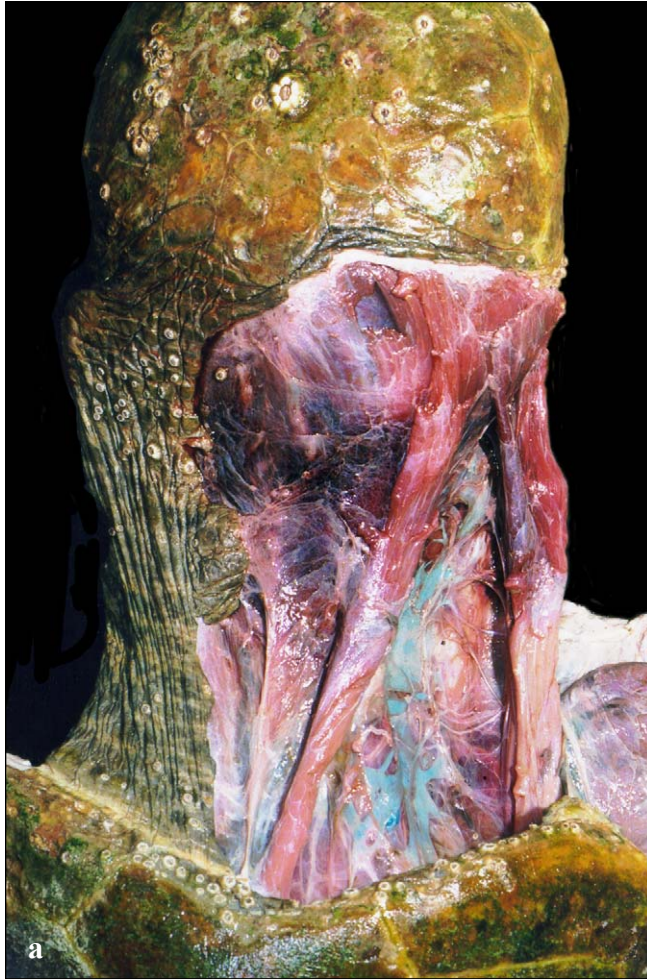


Figs. 144a and 144b. *The external jugular vein and its network of vertebral branches are obvious in this Kemp's ridley. Multiple vertebral branches*

are common in this species between the prominent dorsal neck muscles.

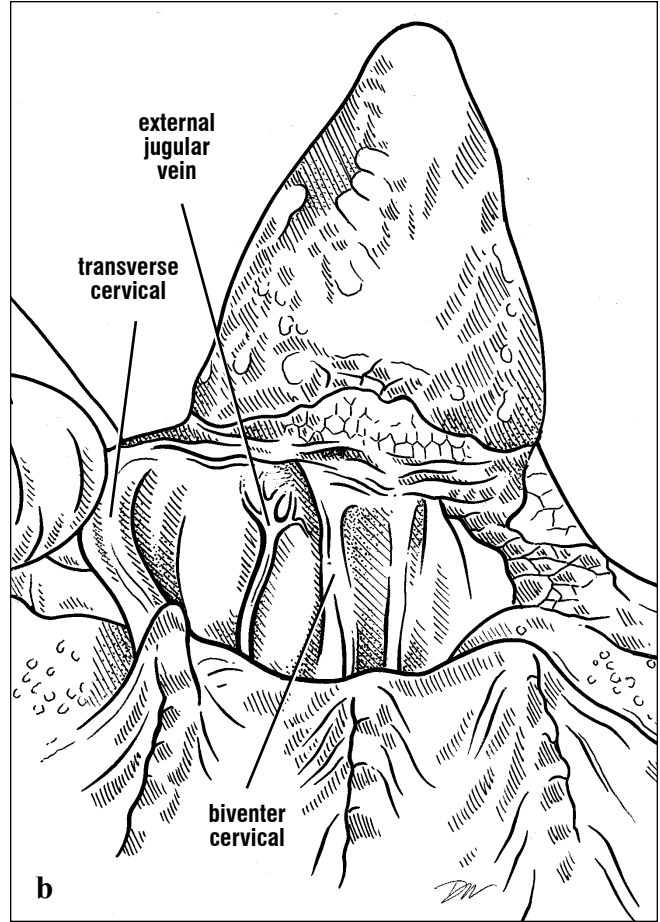
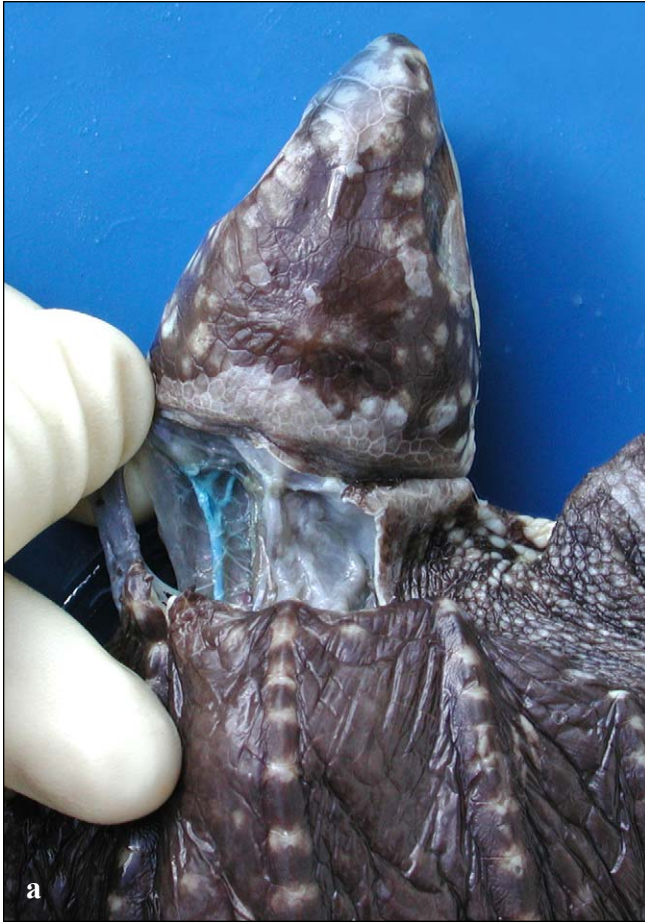

Figs. 145a and 145b. Dorsal view close-up of a Kemp's ridley external jugular vein, and its transverse branch arises medially (toward the left in this picture).



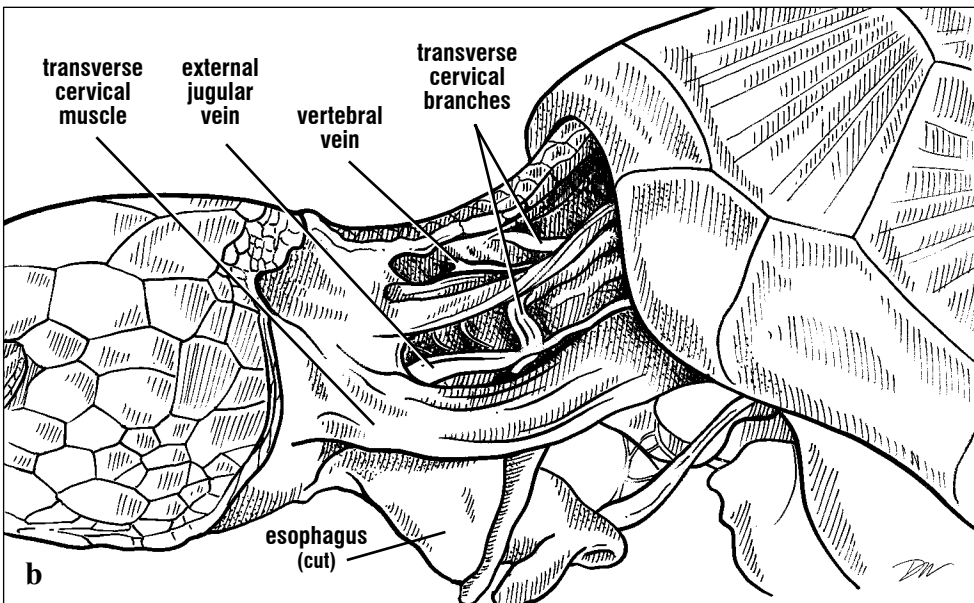
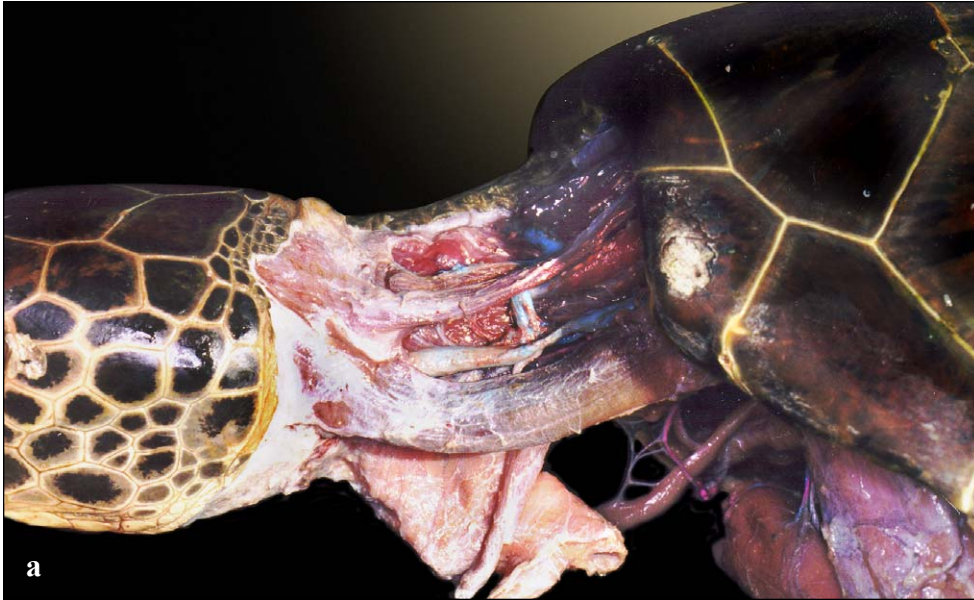
Figs. 146a and 146b. *The external jugular vein is large and is associated with many anastomoses (networks of interconnected blood vessels) as well*

as cervical (vertebral) branches to the neck muscles of loggerheads.



Figs. 147a and 147b. Dorsal neck circulation in a leatherback. The external jugular vein is large and is associated with many small cervical (vertebral)

branches to the neck muscles. The vessel is located deep between the transverse cervical and biventer cervical muscles.



Figs. 148a and 148b. Lateral view of the external jugular vein and both right and left transverse cervical branches in a green turtle. The vertebral vein is visible for part of its length, and is medial and deep to the cut skin of the dorsal neck.

The external jugular vein (often termed the dorsal cervical sinus) is a commonly used venipuncture (blood collection) site in sea turtles. The external jugulars are large and extend from the base of the neck into the head where they drain the structures of the head. Each gives off at least one transverse branch that joins the other medially (Figs. 141-147). Often a small central **vertebral vein** extends along the midline from the junction of the transverse cervical veins and provides drainage to

the dorsal cervical muscles, cervical vertebrae, and the spinal meninges. In *Chelonia mydas* and *Eretmochelys imbricata*, the external jugular is smaller in diameter and branches little (Figs. 141-143, 148-149). This vessel branches frequently in the dorsal cervical region of *Caretta caretta* and *Lepidochelys kempii* (Figs. 144-146). In *Dermochelys*, it branches near the head (Fig. 147). All species have vertebral branches from the external jugular draining the cervical structures.

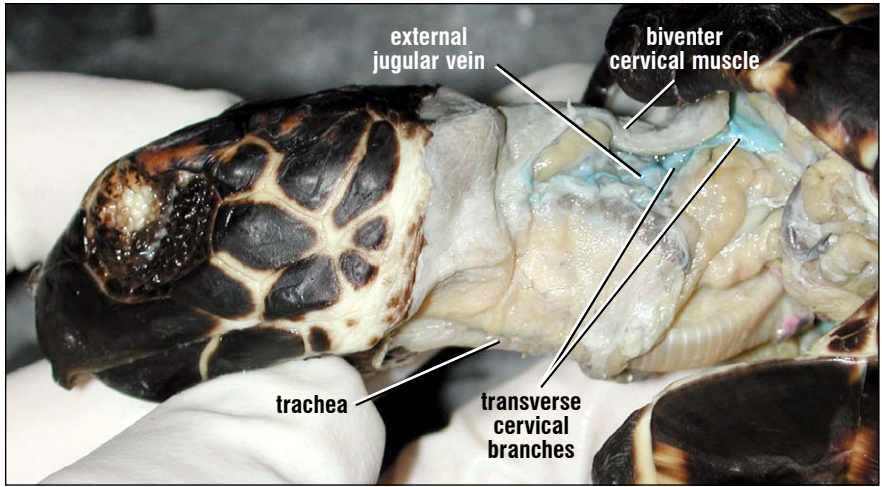
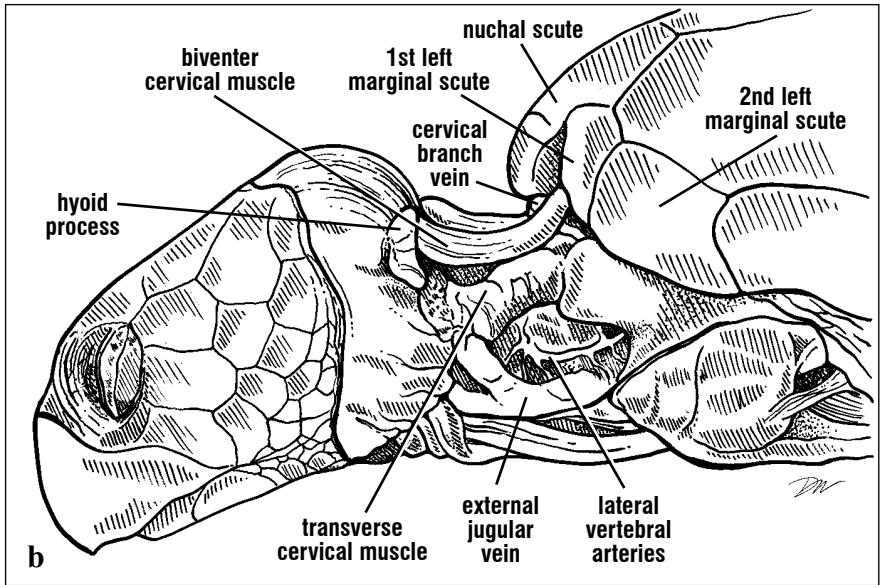
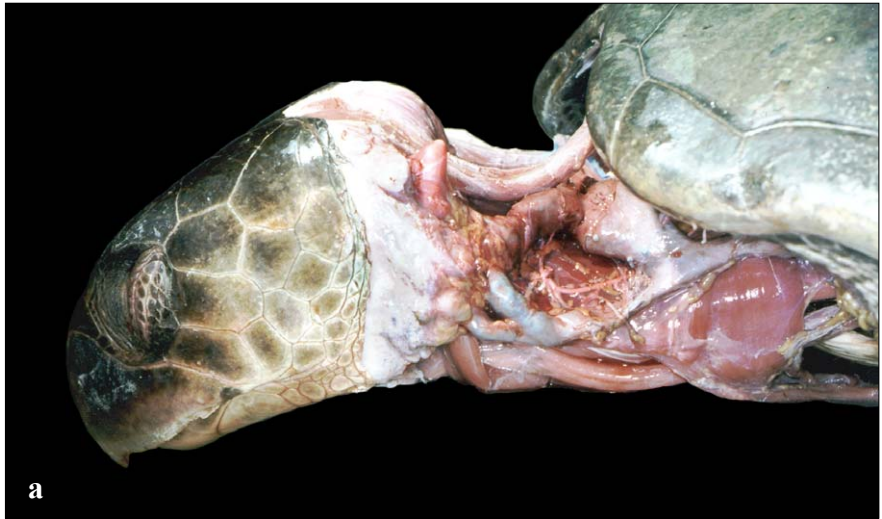
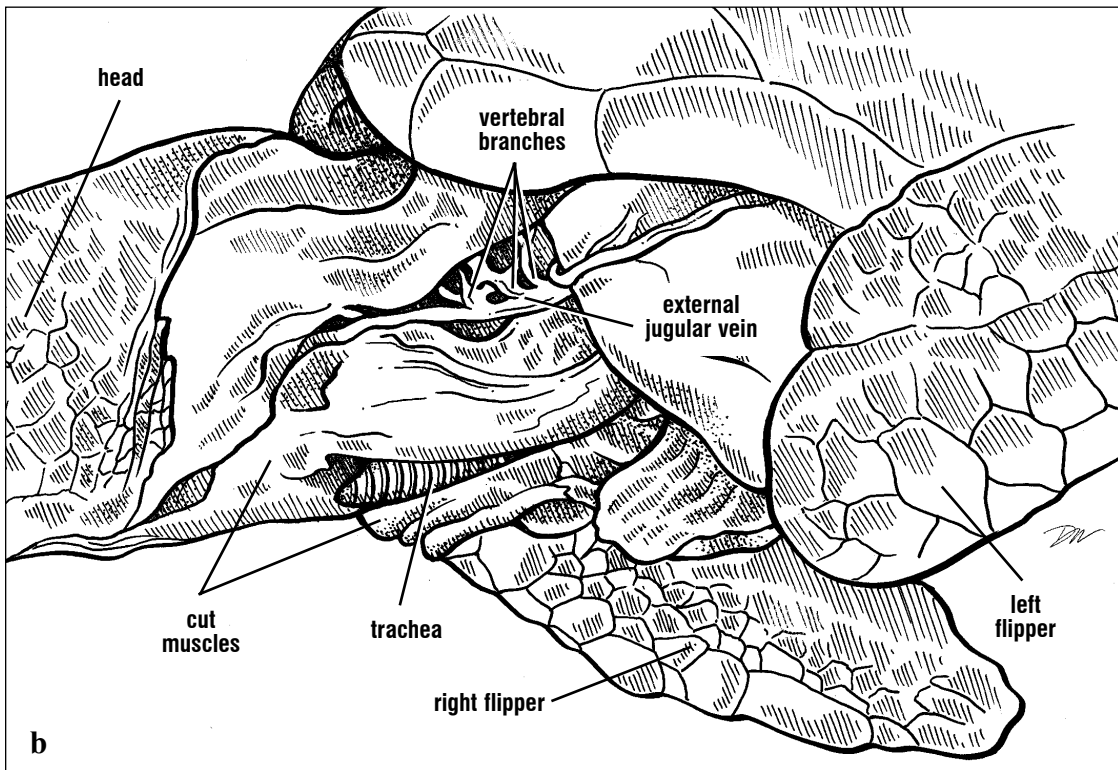
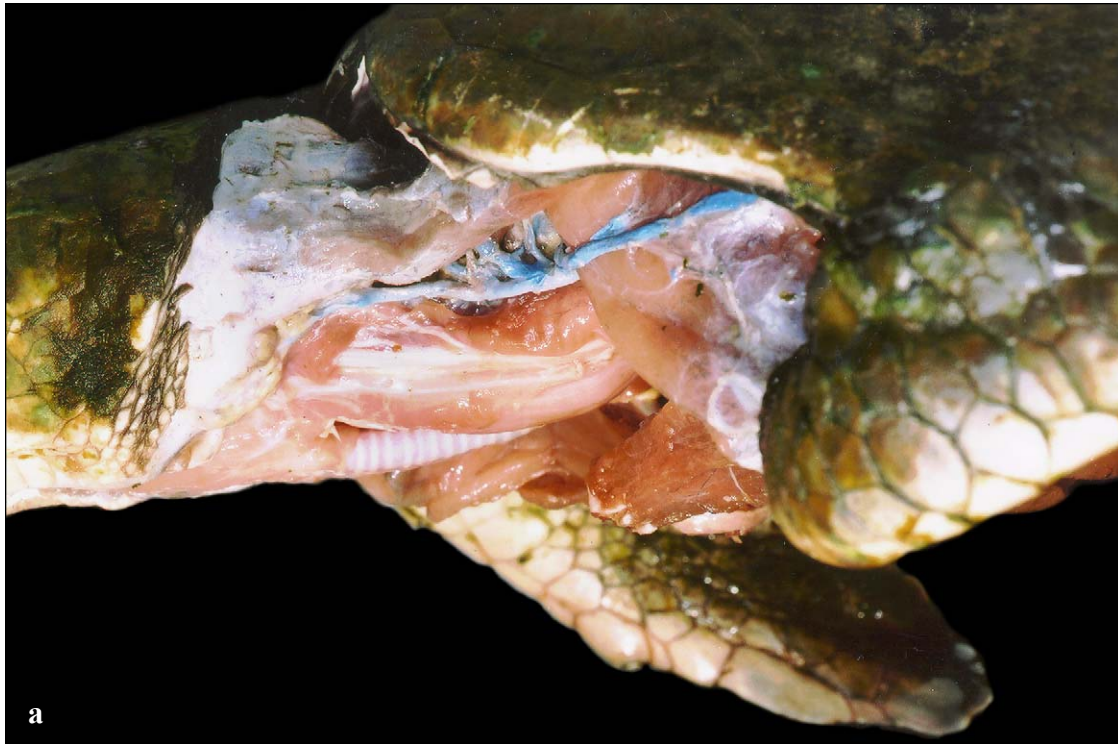

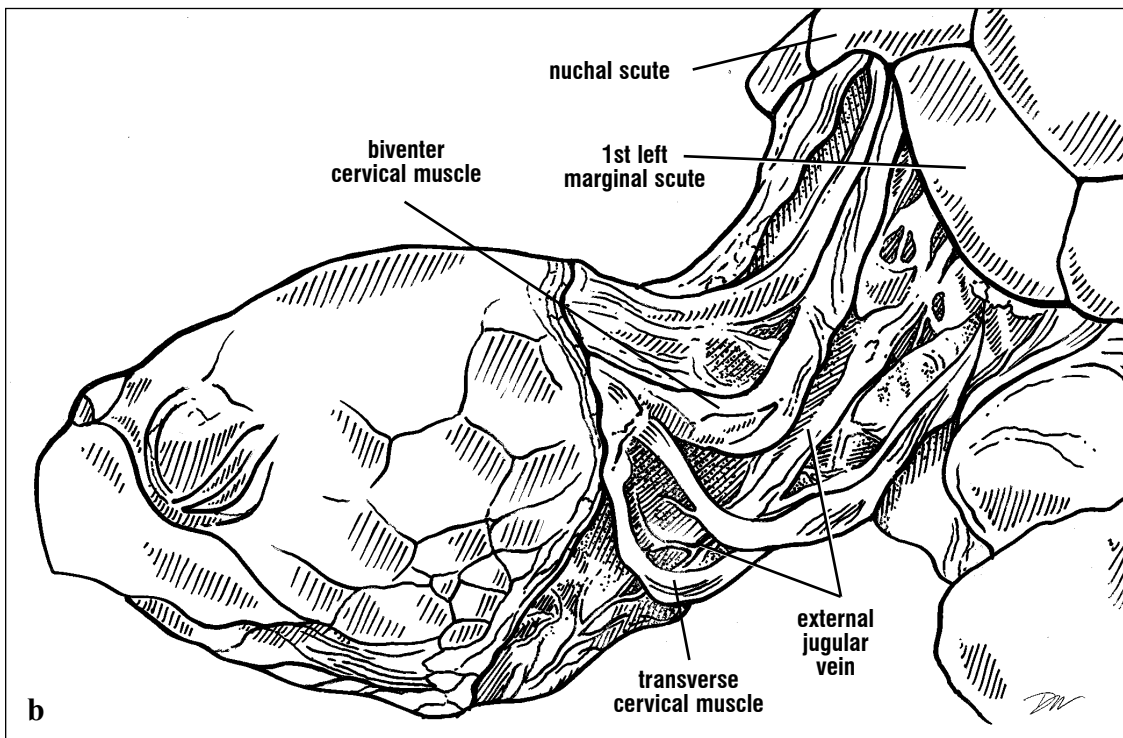
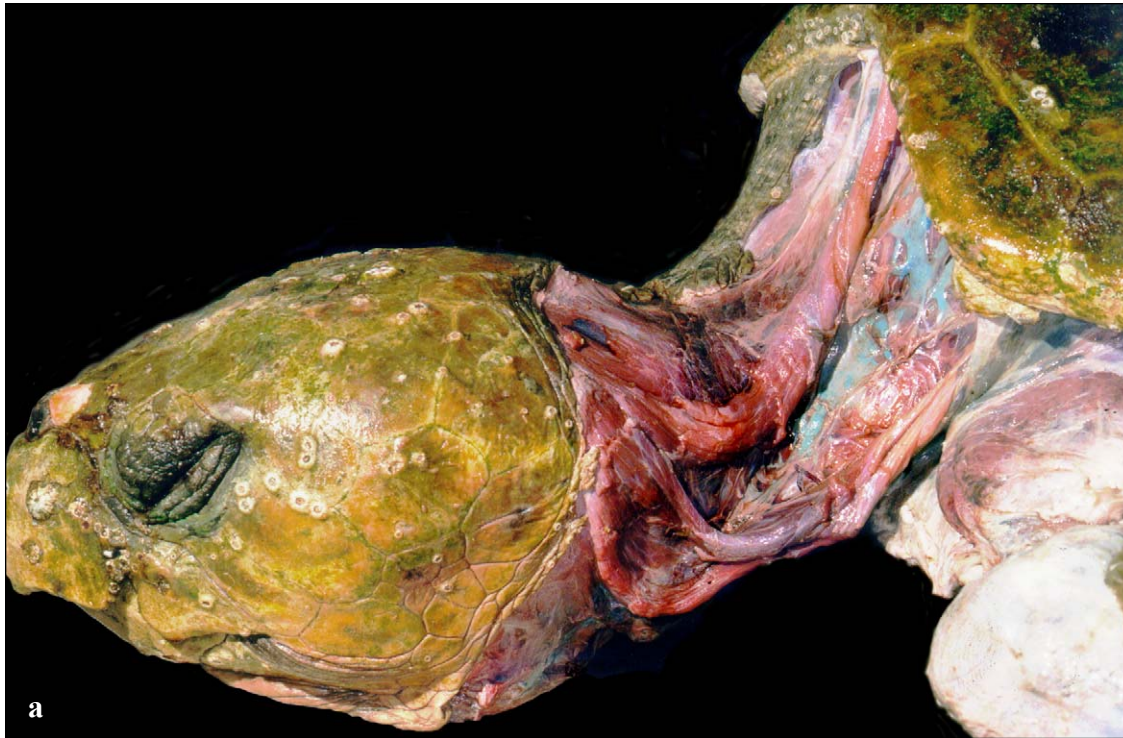
Fig. 149. Lateral view of hawkbill cervical circulation. The external jugular vein in hawkbills has few branches along most of its length. The vessel branches proximally to receive vertebral branches (near the nuchal scute) and ventrally, draining the ventrolateral neck muscles. Ventral cervical arteries are exposed adjacent to the trachea near the plastron.



Figs. 150a and 150b. The external jugular, injected with latex to provide contrast, is very large in this Kemp's ridley. After removing the connective tissue, the external jugular dropped to a more ventral position than would be found in life. Lateral vertebral arteries from the carotid are seen in this deep dissection.



Figs. 151a and 151b. *This lateral view of a Kemp's ridley shows the many vertebral branches off the external jugular going to the deep cervical musculature.*



Figs. 152a and 152b. This lateral dissection of a loggerhead's external jugular shows the extensive branching that is typical of this species. The transverse cervical muscle has been split along its length to expose the vein. Both the muscles and veins are displaced ventrally because their supporting connective tissues have been removed.

The internal jugular vein is smaller in diameter than the external jugular and is found more deeply adjacent to the longus colli muscles. It receives

multiple branches from the esophagus (**esophageal veins**) before it drains into the precava (Fig. 153).

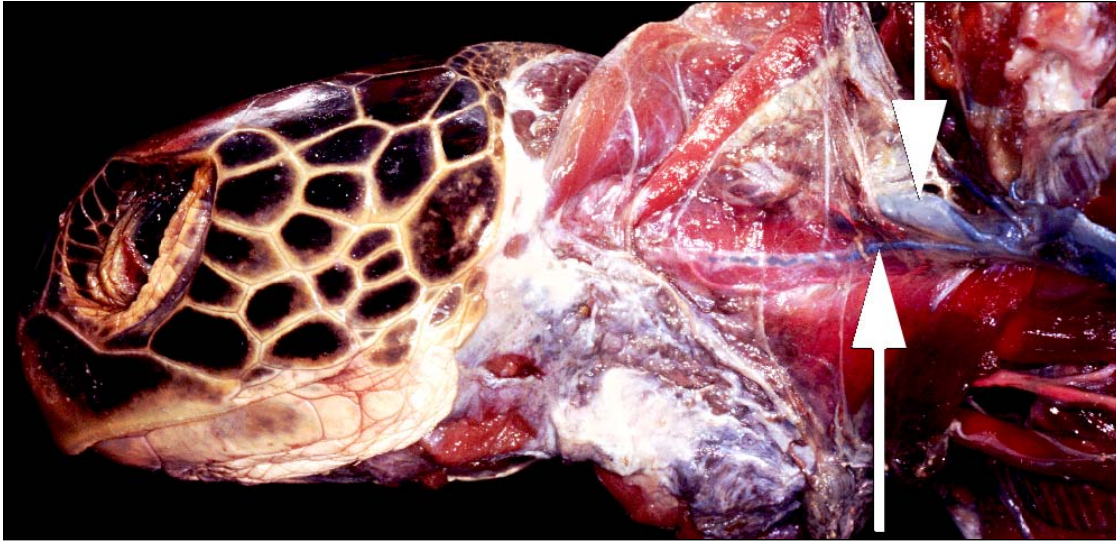
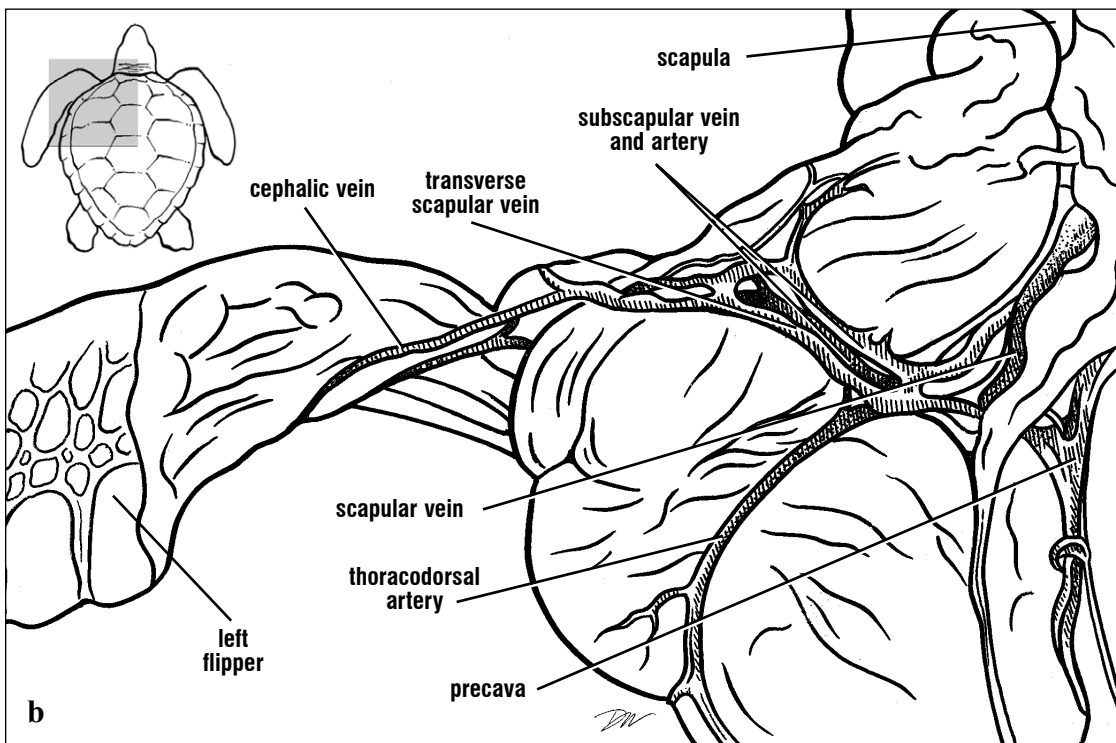
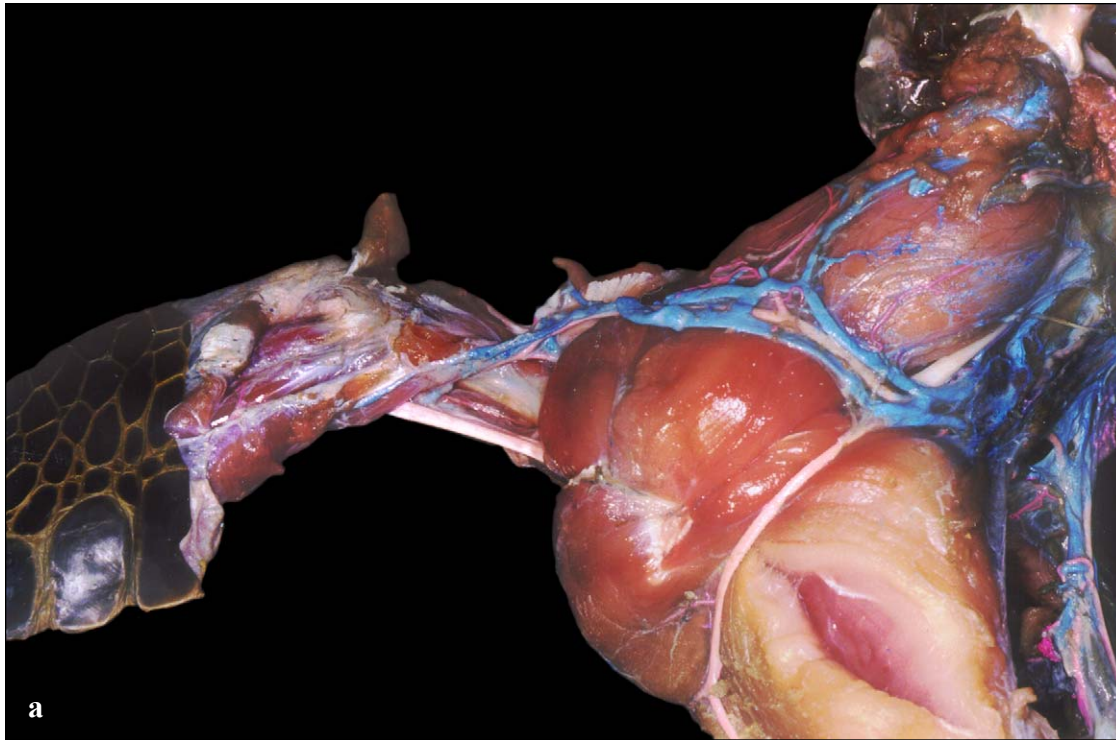


Fig. 153. *The internal and external jugular veins from the precava are exposed in this dissection of a green turtle. The external jugular vein (downward pointing arrow) is mostly covered by the cut neck musculature which has been reflected dorsally. The internal jugular (upward pointing arrow) is partially injected with latex. The internal jugular vein is usually accompanied by the vagus nerve, however it is not distinct in this photo.*



Figs. 154a and 154b. Venous and arterial branches of the posterior aspect of the flipper. The cephalic vein from the flipper drains into the transverse scapular vein along the scapular musculature, then to the scapular vein, which then joins the precava. The thoracodorsal artery is a branch from the subclavian or the brachial in most turtles.

Venous return from the posterior body is by both direct routes (to the postcava and the left hepatic vein) and indirect routes (via the **renal portal** and **hepatic portal** systems). Portal systems are those that start and end in capillaries. The renal portal system consists of veins draining into the **postcava**, **abdominal**, **renal portal**, and **external iliac veins**. The hepatic portal system includes the veins draining into the **hepatic portal**, **common mesenteric**, **mesenteric**, and **duodenal veins**. These will be discussed separately.

The postcava runs anteriorly from the capillaries of kidneys through the right lobe of the liver (Fig. 132). It emerges from the right lobe of the liver

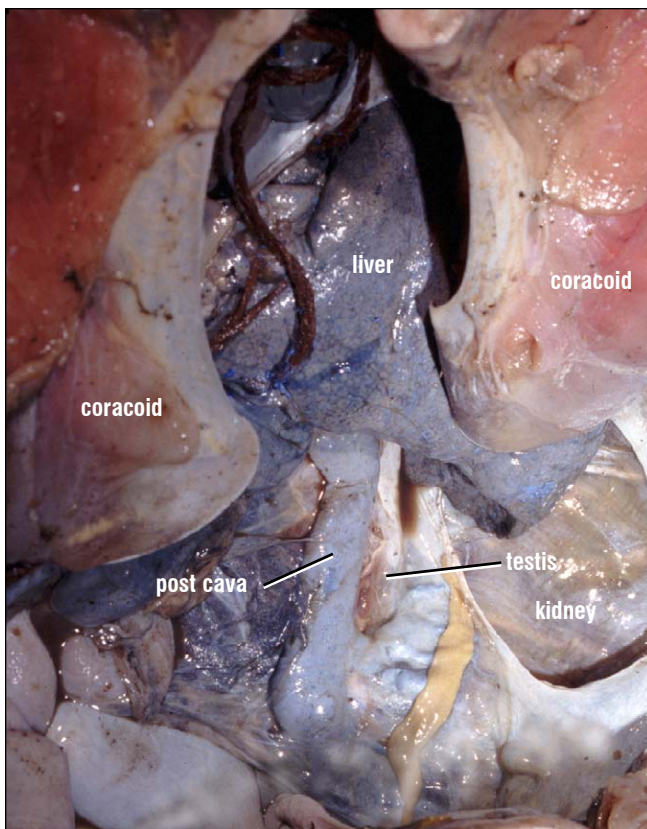
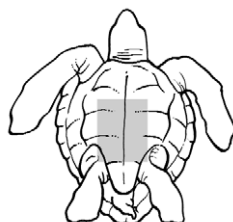
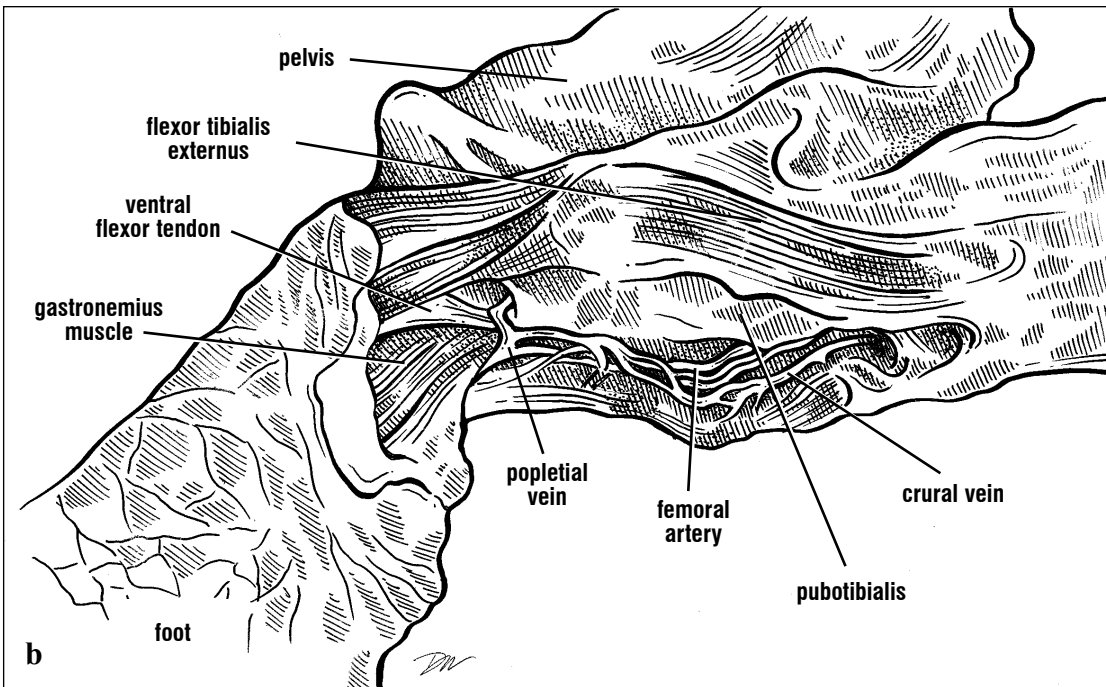
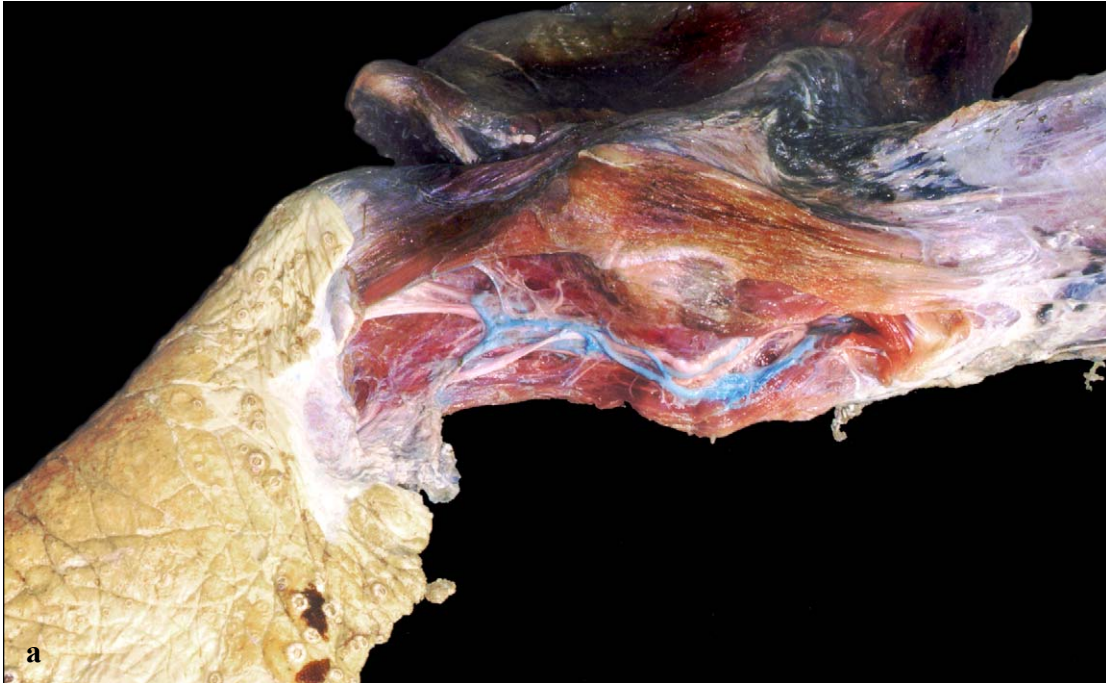


Fig. 155. *Ventral view of the postcava. The postcava emerges from the liver and passes to the kidneys. Blood is drained from the kidneys and posterior body to the liver.*

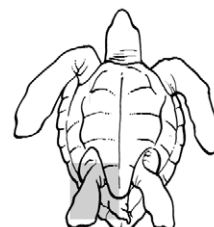


and enters the right side of the sinus venosus. Posteriorly, the postcava receives multiple pairs of **renal veins** from the ventral surface of the kidneys. **Gonadal veins** also pass from gonads, through the kidneys, and to the postcava. Branches from the **iliac veins** drain the pelvic musculature, and the **costal veins** from the carapace occasionally drain into the postcava. Anteriorly it receives multiple **hepatic veins** from throughout the liver. The postcava is part of the renal portal system. The **left hepatic vein** drains blood through the liver and from the paired **abdominal veins**, (Fig. 132) which are located just anterior to the pelvis and in the peritoneum. There is usually a **transverse abdominal vein** connecting the abdominal veins. Blood can flow in either direction through this vein. The abdominal veins receive **pectoral veins** (Fig. 127) descending from the pectoral muscles. **Pericardial veins** usually enter the abdominals near the pectoral veins and posterior to these, a pair of vesicular veins enters from the bladder. The abdominals extend along the dorsal pelvic musculature and receive **pelvic veins** from the left and right sides.

In the hind limb, **crural veins** extend from the medial to the posterior thigh and shank. Crural branches from the shank, the **tibial** and **popliteal veins**, plus the **femoral veins** (from the dorsolateral thigh and shank; Figs. 132 and 156) drain to enter the abdominals, usually just posterior to the pelvic veins. Paired **lipoidal veins** from the left and right inguinal fat pads, enter the abdominal veins from near the crural veins. **External iliac veins** drain into the abdominals at or near the junction of the femoral and crural veins with the abdominal veins. The **epigastric vein** (Fig. 157) extends from the marginocostal vein on each side and travels with the epigastric artery along the posterolateral margin of the carapace. It runs along the upper thigh, and drains into the external iliac vein.



Figs. 156a and 156b. The right hind limb of this loggerhead shows the positions of the femoral artery, crural, and popliteal veins. These arteries and veins travel with the sciatic nerve.



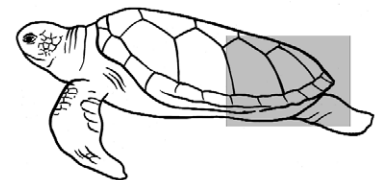
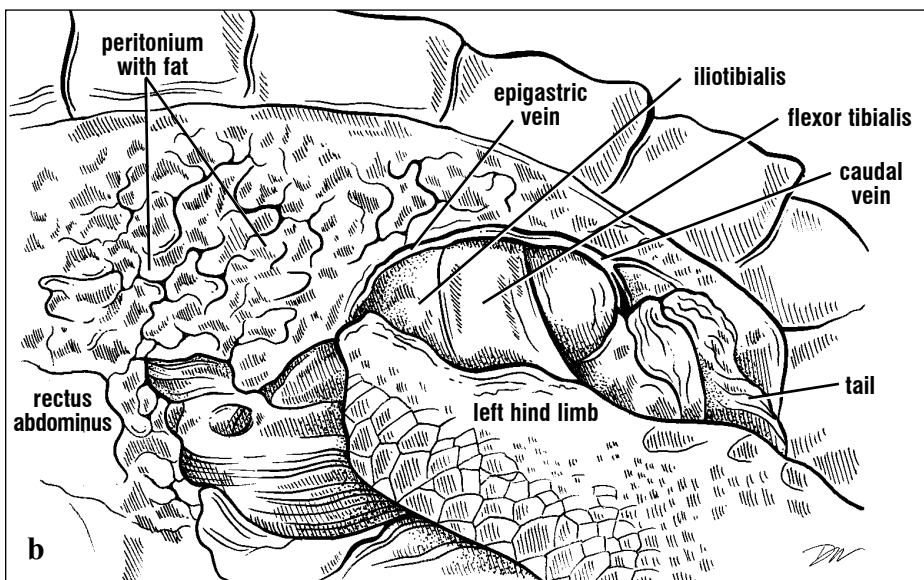
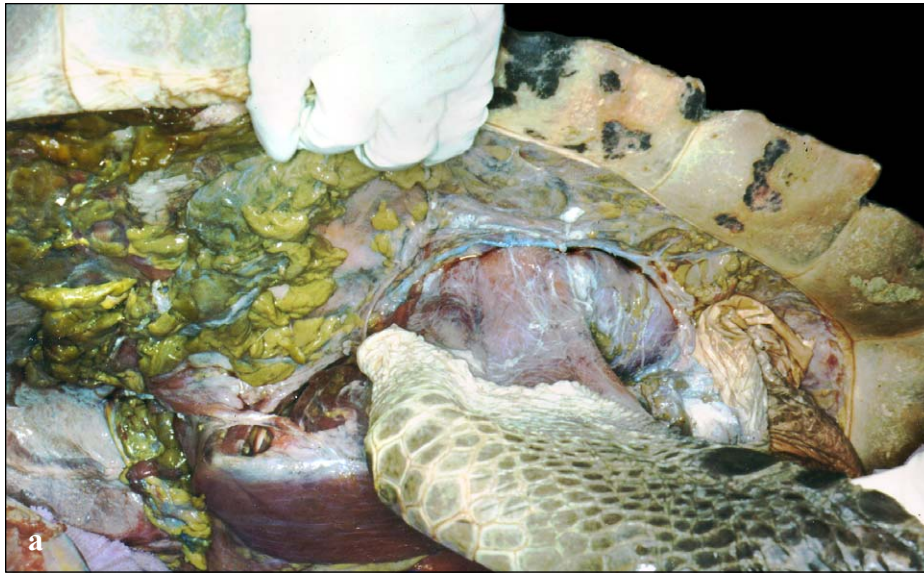


Fig. 157. Lateral and posterior view. The epigastric vein travels dorsally to the dorsal hind leg extensors (*iliotalialis*) and flexors (*flexor tibialis*). This vein is medial to the marginal scutes and just ventral to the dorsal fat layer. It receives drainage from into the caudal veins just dorsal to the tail.

The paired **renal portal veins** receive the **ischialic veins** from the posterior hip muscles. The **caudal veins** (Fig. 157) extend along the lateral tail and receive the **cloacal veins**, medially from the cloaca and rectum. The caudal veins drain into the ischiadic veins, as well as the epigastric vein in sea turtles. The renal portal vein also receives drainage from the narrow **vertebral veins**, which are found lateral to the vertebral column and enter the kidneys anteriorly and dorsally. The vertebrals receive costal veins from the shell, which are connected laterally with the **marginocostal vein** (Fig. 132). From the cloaca,

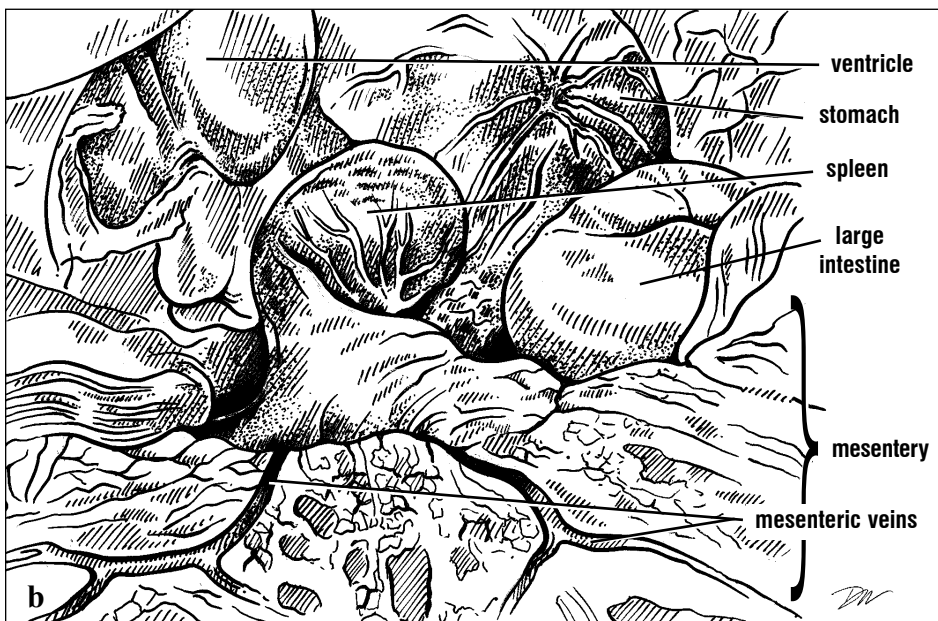
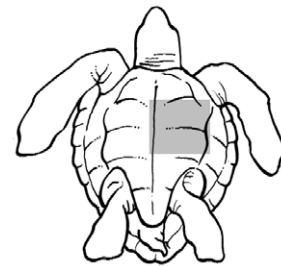
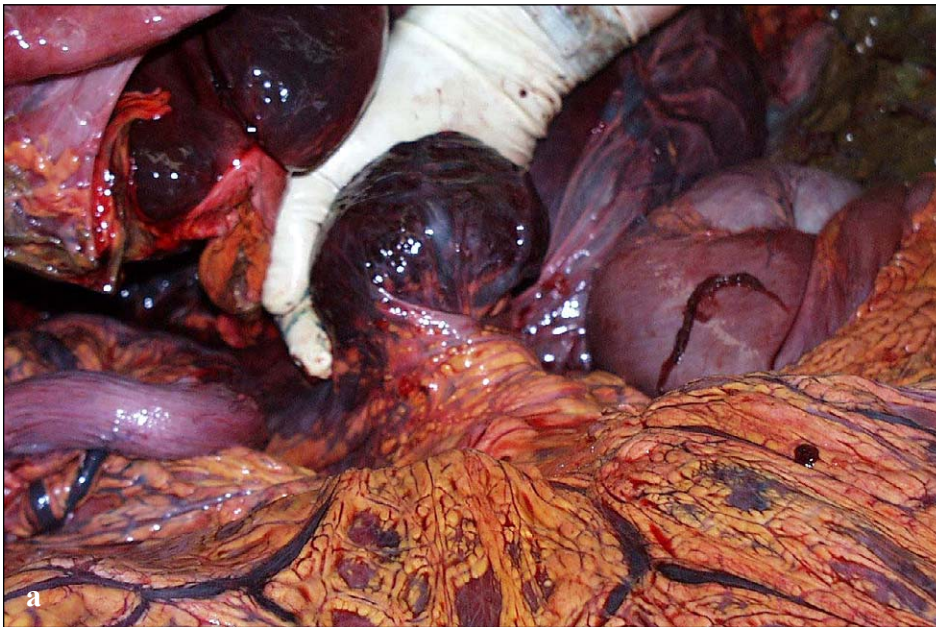
bladder, rectum, and in males, the penis, blood drains to the **hypogastric vein**, which enters the kidneys posteriorly and ventrally. The renal portal veins drain from the dorsal kidney capillaries into the external iliacs at the level of the epigastric veins, or into the posterior extent of the abdominal veins.

The **hepatic portal** vein receives drainage from the abdominal veins. It passes dorsally between the right and left lobes of the liver. Anteriorly, it receives several branches from the stomach, the **gastric veins**, with several branches forming the **anterior**

pancreatic veins (along the left half of the pancreas), the **posterior pancreatic veins** (from the right half of the pancreas), and the long **duodenal vein** (Figs. 134 and 136). The spleen, found near the posterior end of the pancreas, is highly vascular and is drained by several **splenic veins** to the hepatic portal vein (Fig. 158).

More posteriorly, multiple **mesenteric veins** travel

with the mesenteric arteries radiating from the small intestines and through the fan-shaped mesentery (Fig. 158). The mesenteric veins converge on the **common mesenteric vein**, which drains into the hepatic portal vein. The **inferior mesenteric vein** drains branches from the large intestine up to the iliocaecal junction (where the large intestine meets the ileum), then itself enters the common mesenteric vein leading to the hepatic portal vein.



Figs. 158a and 158b. *The spleen is exposed to the left of the stomach and distal to the pancreas (covered by mesentery). Several splenic veins cover the spleen's surface. Mesenteric veins, in the fat-rich mesentery, drain blood returning from the small intestines.*

Circulation Through the Heart. The route blood takes through the heart differs depending upon whether blood is shunted toward the lungs and the body, or primarily toward the body. Unlike mammalian cardiopulmonary systems, the pulmonary and systemic blood flows are not always separate. The extent of separation between the pulmonary and systemic circuits of flow differs somewhat between *Dermochelys* and the cheloniids. There is a nearly complete separation of systemic (body) and pulmonary (lung) circulation in the leatherback heart, but the intra-cardiac flow is less well separated into pulmonary and systemic outflows in the cheloniid species.

Studies of turtles generally show that whether blood is shunted to or away from the lungs is a function of arterial blood gas levels. Venous blood returning from the head, limbs, and body enters the sinus venosus, then flows to the right atrium. From the right atrium, blood enters the ventricle where it flows along at least two possible routes. The diagram below (Fig. 159) summarizes the route blood takes through the heart. Blood from the kidneys returns to the left atrium via the pulmonary veins. It then flows from the left atrium to the ventricle and usually out through the aortas to the body.

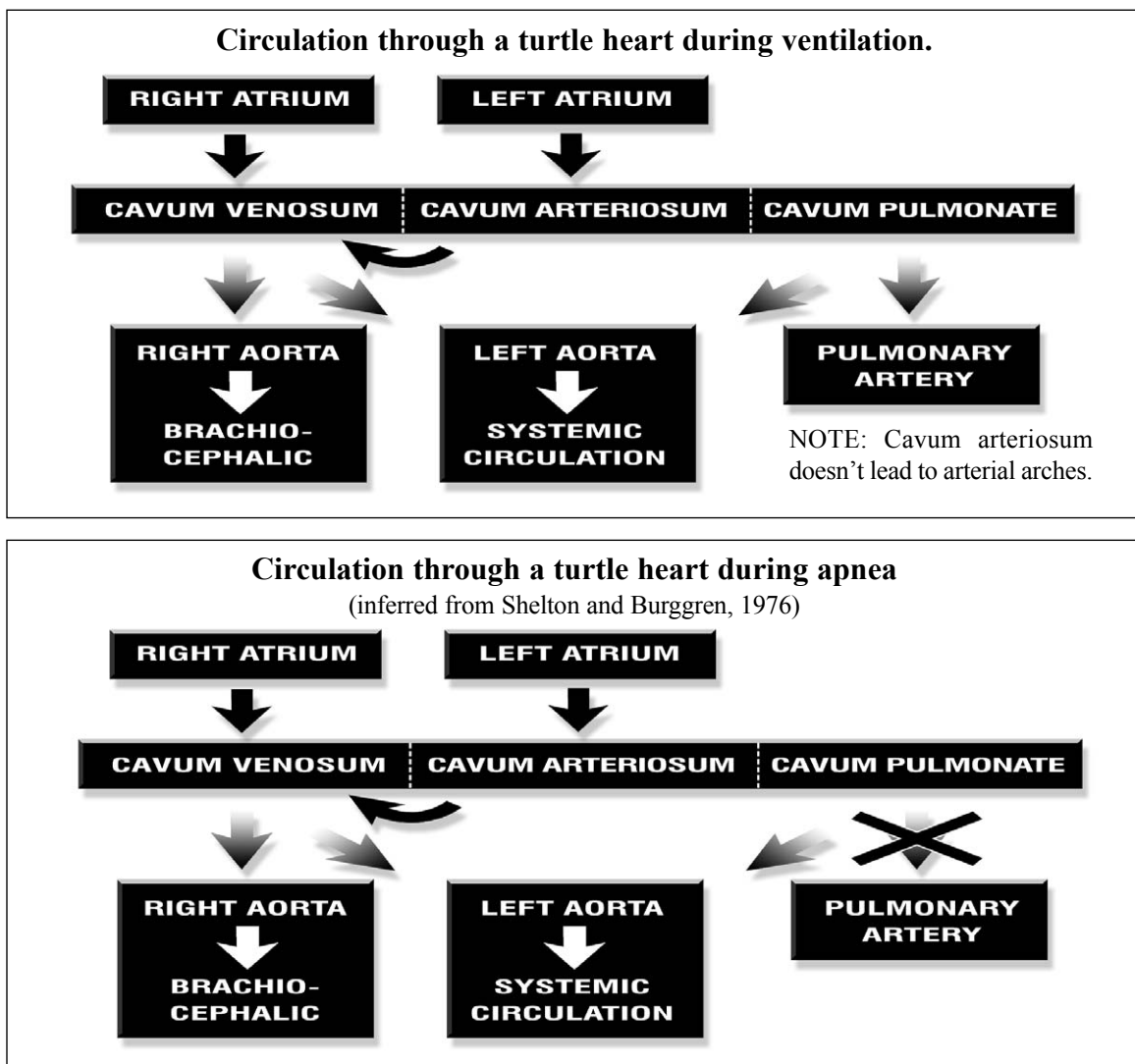


Fig. 159. Circulation through a turtle heart during breathing and during breath-holding (apnea).

Lungs and Airways

The **pulmonary system** is composed of the **glottis**, **trachea**, a **bronchus** to each lung, and the left and right **lungs**. The airways begin at the glottis, which is located in the middle to posterior portion of the tongue (Fig 160). The glottis and its muscles are supported ventrally by the hyoid apparatus. The glottis opens during air passage and is closed during breath-holding. The glottis leads directly into the trachea, which is supported by complete cartilaginous rings that are usually white, except in decomposing animals or some

turtles with pulmonary disease. The trachea is long and bifurcates into two bronchi dorsal and anterior to the heart. These then enter the anterior part of the lungs next to the pulmonary arteries. The bifurcation begins internally, anterior to the external division to form the bronchi. The bronchi extend for virtually the length of the lungs and have many openings into the complex internal lobes of the lungs (Fig. 161). Unlike the bronchi of mammalian lungs, these openings lead to chambers that are not supported by cartilage. There are no secondary bronchi in sea turtles.

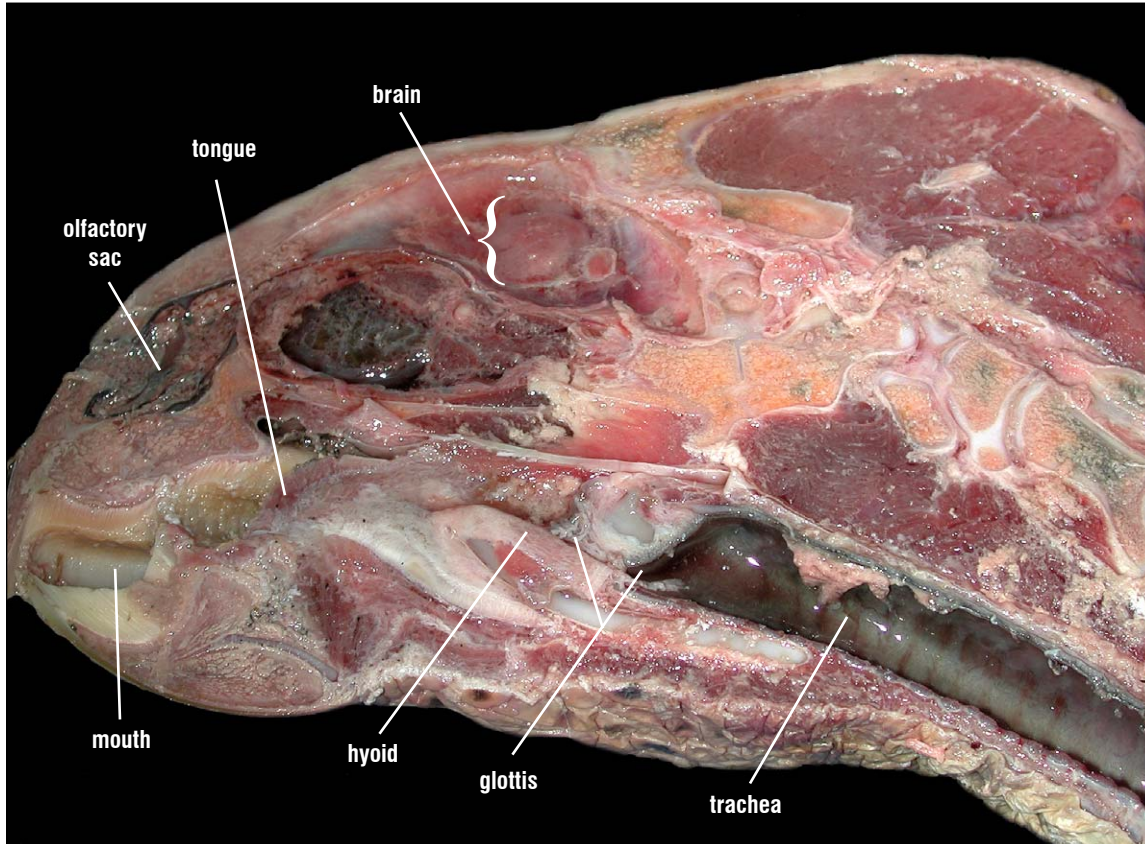


Fig. 160. Parasagittal section of a hawksbill showing the airway. The hyoid apparatus, including both bony and cartilaginous portions, supports the glottis ventrally. The glottis, located between the hyoid and the surface of the tongue, is closed in this dissection. The large tracheal diameter is maintained by cartilaginous rings. The trachea is lined by smooth epithelium.

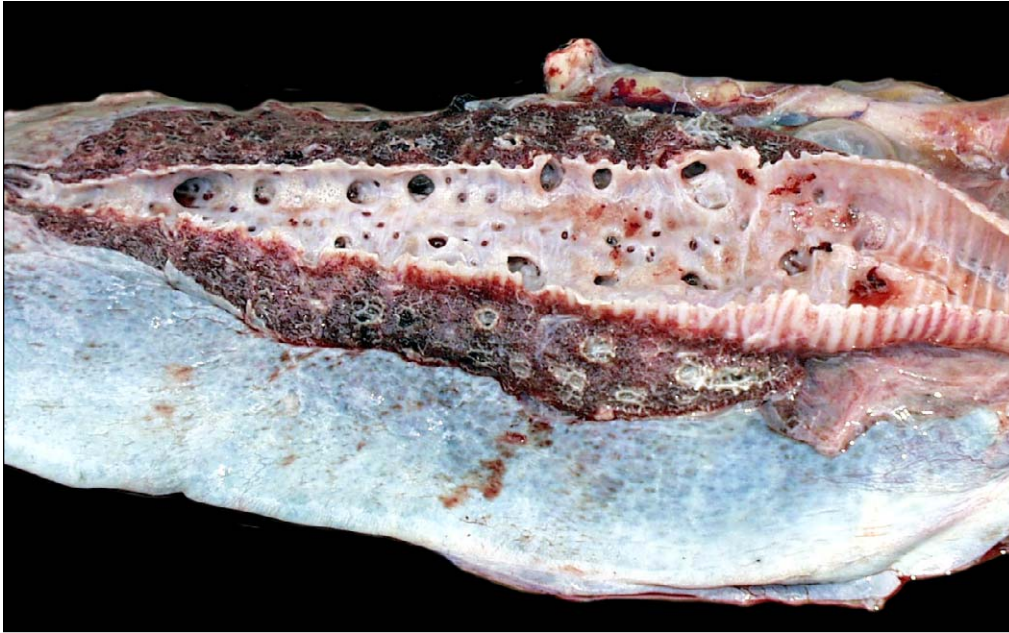


Fig. 161. Longitudinal section through a loggerhead bronchus. The lungs of cheloniids are spongy in construction and red in color. They also have a large surface area but are not as densely constructed as the lungs of leatherbacks. The large-bore trachea has many openings to the chambers of the lung along its length. These openings are not supported by cartilage once they leave the bronchus. The unsupported airways extend to the air exchange surfaces called faveoli and ascini. The trachea and bronchus are supported by cartilage, which resists collapse during ventilation and diving.

The lungs are located dorsally and are attached dorsally to the carapace and vertebral column. In some species, (e.g., *L. kempii* and *C. caretta*) the lungs are more closely attached to the vertebral column than in other species. Ventrally, the left lung is attached to the stomach via the **gastropulmonary ligament**. The right lung is

attached to the right lobe of the liver by the **hepatopulmonary ligament**. Posteriorly, the lungs attach to the peritoneum that overlies the kidneys and adrenal glands and are adjacent to the gonads. The medial border of each lung is firmly attached (Fig. 162) via fibrous connections to dorsolateral surfaces of the vertebral column.




Fig. 162. *CT scan showing the lungs in a Kemp's ridley. This CT shows the position, form, and the extent of the lungs and airways in a living Kemp's ridley turtle. The medial surfaces of the lungs are attached tightly to the vertebral column.*

All sea turtles have multichambered lungs (there are multiple lobes contained within the body of the lung). The lobes are not obvious externally. The

by movements of ventral muscles of the pelvic and pectoral girdles that attach to the plastron, compression of the inguinal region, and rocking of

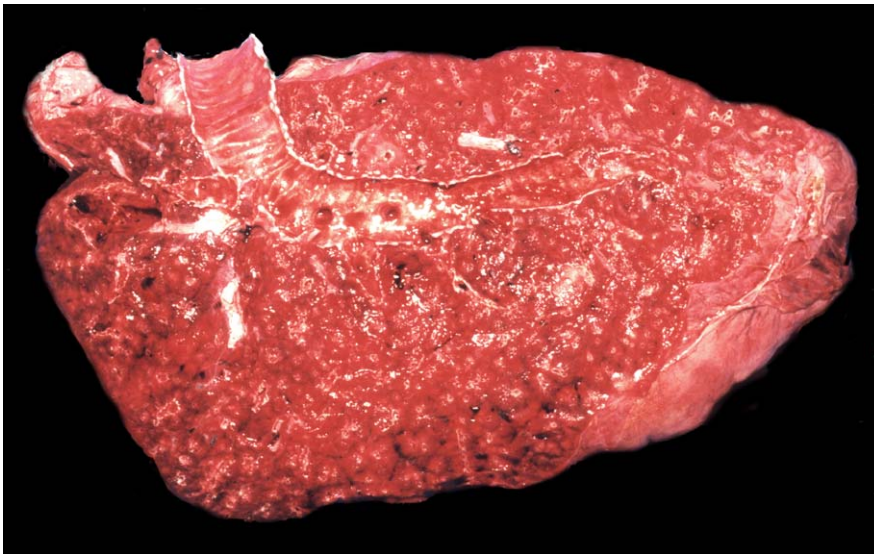

Fig. 163. *Longitudinal section through a leatherback lung. The lungs of leatherbacks are characterized by more dense construction. The high surface area, dense parenchyma, high levels of connective tissue, and extensive blood supply make leatherback lungs particularly spongy and deep red in color.*

lung tissue is spongy and highly elastic (Figs. 161 and 163) in sea turtles.

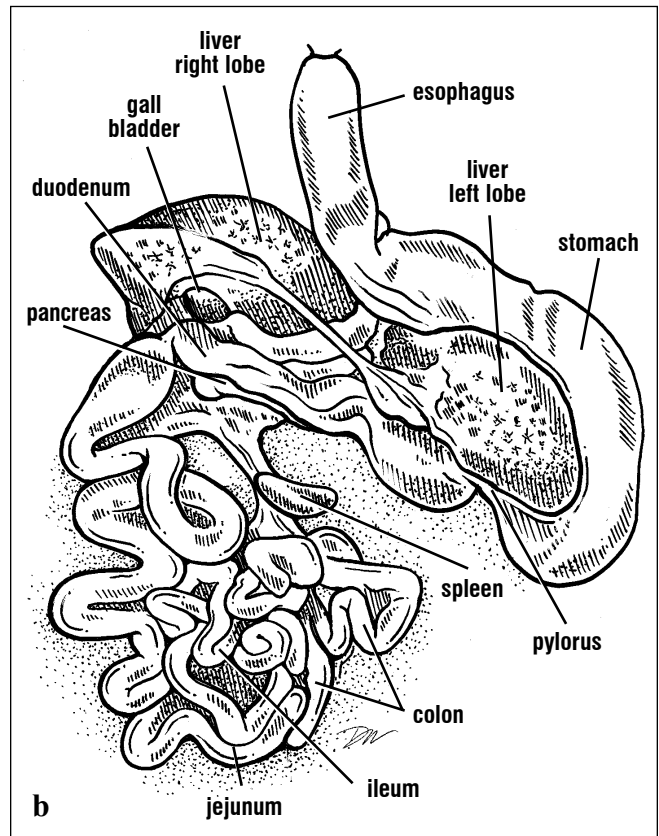
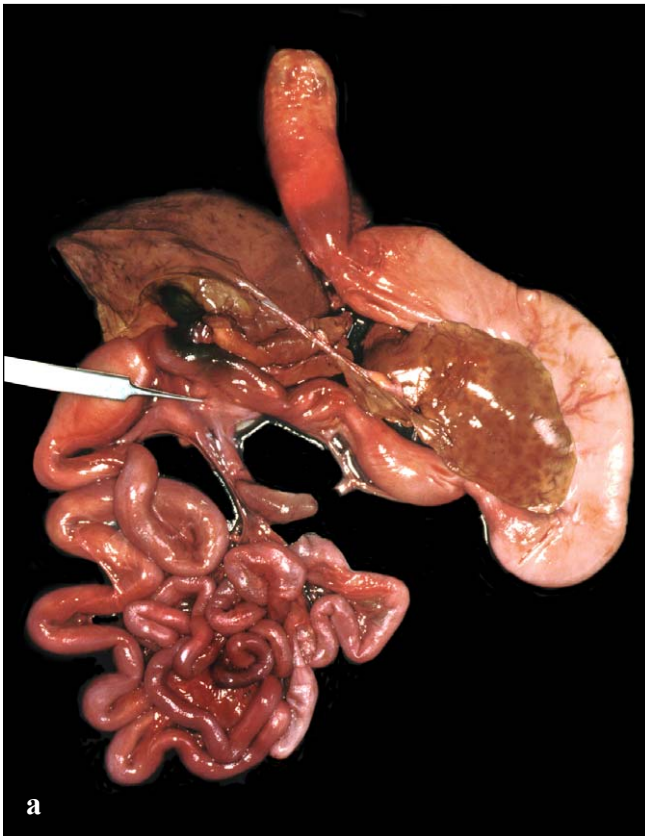
Ventilation of the lungs occurs without the assistance of a diaphragm. Marine turtles ventilate

the shoulder muscle masses to change the pressure within the pleuroperitoneal cavity. Sea turtles have a large tidal volume. Under normal circumstances, they breath-hold until blood oxygen levels drop to low levels.

Gastrointestinal Tract

The **gastrointestinal tract** (GI tract or gut) extends from the mouth to the cloaca (Fig. 164). It is demarked by structural and functional divisions. The **mouth** captures and processes food. The **esophagus** conveys food to the stomach and expels excess water. It also works with the tongue in swallowing. The **stomach** starts the chemical and physical process of digestion. In the **small intestines**, digestive enzymes are added to food to

break down proteins and complex carbohydrates. The small intestines are regionally specialized to absorb amino acids, carbohydrates, sugars, water, fatty acids, and minerals (particularly calcium and phosphorus). The **large intestine** (colon) typically reclaims water. The length of the gut is somewhat related to diet. It is proportionally longer in green and leatherback turtles than in loggerheads, ridleys, and hawksbills.



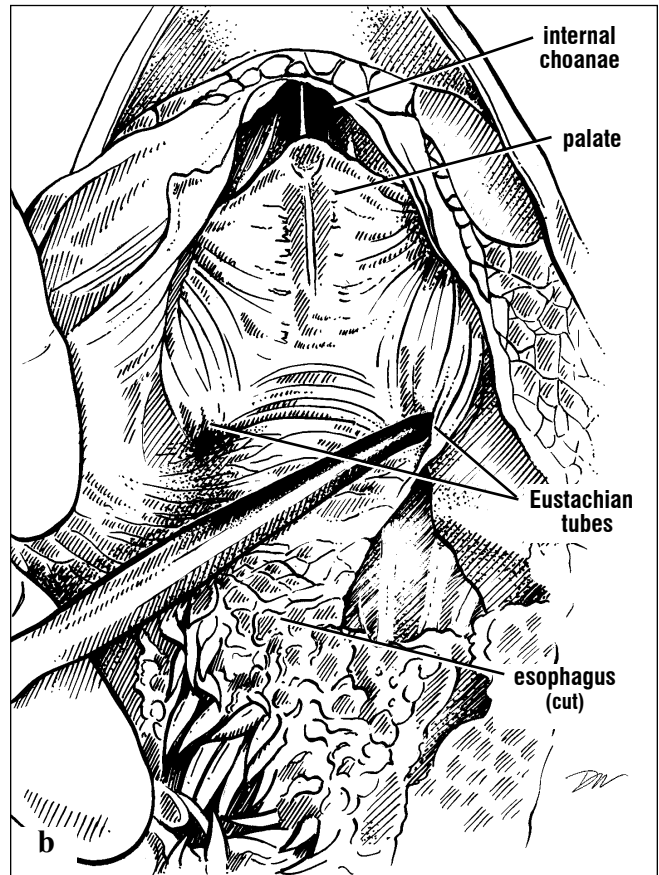
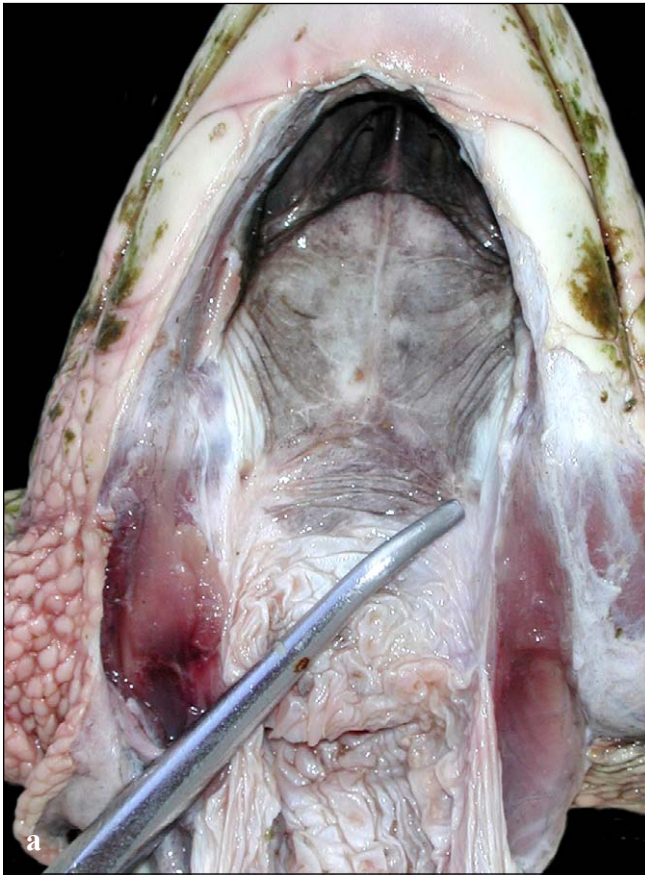
Figs. 164a and 164b. *The gastrointestinal tract with digestive glands and the spleen. The GI tract from the esophagus to the rectum from a Kemp's ridley turtle shows the different regions as well as the associated digestive glands, the liver and pancreas. The gall bladder stores bile, produced*

by the liver, and releases it through the common bile duct when food enters the duodenum. The spleen, located at the distal end of the pancreas, is not a digestive gland; rather it is a lymphoid organ in turtles involved in immunological activity.

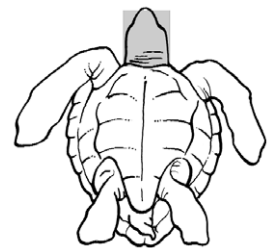
GASTROINTESTINAL ANATOMY

The mouth includes several GI, respiratory, and ear structures: the **mandibles** and the **pharynx** includes the **palate**, **esophagus**, **glottis**, **Eustachian tubes**, and **internal choanae** (Fig. 165). For convenience, these structures will be described together here. The glottis and internal choanae are part of the respiratory system and the Eustachian tube connects the pharynx with the middle ear cavity. The tongue is fixed to the floor of the mouth and is not protrusible. The glottis is located on the middle part of the tongue (see Sense

Organs, Fig. 209), just posterior and ventral to the internal choanae (internal nares); it acts as a valve to open and close the airway. The esophagus starts at the back of the tongue; it is a muscular tube that leads to the stomach. It passes slightly dorsal and to the right of the trachea. The Eustachian tubes (one on each side), are found in the posterolateral aspects of the mouth, medial to the jaw joint; they function in maintaining normal pressure in the middle ear (Fig. 165).

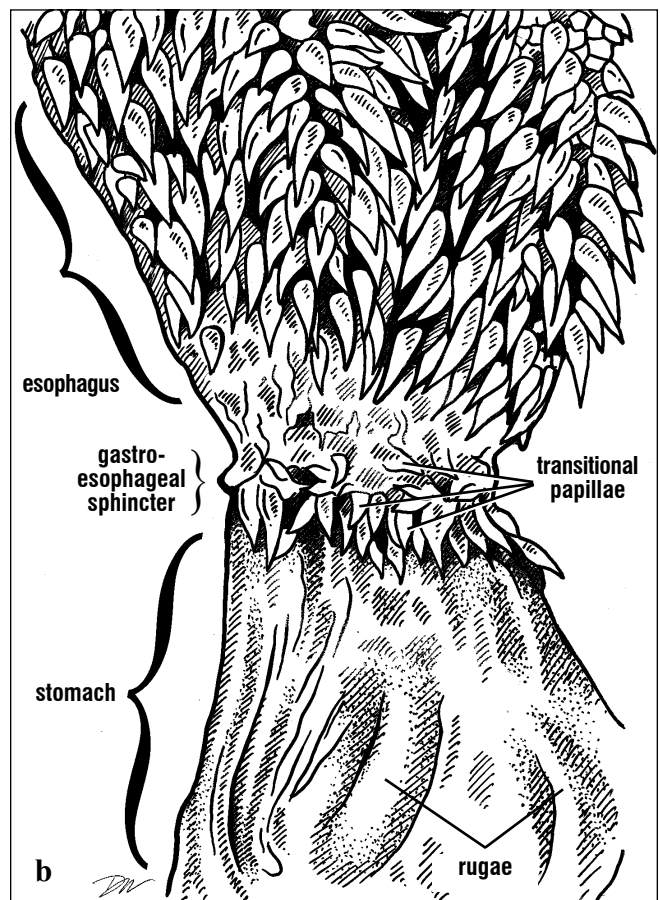
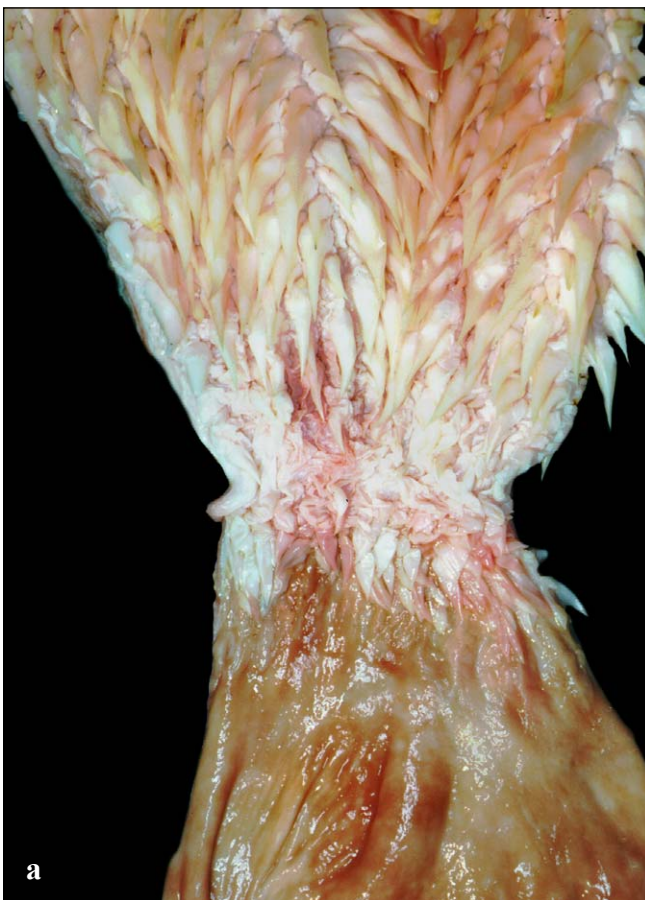

Figs. 165a and 165b. Ventral view of the palate with the tongue and hyoid apparatus cut away. The roof of the mouth has internal choanae (internal nares) that open above the glottis (removed in this picture). In the posterior lateral parts of the palate, near the jaw joint, are the openings to the Eustachian tubes, which lead to the middle ear cavity.



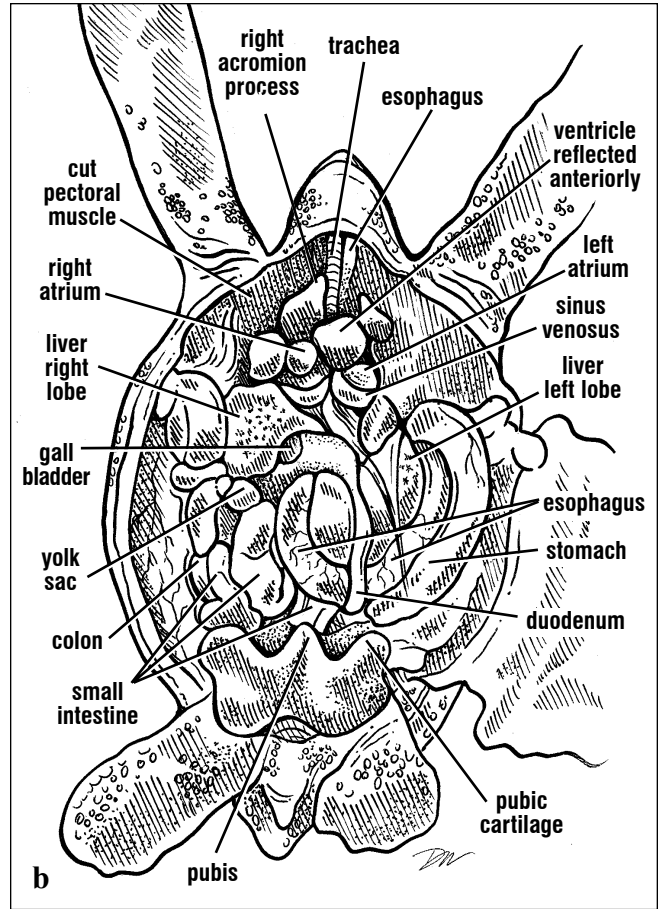
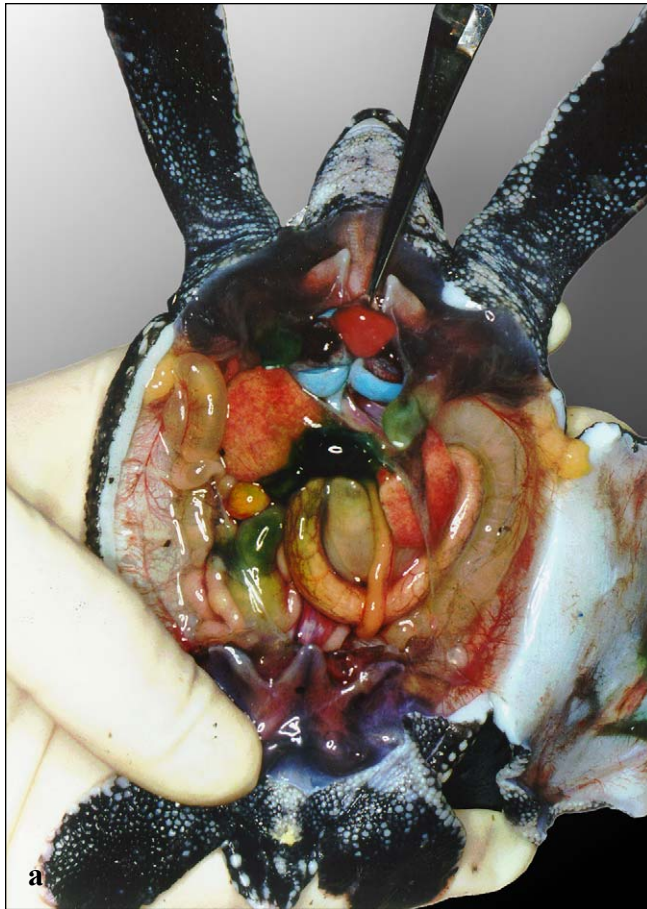The esophagus (Fig. 166) is lined with **papillae** that are sharp and keratinized; they point inward towards the stomach. The papillae end where the esophagus joins the stomach (Fig. 166). The papillae are presumed to trap food while excess water is expelled prior to swallowing. In Atlantic green turtles, the esophagus enters the stomach in a smooth transition. However, in Pacific green turtles, there is a muscular specialization at the base of the esophagus called a **crop**. Its function

is unclear. In cheloniids, the esophagus descends to a position just inside the plastron and bends to the left in an S-shaped curve to join the stomach. In *Dermochelys*, the esophagus is exceptionally long and extends almost half the length of the body before looping to the left, and returning anteriorly almost to the level of the axilla. There, the esophagus bends left again and joins the stomach (Fig. 167).



Figs. 166a and 166b. The esophagus and anterior stomach lining. The papillae that line the esophagus are keratinized for most of the length of the esophagus. They end abruptly; several flat, transitional papillae, lacking keratin line the

esophageal wall at the level of the gastroesophageal sphincter. Posterior to this sphincter, the stomach lining is very smooth and has no papillae.



Figs. 167a and 167b. Ventral view of a leatherback hatchling's viscera and heart. This dissection of a leatherback posthatchling shows the extremely long esophagus, large stomach, and small intestines. On the animal's right is the remaining yolk sac. The yolk sac can persist well after the time that the animal has begun feeding.

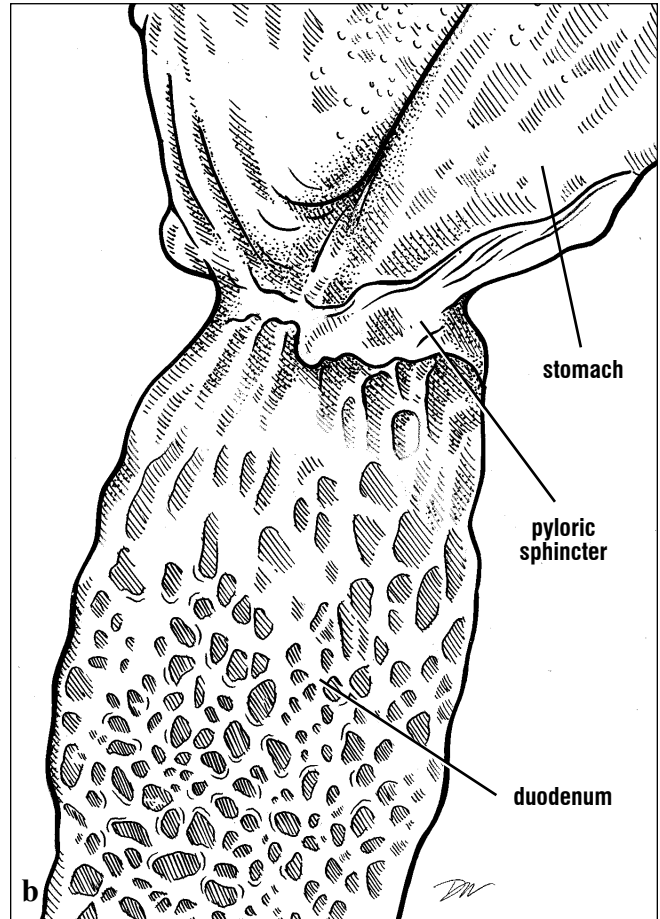
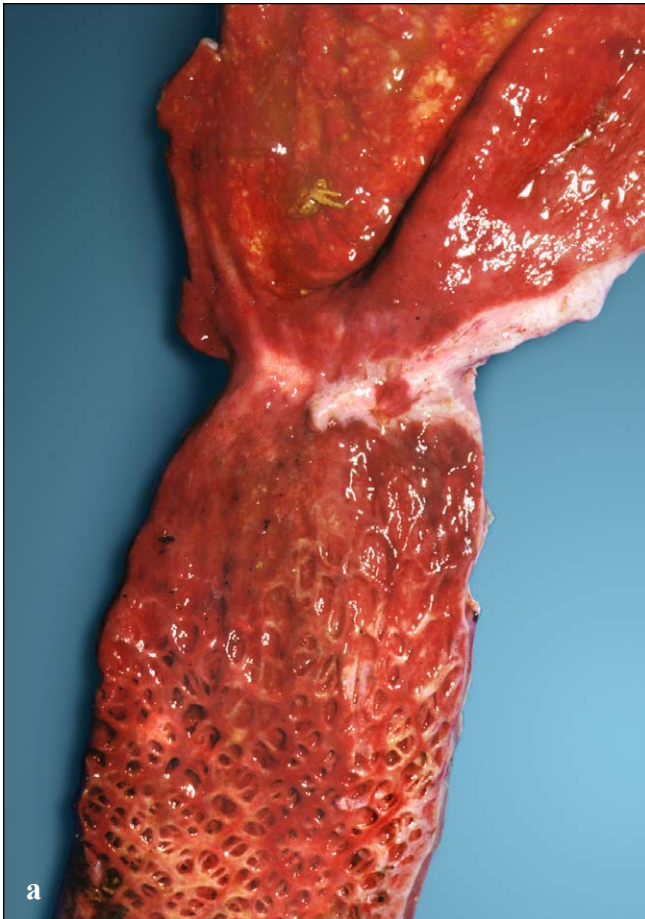
In this animal, the coracoid processes were cut away and the acromion processes reflected anteriorly to provide a clear view of the heart and liver. The ventricle is pushed anteriorly exposing the sinus venosus, which was injected with latex to provide contrast.

The **stomach** is on the animals left side and curves around the more medially located liver and pericardium. It is attached to the liver's left lobe by a **gastrohepatic ligament** and the left lung by a **gastropulmonary ligament**. The stomach is smooth-walled along its length. It ends in a short muscular region, the **pylorus** (= **pyloric sphincter** or **valve**). The pylorus is usually constricted and the intestinal lining on the **duodenal** side of the sphincter differs from that of the stomach (Fig. 169).

The pancreas runs distally along the duodenum from the pylorus to just past the **common bile duct** (Fig. 170). Both the pancreas and the common bile duct (from the gall bladder) deliver digestive enzymes to the duodenum. The common bile duct enters the duodenum via a small papilla, the **ampulla of Vater**, on the duodenum's internal surface. Its location can be identified from the green bile stain (Figs. 170-171). The pancreatic duct (not shown) is difficult to locate in all but the largest turtles; it enters the duodenum near or in

common with the common bile duct. The duodenum's lining is textured and, in some species, it is "honey-combed" in appearance (Fig. 171). This textured lining is associated with increased surface area and is well-developed in

histological examination for the functional characteristics of the tissues. The transition from ileum to **colon** is clear. The ileum ends in a muscular sphincter, the **ileo-caecal valve**. The proximal end of the colon is a **caecum** (pouch) that



Figs. 169a and 169b. Linings of the stomach and duodenum. The stomach and duodenum are separated by a short muscular sphincter, the pylorus. While stomach lining is generally smooth,

that of the duodenum is often textured. In the leatherback and green turtle, there are the overlapping crypts containing mucus found along the length of the duodenum and into the jejunum.

green turtles and leatherbacks. It is not as pronounced in the carnivorous/omnivorous species (e.g., loggerheads, ridleys, and hawksbills).

bulges somewhat more than the remaining large intestine (Fig. 77). It is more prominent in green turtles than other species. The colon narrows somewhat past the caecum; it is constricted weakly by segmentally arranged bands of muscle. Distally, the colon tapers to form a muscular rectum, which is often pigmented; its muscular walls are thickened and folded (Fig. 172).

The transitions from one type of small intestine to the next (**duodenum** to **jejunum** to **ileum**) are often difficult to identify. Gross differences are often not obvious and are best confirmed by

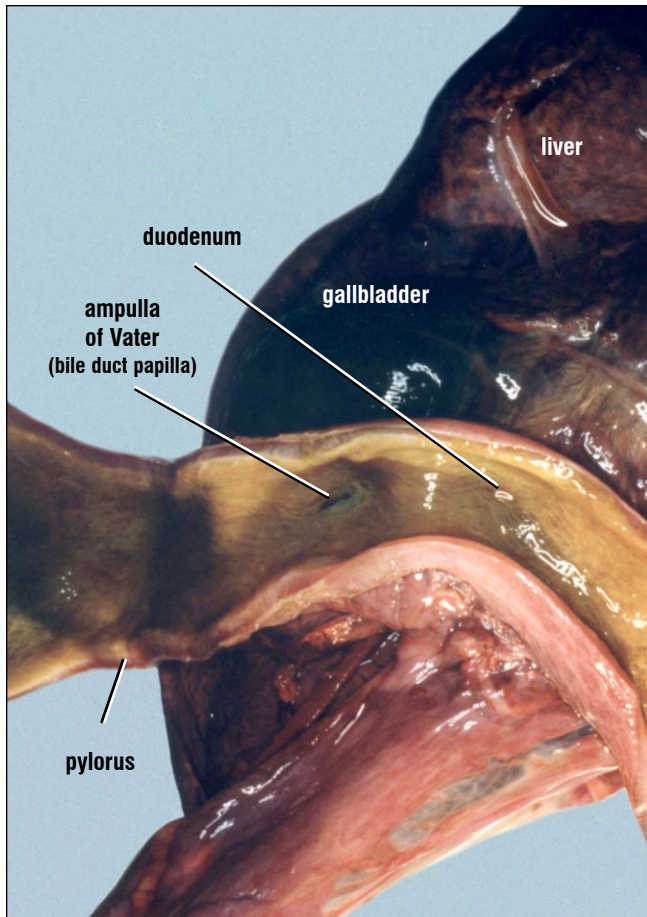


Fig. 170. Longitudinal section of the duodenum. The common bile duct opens into the duodenum at a papilla (termed the Ampulla of Vater). The common bile duct extends from the gallbladder to the duodenum.

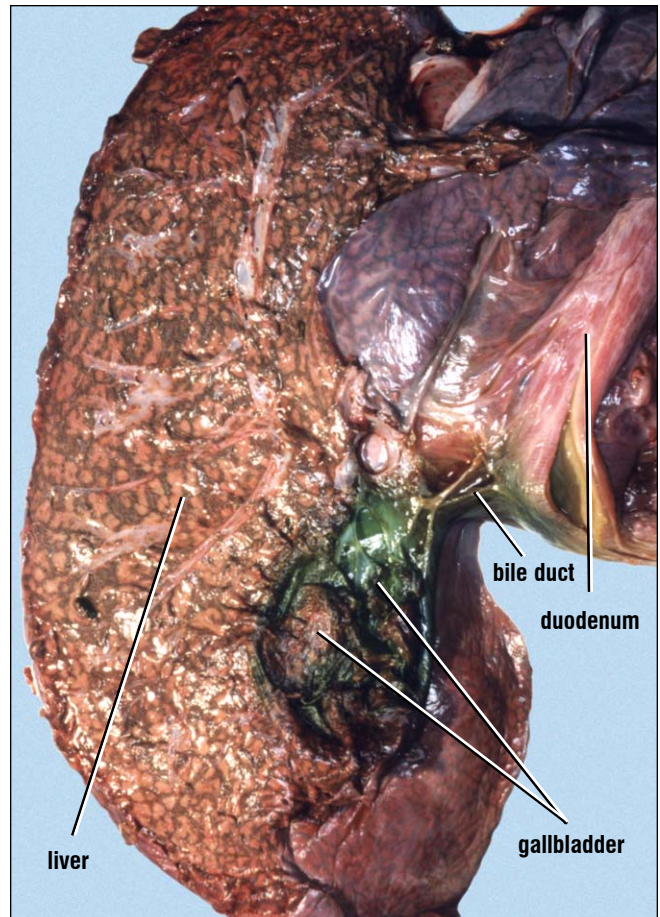
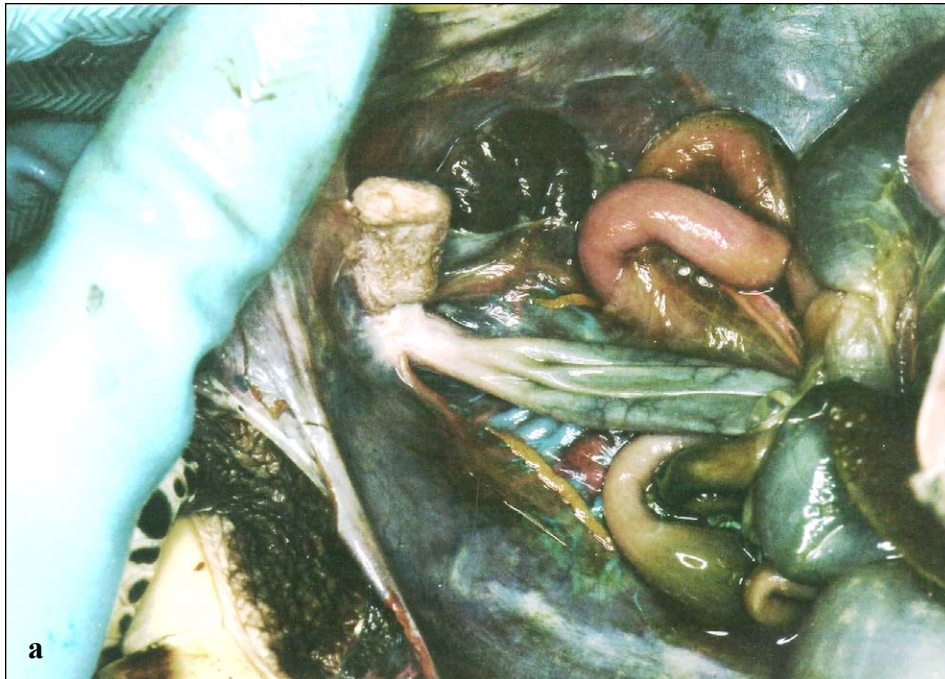
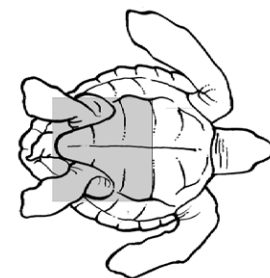
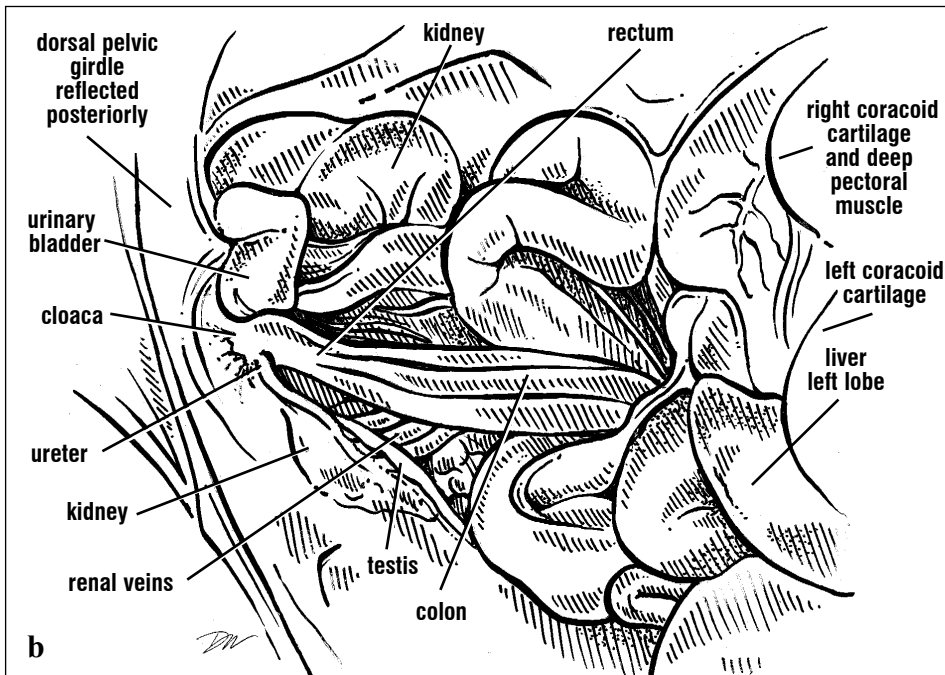


Fig. 171. Longitudinal section through the liver and gallbladder. The walls of the gallbladder are removed dorsally to expose the common bile duct to the duodenum.



Figs. 172a and 172b. *Ventral view of the posterior viscera. The rectum (collapsed here) narrows as it joins the cloaca. The urinary bladder; seen just above the rectum, enters the cloaca ventrally. The dorsally-located kidneys produce urine that travels through the ureters to enter the dorsal cloaca. Several renal veins are exposed medial to the kidney. The testis of this immature male is still attached to the peritoneum (and is located anatomically ventral to the kidneys).*



The rectum empties into the cloaca (Fig. 171), a chamber that also receives the urine from the kidneys, eggs or sperm, and connects ventrally into the urinary bladder. The cloaca empties to the outside via the cloacal opening or vent. Each function of the cloaca is associated with a region into

which the products empty. The **coprodeum** received feces from the rectum. The **urodeum** is associated with the **urinary papillae** and the opening of the urinary bladder. The **proctodeum** is the most distal region and is associated functionally with copulation and structurally with proximity to the genital ducts.

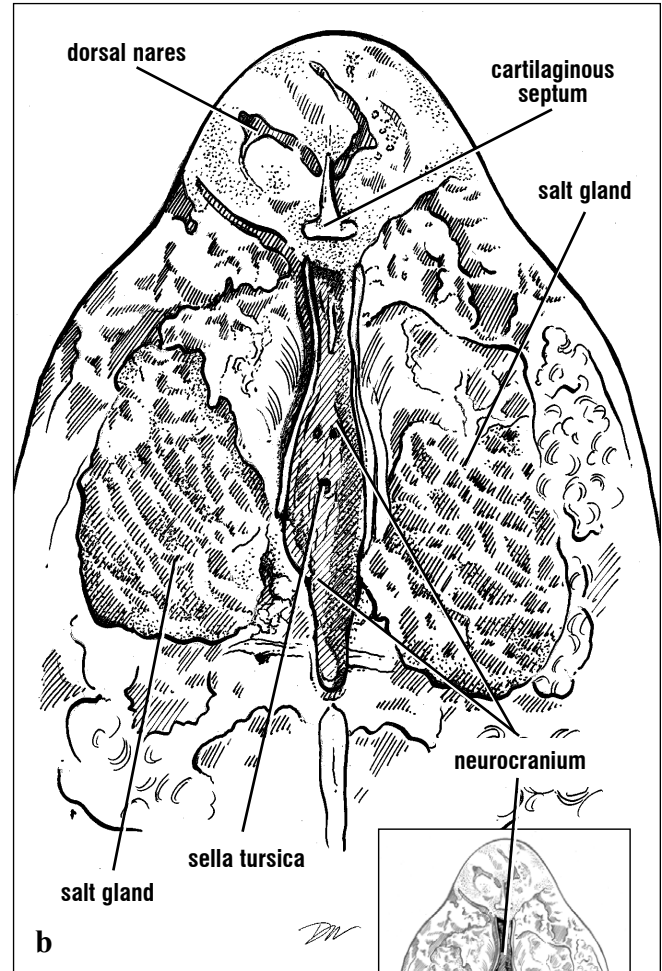
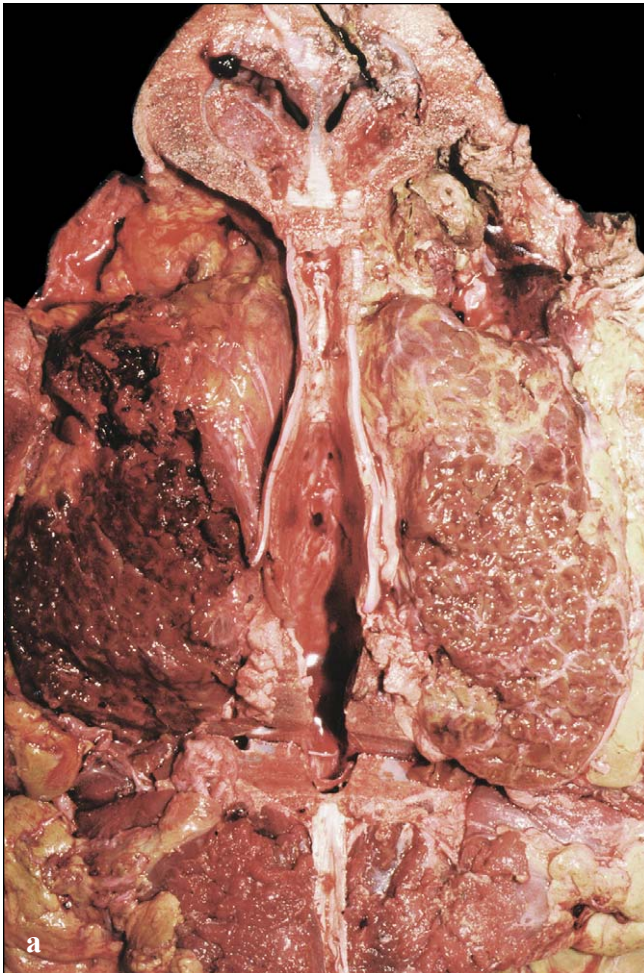
Glands

Glands are often lobular and may have ducts or are ductless. They are involved in the production of peptides and steroids, which can form skin coatings (waxes), enzymes, or hormones. Glands are either formed in the skin and its related structures (ectodermal in origin) or from deeper within the body (mesodermal in origin). Glands are discussed below by region and function, when known.

The **salt** (lacrimal) **gland** (Figs. 81 and 172) is the

largest gland in the head and is found dorsal and medial to the eye. These glands are large in all sea turtles, but are especially hypertrophied in *Dermochelys* (Fig. 172). The salt gland is responsible for removal of excess salt from the body. Anterior to the eye, there is a small **Harderian gland**, associated with lubricating the eye.

Sea turtles, like most aquatic lower vertebrates, appear to lack oral glands.



Figs. 172a and 172b. Dorsal view of the salt gland and braincase of a leatherback. The extremely large salt glands dominate the skull space lateral to the braincase and dorsal, medial, and posterior to the eye. The brain has been removed leaving the braincase with the sella tursica retaining the pituitary gland.

GLANDS

The ductless **pineal gland** (epiphysis) is a dorsal extension of the brain; it connects indirectly to the dorsal surface of the braincase, it is located deep to the frontoparietal scale in cheloniids and the "pink spot" in *Dermochelys* (illustrated in the Nervous System, Figs. 193-194, 196, 198-201). It is responsible for modulating biological rhythms.

The **pituitary gland** (hypophysis) is found in a cavity, the **sella tursica** in the floor of the braincase (Nervous System, Fig. 190). The pituitary is composed of two parts, the **neurohypophysis** (infundibulum) and the **adenohypophysis**. The neurohypophysis produces releasing hormones (e.g. oxytocin) and release-inhibiting hormones (e.g. antidiuretic hormone), while the adenohypophysis produces growth hormone, prolactin, thyroid-stimulating hormone, gonadotropins, adrenocorticoids, and melanophore-stimulating hormone.

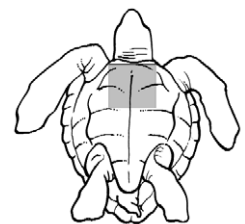
More posteriorly are several glands derived from pharyngeal pouches of the embryo. These ductless glands are the **thyroid, thymus, parathyroid, and ultimobranchial bodies**. All are located in the ventral neck and upper body. The thyroid gland can be located medially to the the acromion processes (Figs. 75 and 173) by tracing along the brachiocephalic trunk where it gives rise to thyroid arteries (soon after its bifurcation to form the subclavian arteries). The thyroid arteries "frame" the single thyroid gland that is encased in connective tissue (Fig. 173). The thyroid is round and is often coated with a thin layer of fat. In fresh specimens, it is bright red. However, in turtles that have been frozen, then thawed, or that have started decomposing, it may become brown. It is gelatinous in texture in fresh and fresh-frozen animals. In decomposing carcasses, it liquifies. The thyroid is involved with increasing oxygen consumption when reptiles exceed their preferred body temperatures, and it functions in gonadal maturation.

The thymus glands can be located by tracing along the subclavian arteries and palpating for a dense,

laterally elongated structure (Figs. 174-175). There is a gray to pink thymus gland on each side of the body that is composed of small lobes. It is usually associated with fat. The thymus glands are more dense and compact than the fat. They are often easiest to find by palpating. The thymus glands play a role in immune responses. In chronically ill animals this gland is frequently thin and diffuse.

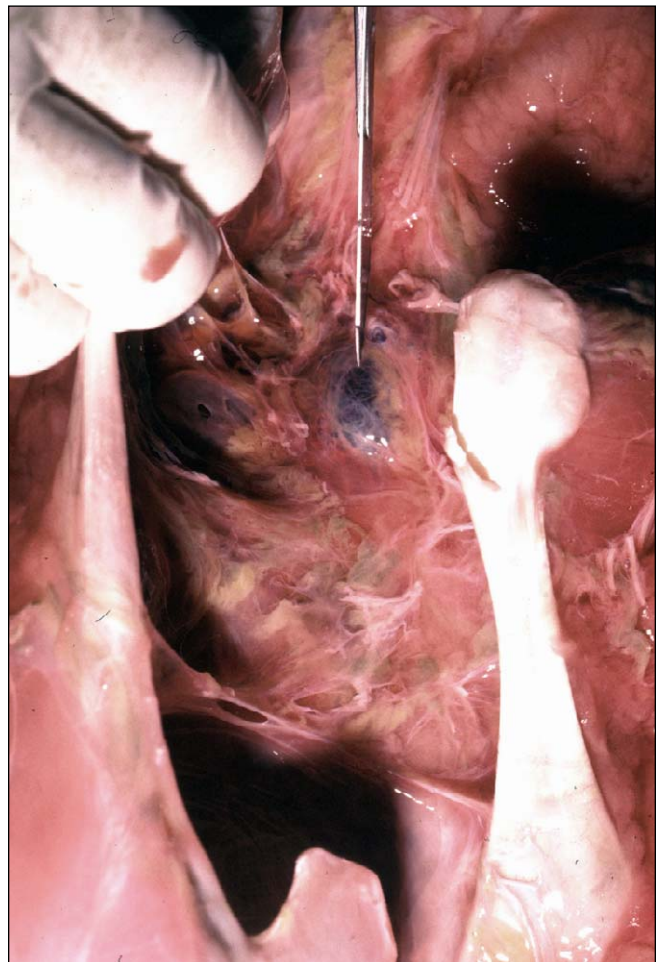

Fig. 173. *Thyroid gland in ventral view, medial to the acromion processes. The thyroid is the dark, round structure at the tip of the pointer. The heart has not been exposed yet. Anterior is toward the top of the figure. The two acromio-coracoid ligaments extend posteriorly from the acromion process.*



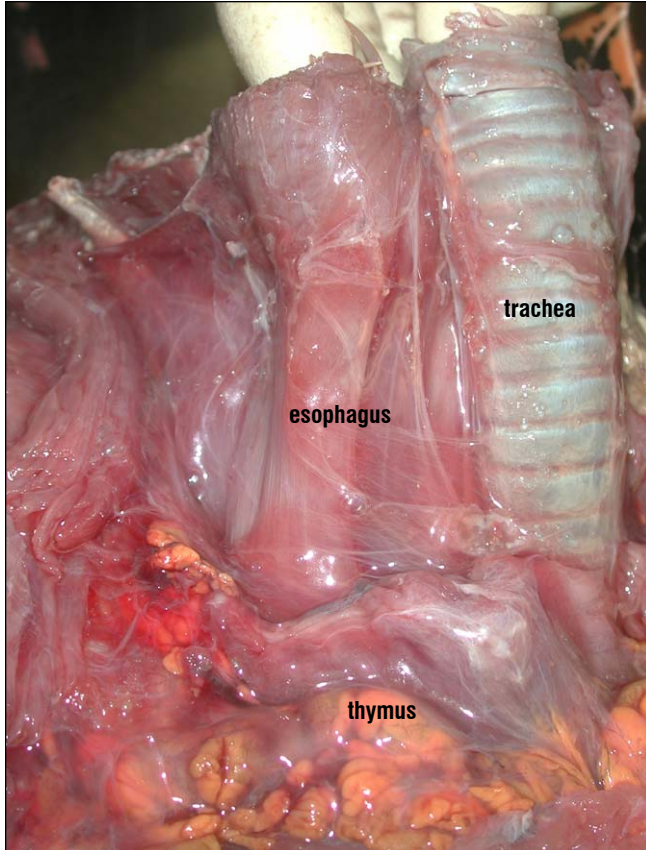


Fig. 174. Ventrolateral view of the neck structures. Positions of the trachea (with cartilaginous rings) and esophagus to the animal's right provide landmarks. The head is removed; anterior is toward the top of the picture. The lobular right thymus gland is at the bottom of the picture.

The **parathyroid** and **ultimobranchial bodies** are difficult to identify and can only be distinguished from one another histologically (Fig. 176). They are very small and located along the carotid and ventral cervical arteries. Generally, the parathyroid glands are the more anterior glands and the ultimobranchial bodies are more posterior. They are brown or dark pink in color. They are best

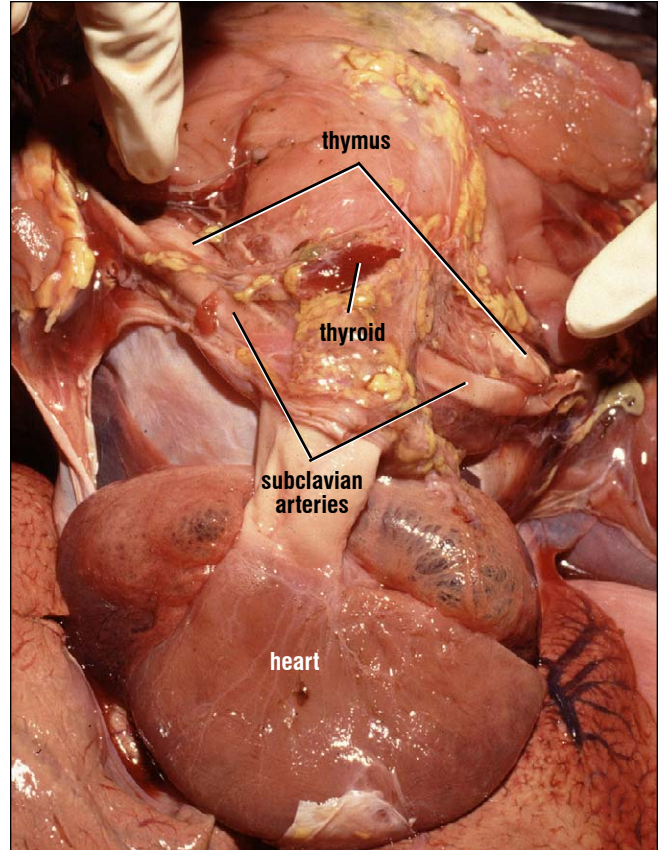
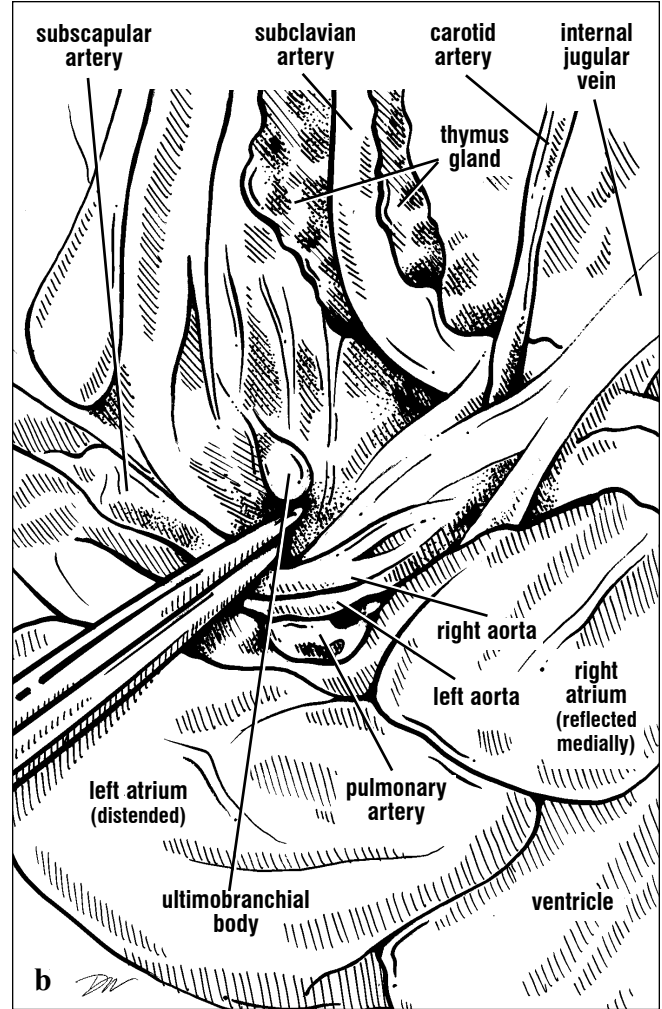
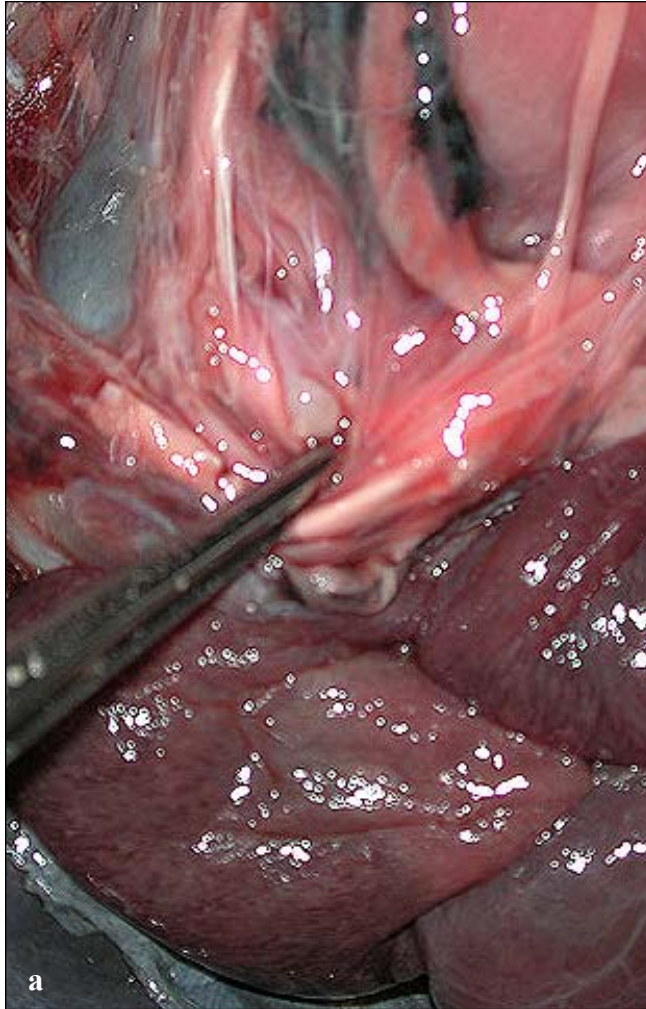
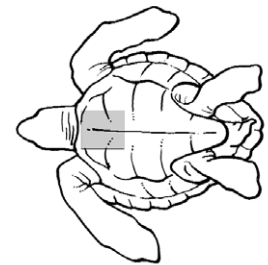


Fig. 175. Ventral view of the two thymus glands, just below the fingertips, are located adjacent to the subclavian arteries. They are anterior to the heart and lateral to the thyroid gland (seen as the smooth oval tissue anterior to the great vessels).

located by feeling for the round, dense glands, then using careful dissection. The two kinds of glands have antagonistic functions. The parathyroid gland releases parathormone, which stimulates the mobilization of calcium and phosphorus from storage (usually bones). The ultimobranchial body releases calcitonin, which lowers blood levels of calcium and phosphorus.



Figs. 176a and 176b. Ventral view of an ultimobranchial body (or parathyroid) and thymus gland. The carotid and ventral cervical arteries are the best landmarks for locating the parathyroid and ultimobranchial glands. The glands tend to be associated with the connective tissue on the dorsal surfaces of the arteries. Typically, 2-4 glands are present on each side. The large thymus gland, deep to the subclavian artery, is seen near the top of the picture.



GLANDS

The **liver** is the largest visceral organ and is located ventrally, but deep to the pectoral skeleton and peritoneum (Fig. 177). It is dark brown to reddish brown and composed of two lobes joined by one or more connecting strips of hepatic tissues. The right lobe houses the gallbladder on its ventral surface and is typically larger than the left lobe (Fig. 177). The liver is highly vascular; it receives blood from the hepatic portal vein and the hepatic artery. Blood from the body drains from the liver via the hepatic veins to the sinus venosus.

The liver contains many bile ductules and hepatocyte cords. The hepatocytes manufacture bile which drains via bile ductules into the gallbladder.

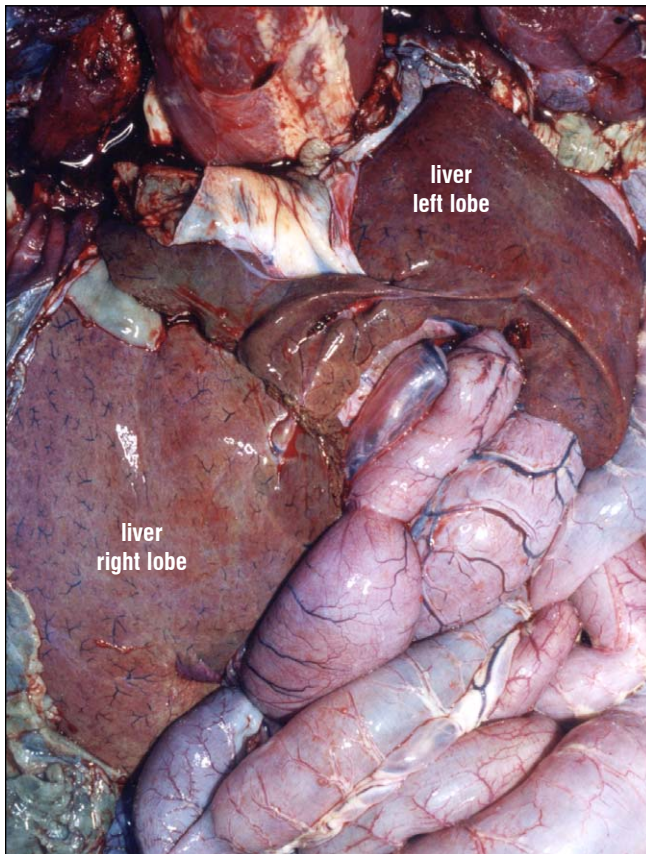


Fig. 177. The liver is exposed in a green turtle. The left and right lobes are located lateral and slightly dorsal to the heart. Both lobes receive blood from the hepatic portal system.

The gallbladder stores bile which is then transported via the common bile duct to the duodenum in response to the presence of fats. Bile contains the enzymes involved with fatty acid breakdown.

The liver plays a major role in carbohydrate and protein metabolism as well as in removal of toxins from the blood. Blood from the stomach and intestines percolates through hepatic tissues where carbohydrates, amino acids, and peptides are broken down. Other liver cells make serum albumin and a number of clotting factors.

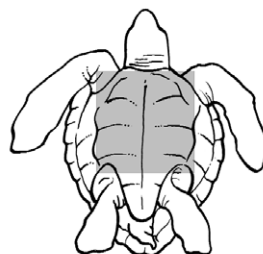
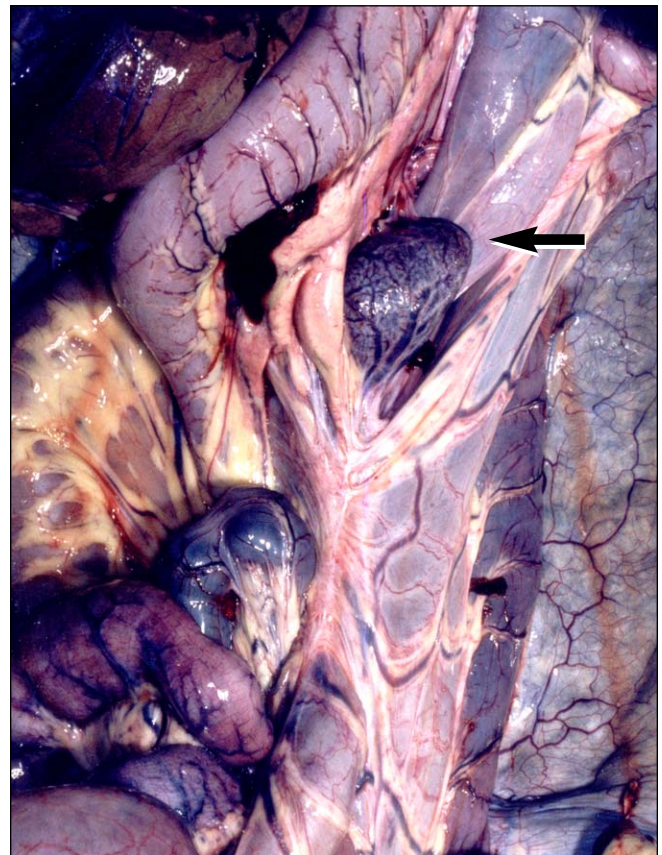

Fig. 178. Dorsal view of the duodenum (at top) with the pancreas, spleen (at arrow), and a portion of the liver's right lobe.

Pancreas. The pancreas is located along the duodenum just past the stomach (Fig. 178-179). It is a smooth and thick tissue that extends as an irregular strip past the common bile duct and often ends at or just past the spleen. It is pink to yellow orange in color. The pancreas is a digestive gland as well as an endocrine gland and produces

Rathke's glands are located deep to the inframarginal scutes in *Lepidochelys* (Figs. 180-181) and in the posterior axilla and anterior-most inguinal regions in *Eretmochelys* and *Chelonia* (Figs. 182-183). Rathke's glands have not been identified in *Caretta* and *Dermochelys*. While prominent, they show no change with reproductive

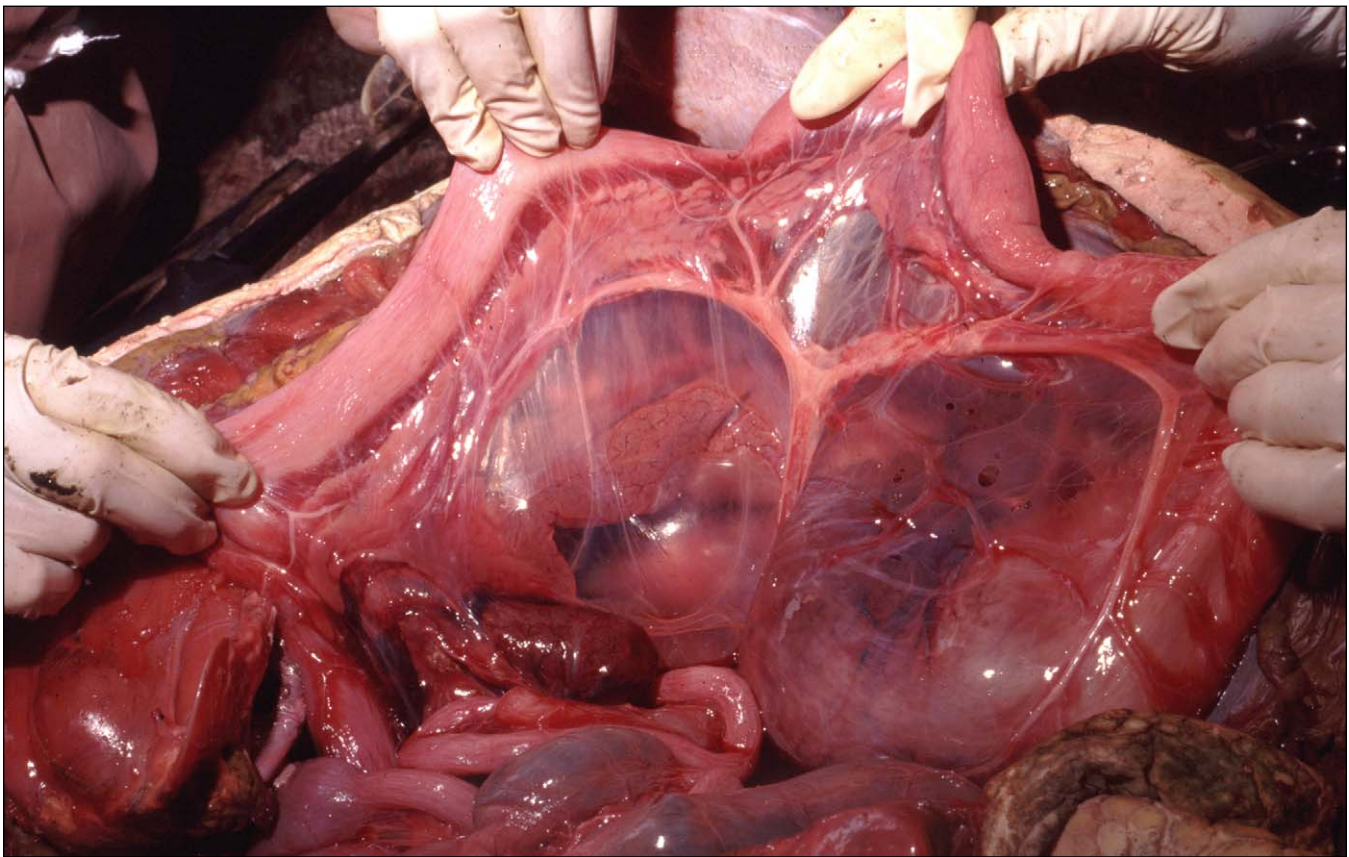
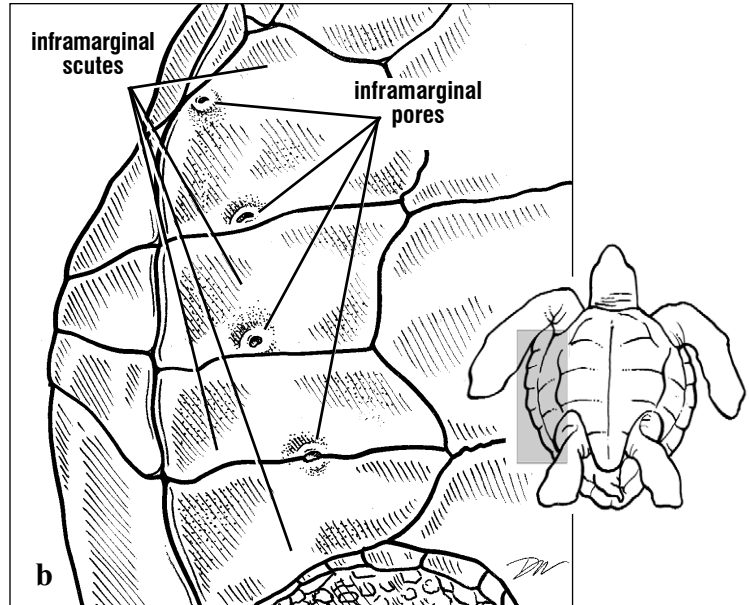
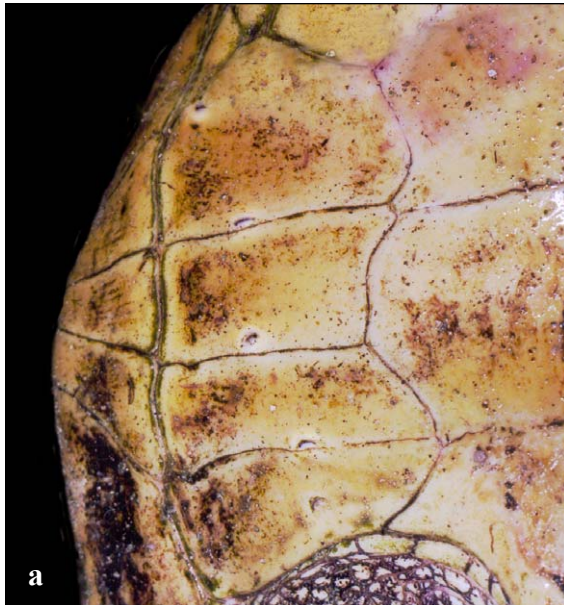

Fig. 177. The long narrow pancreas is seen just below the duodenum (at arrow) in this loggerhead dissection. It is encased in the mesentery. A large artery in the mesentery is seen supplying branches

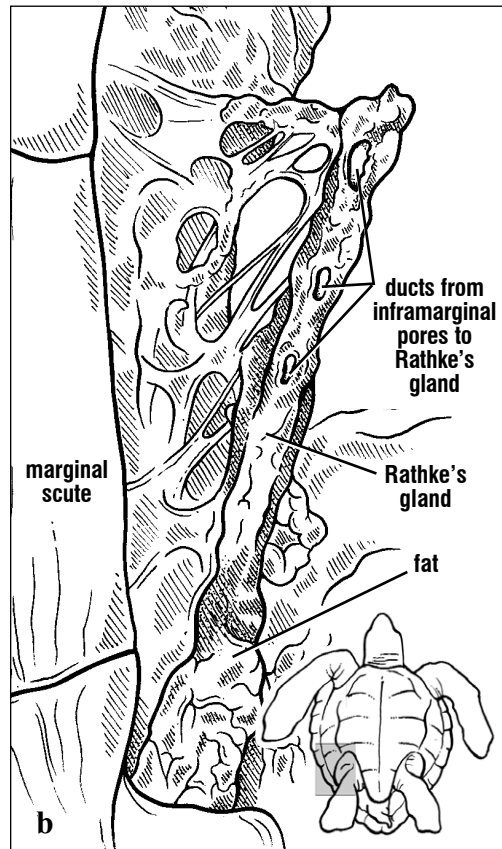
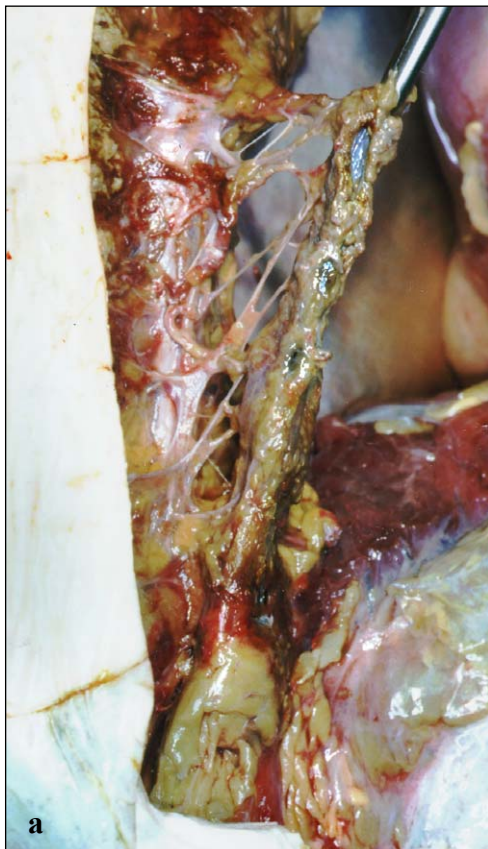to the proximal and distal pancreas. The dark, oval spleen is seen below the pancreas, above the loops of small intestines.

pancreatic polypeptides which stimulate flow of gastric juices in the stomach. Other pancreatic cells produce insulin which assists in the metabolism of glucose. Some pancreatic cells produce glucagon which stimulates the breakdown of glycogen to increase blood glucose levels.

condition or season. Their function is unknown. The secretions of the glands have been hypothesized to play various roles including intraspecific communication, anti-fouling, and/or anti-microbial function.



Figs. 180a and 180b. *Inframarginal Pores.* Ridley turtles have pronounced inframarginal or Rathke's pores associated with each inframarginal scute. The pores lead to the Rathke's gland. In mature turtles, with fully developed plastron bones, the ducts from these pores are surrounded by bone. They leave foramina (holes) in the hyoplastron and hypoplastron bones.

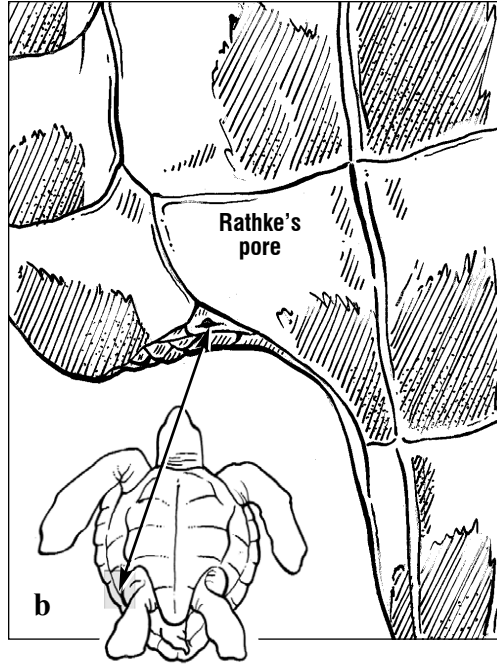
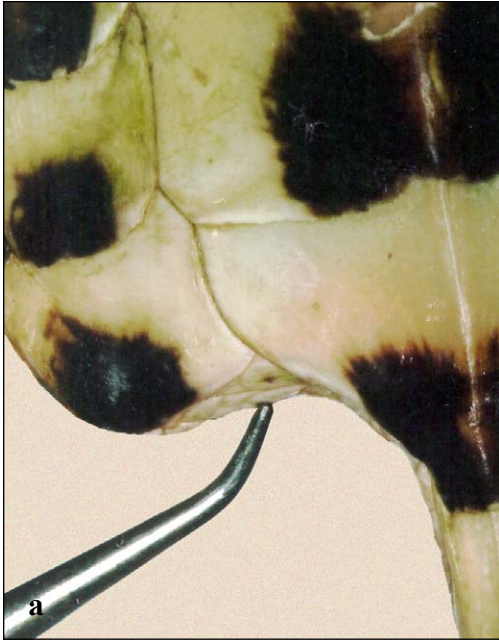

Figs. 181a and 181b. When the plastron is removed, the gray-green Rathke's gland and its ducts are exposed. Each duct leads to an inframarginal (Rathke's) pore. The gland is typically embedded in fat. It extends the length of the inframarginal scutes from the axilla to the anterior extent of the inguinal region.

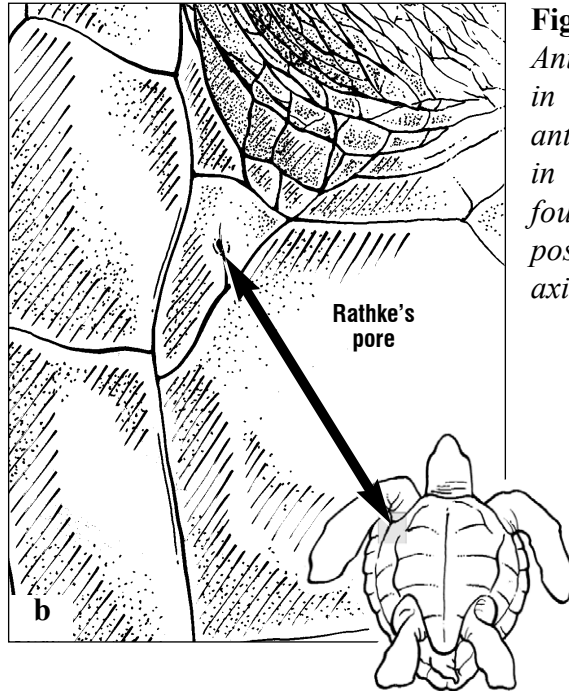
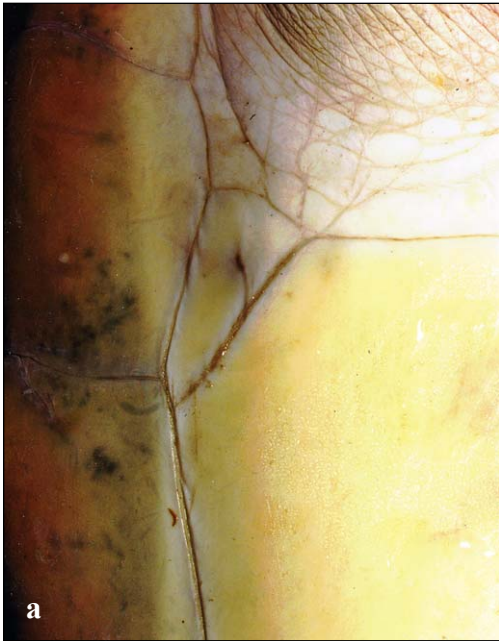GLANDS

Rathke's pores and Rathke's glands are also found in *Chelonia mydas* and *Eretmochelys imbricata*. They are restricted to the posterior axilla and the

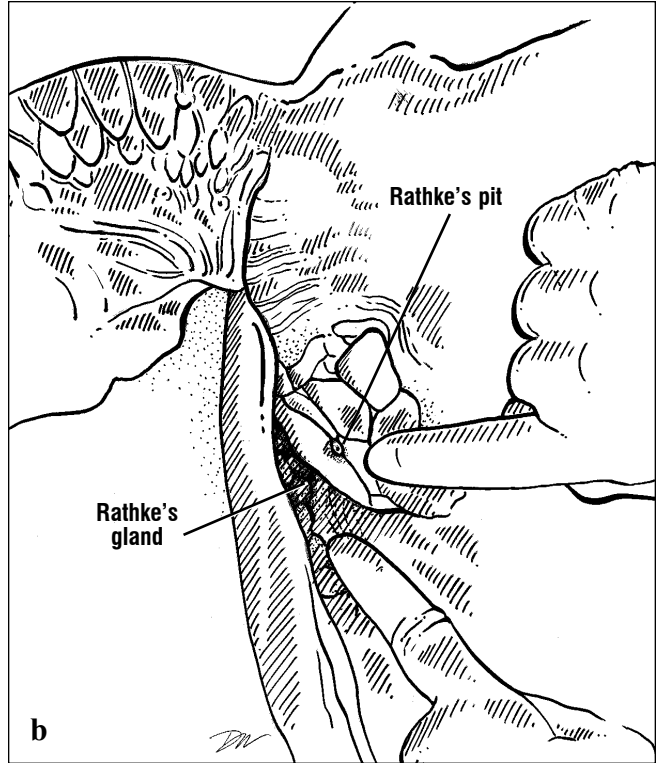
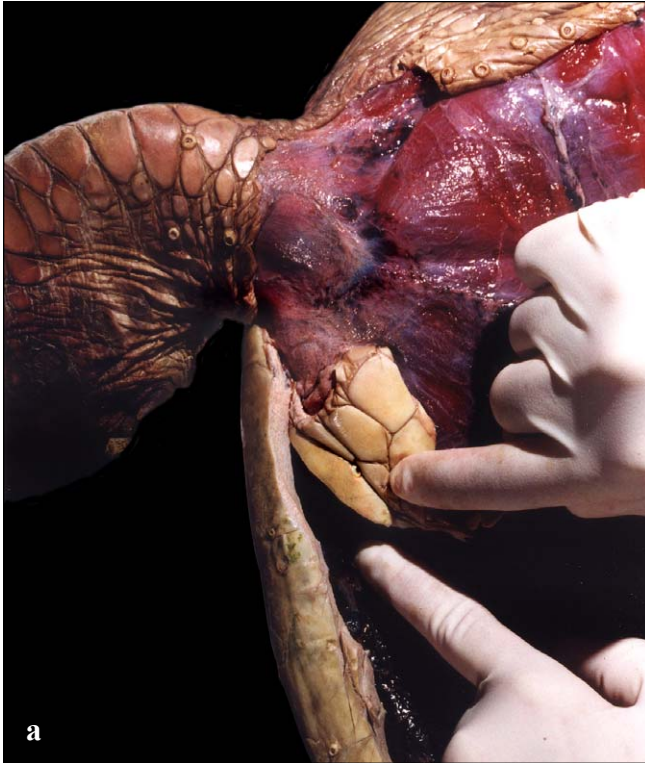anterior-most inguinal scales. The pores typically do not extend to the inframarginal scutes (Figs. 182-185).



Figs. 182a and 182b. Rathke's pores in a hawkbill. The posterior Rathke's pore in this hawkbill is found in the anterior-most inguinal scale.

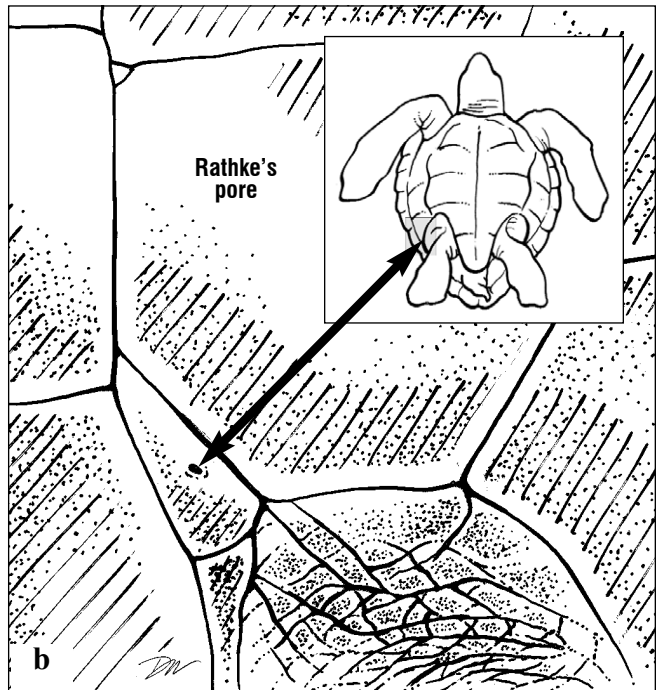
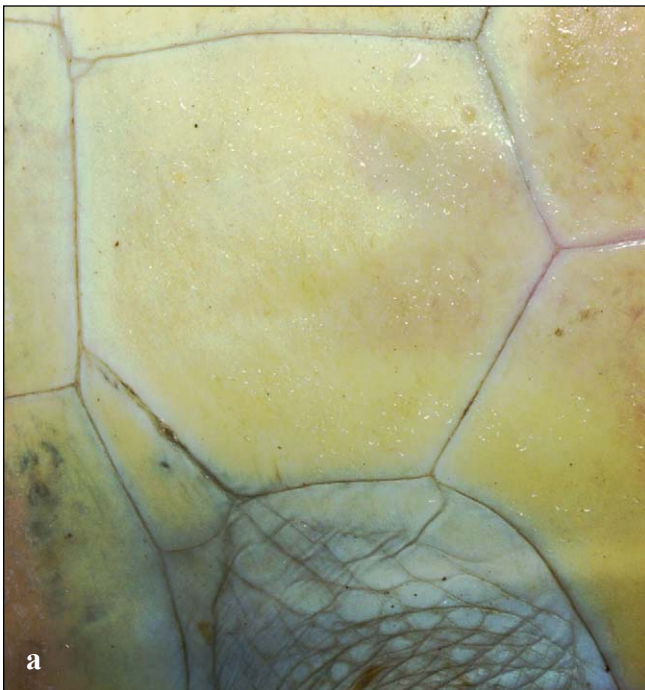


Figs. 183a and 183b. Anterior Rathke's pore in a green turtle. The anterior Rathke's pore in this green turtle is found in the most posterior and lateral axillary scale.



Figs. 184a and 184b. Rathke's gland and pore in a green turtle. As the plastron is removed, the gray

Rathke's gland can be found embedded in fat just deep to the Rathke's pore.



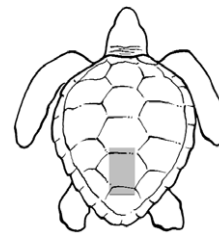
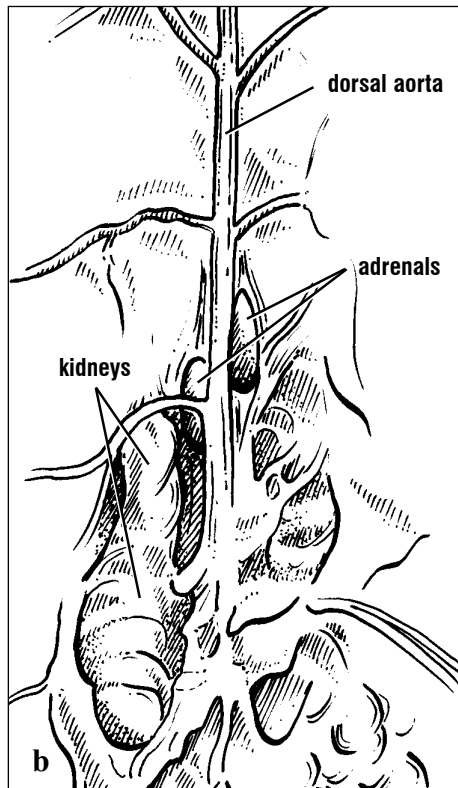
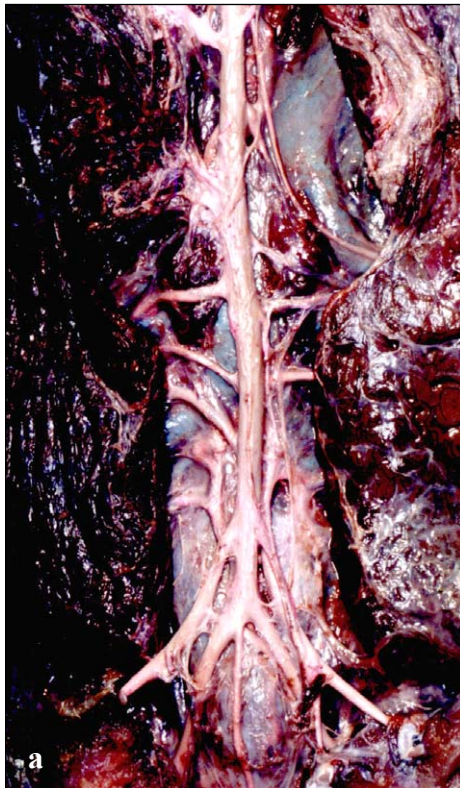
Figs. 185a and 185b. Posterior Rathke's pore in a green turtle. The posterior Rathke's pore in this

green turtle is found in the most anterior and lateral inguinal scale.

GLANDS

The **adrenal glands** (Fig. 186) are paired, tan to pink in color and are located lateral to the dorsal aorta, usually anterior to the renal arteries. They are usually medial to, and just anterior to, the kidneys. The adrenal glands develop from the anterior (cranial) poles of the embryonic kidneys. The paired adrenals are elongated along the anterior-

posterior axis and oval in cross section. They are composed of two intermingling tissue types: interrenal bodies, that produce steroids (corticosterone) and chromaffin bodies that produce catecholamines such as adrenaline (epinephrine and norepinephrine). Unlike mammals, these tissues are not organized into a distinct cortex and medulla.



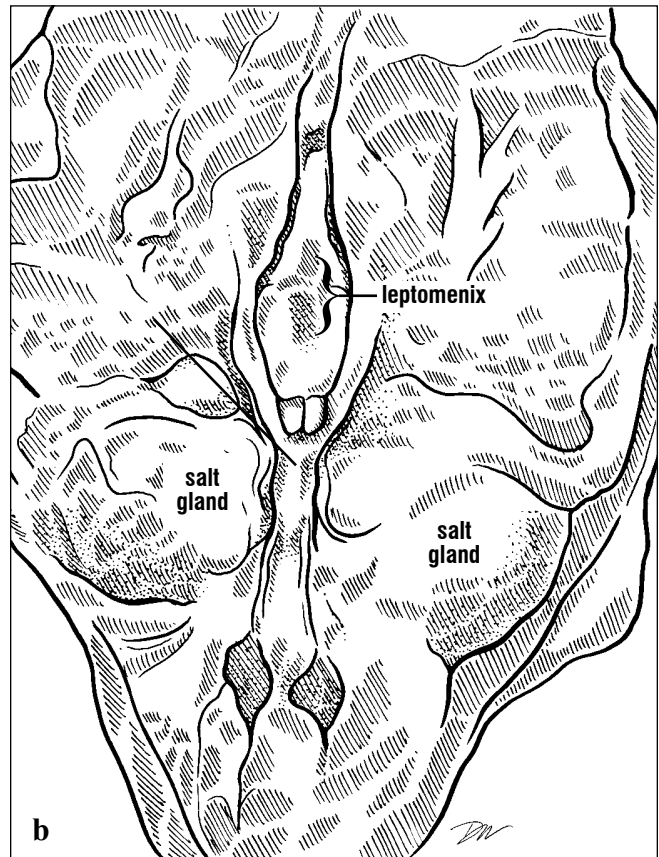
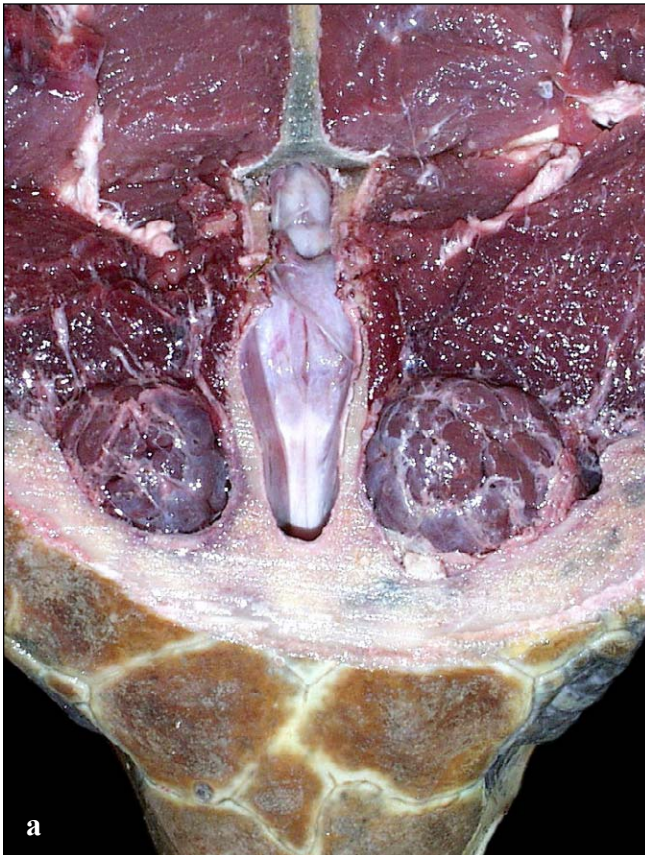
Figs. 186a and 186b. Adrenal glands. This dorsal view of the adrenal glands shows their elongate shape and their position just anterior and medial to the kidneys. The adrenal arteries are not clear in this dissection. The left adrenal is crossed by a costal artery.

Nervous System

The **brain** or **central nervous system (CNS)** of sea turtles is longitudinally arranged along the mid-line of the skull (Fig. 187). The brain is housed in a tubular braincase, composed anteriorly of the following bones: ethmoid, epiotic, prootic, opisthotic, basisphenoid, laterosphenoid, and otic (Figs. 26 and 30). Posteriorly it is completed by the basioccipital, exoccipital, and supraoccipital. It is roofed by the parietal and frontal bones (Fig. 25).

Two tissue layers, the **meninges**, cover the brain.

The outer menix (singular) is the tough **dura mater**. A more delicate leptomenix (sometimes termed the pia mater) lies directly on the brain's surface (Fig. 187). There are both subdural (beneath the dura mater) and epidural (above the dura mater) spaces within the brain case. **Epimeningeal veins** occupy some of the epidural space. The brain is bathed in clear **cerebral spinal fluid** produced by the **tela choroidea**, a vascular region of the brain (Fig. 187).



Figs. 187a and 187b. Exposed brain and cut meninges. The anterior and posterior extent of the dura mater and a vascular portion of the lep-

tomenix (= pia mater) are seen in this exposed loggerhead brain. In life, both meninges would envelop the brain.

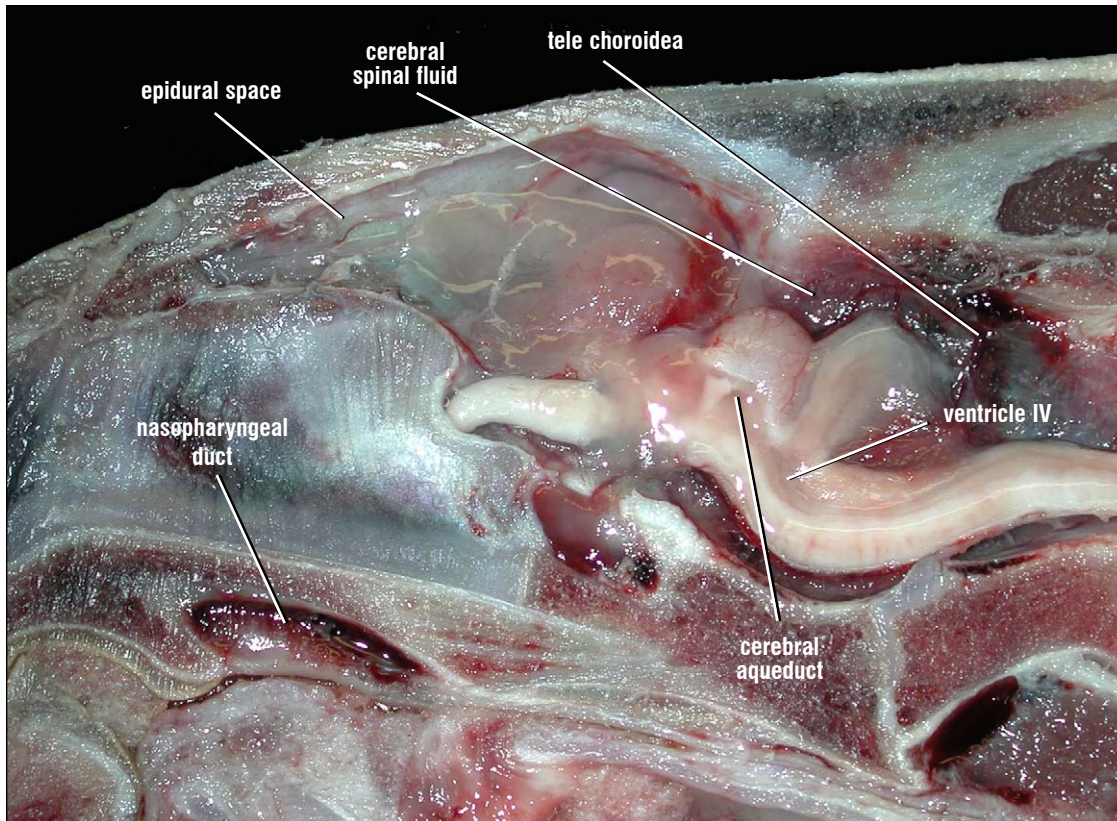
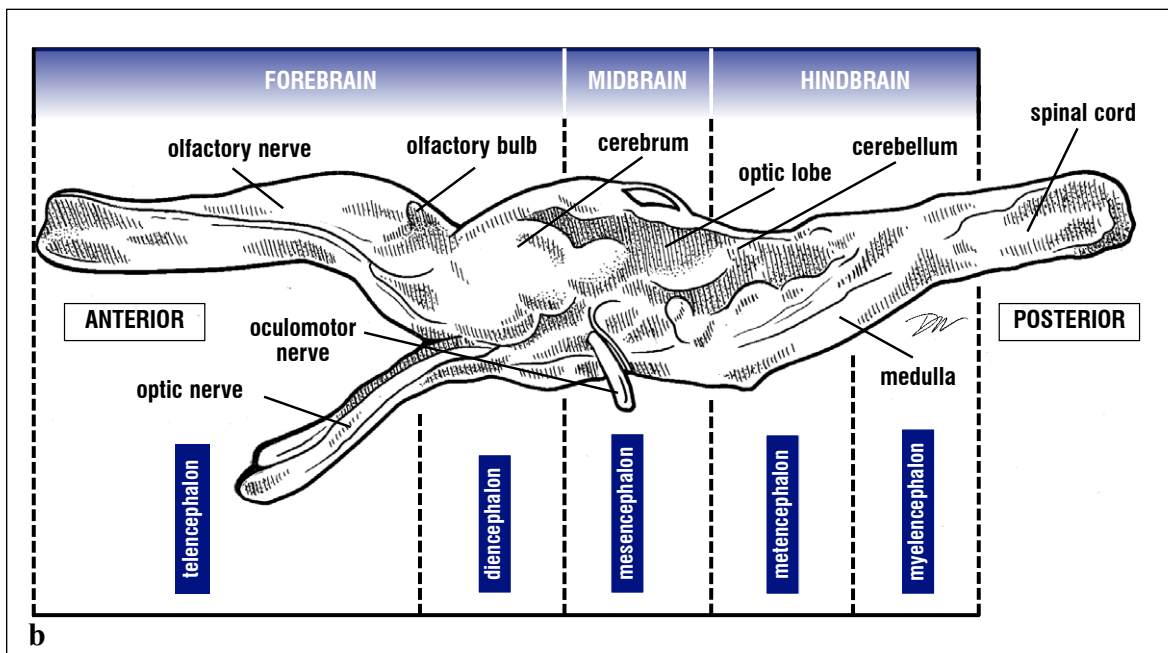
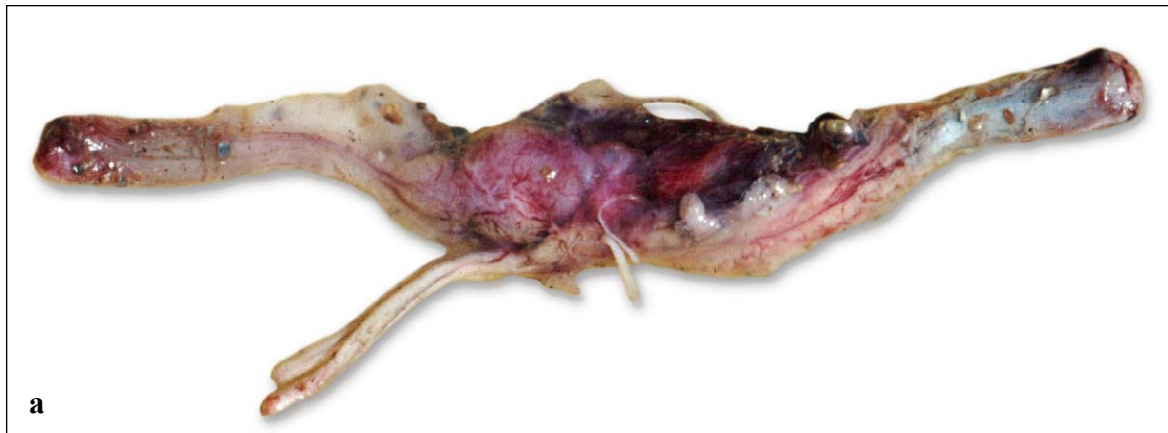

Fig. 188. Parasagittal section of the brain and airways. The section through this green turtle head shows the tight epidural space and the more voluminous subdural space surrounding the brain. Because this cut is to the right of the midline, the cerebral ventricles and part of the cerebellar ventricle can be seen. The nasopharyngeal duct, part of the respiratory system, can be seen passing from the olfactory sacs to the internal choane.

Traditionally, the brain (Fig 189) is described by three regions that are initially demarked during development: the **forebrain**, **midbrain**, and **hindbrain**. The following combinations of external and internal landmarks roughly identify these divisions. The forebrain extends from the nose to the posterior cerebrum. The midbrain extends from the eye to the posterior aspect of the

optic lobes. The hindbrain extends from the ear to the posterior cerebellum. These regions, in turn, are subdivided topographically and/or histochemically into principal divisions: **telencephalon** and **diencephalon** of the forebrain, **mesencephalon** of the midbrain, **metencephalon** and **myelencephalon** of the hindbrain (Fig. 189).



Figs. 189a and 189b. Leatherback brain showing major regions and landmark structures. The brain is demarcated into its major regions and principal divisions.

The divisions of the brain and their major components are as follows.

Telencephalon: cranial nerve I, (olfactory nerve), olfactory bulbs, cerebral hemispheres, lateral ventricles.

Diencephalon: hypothalamus, thalamus, infundibulum and pituitary, pineal, optic chiasma, cranial nerves II-III (optic and oculomotor nerves).

Mesencephalon: optic lobes, third ventricle, cerebral aqueduct, cranial nerve IV (trochlear nerve).

Metencephalon: cerebellum, anterior part of medulla, fourth ventricle, cranial nerves V-X (trigeminal, abducens, facial, statoacoustic, glossopharyngeal, and vagus, respectively).

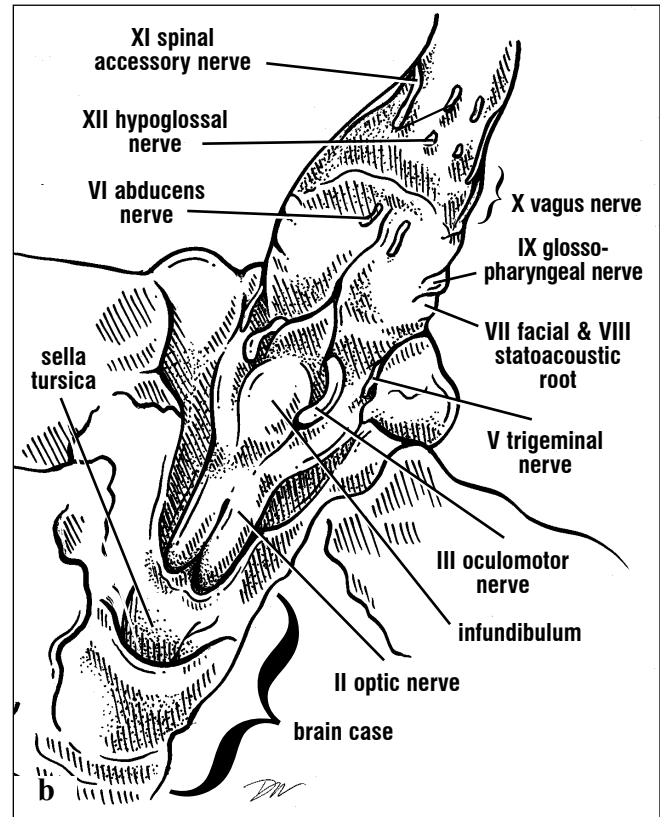
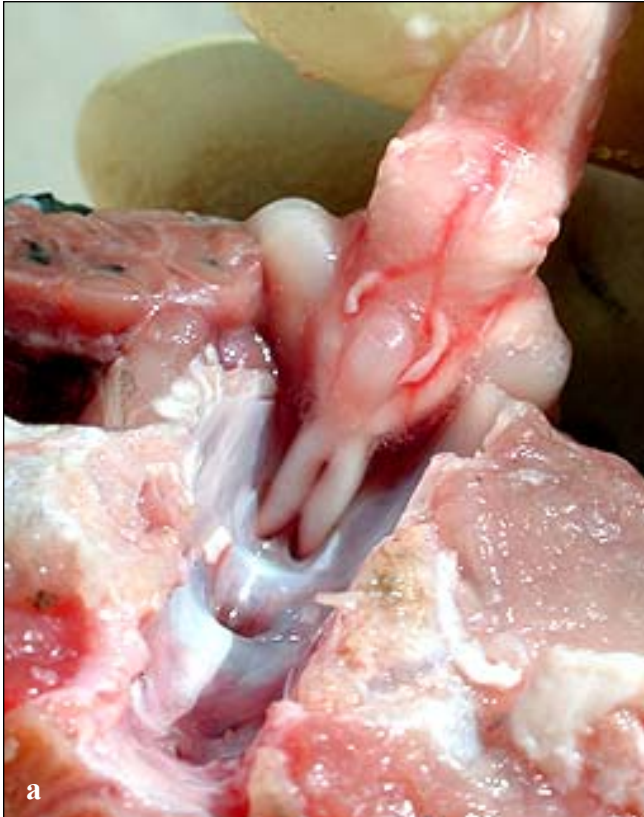Myelencephalon: most of medulla, cranial nerves XI-XII (spinal accessory and hypoglossal).

NERVOUS SYSTEM

The brain forms as a tube during sea turtle development. It then undergoes considerable regional specialization, torsion, and expansion to form the structures found in adult turtles. Remnants of the nerve tube cavity persist as the **lateral ventricles** of the cerebral hemispheres, the **third**

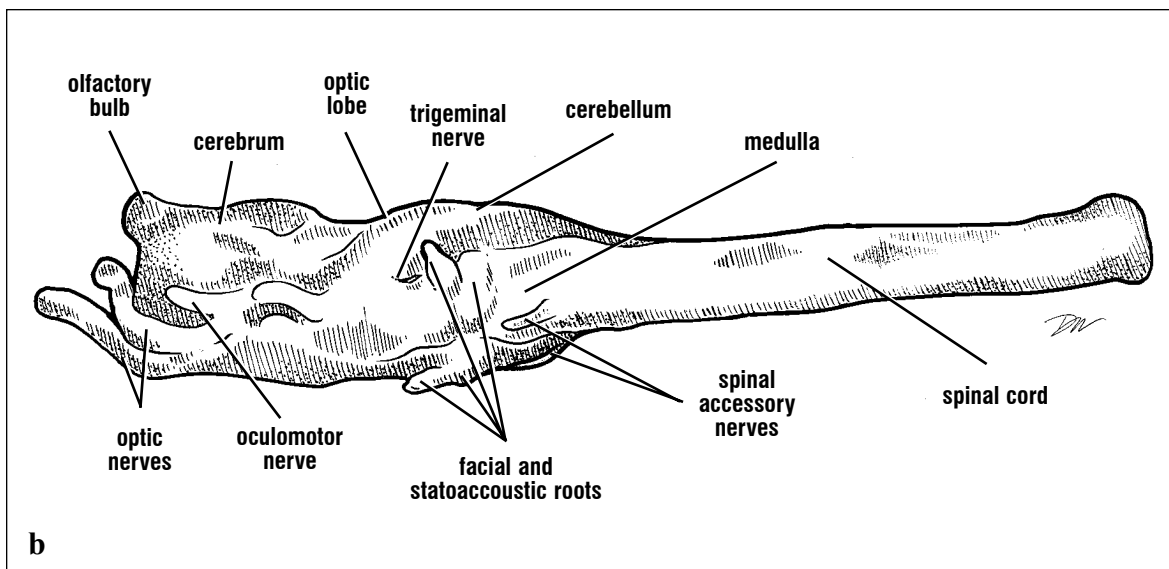
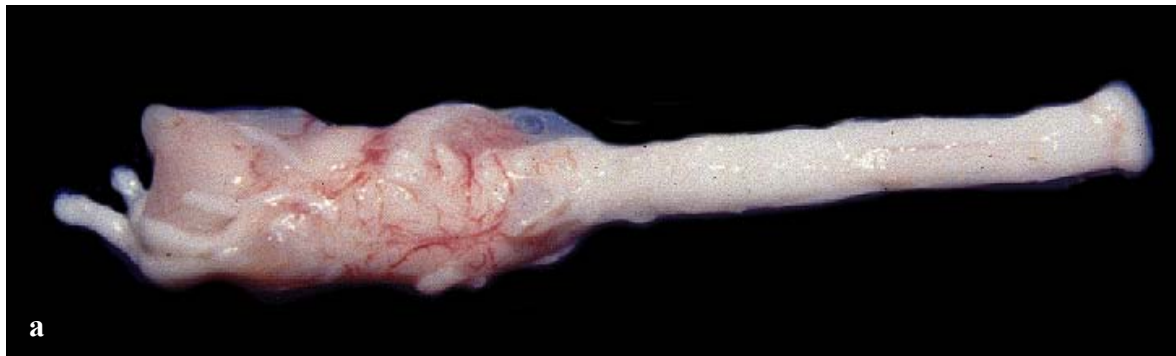ventricle and **cerebral aqueduct**, and the **fourth ventricle** of the cerebellum and medulla (Fig. 188).

Most of the cranial nerves arise ventrally and laterally, and are easiest to observe when the brain is removed (Figs. 189-191).



Figs. 190a and 190b. *Ventral surface of a ridley brain. This brain is viewed from the posterior aspect of the skull and is reflected anteriorly and dorsally. Only the optic and olfactory nerves are*

still attached to the head. The cut pituitary can be seen in the sella tursica in the floor of the brain case, while the infundibulum is removed with the rest of the brain.



Figs. 191a and 191b. Ventrolateral view of a loggerhead brain without the olfactory nerves. The size of the brain of mature and maturing turtles is remarkably small for the body size. This brain from a 72 cm SCL loggerhead is just less than 10 cm long.

Specific landmarks identifying the parts of the brain differ slightly across cheloniids and, even more when compared with *Dermochelys* (Figs. 192-202). Among the cheloniids, the brain is closest to the skull roof in *Lepidochelys kempii*. It is furthest from the skull roof in adult *Caretta caretta* and *Eretmochelys imbricata*.

Scalation patterns on the lateral head and the position of the ear provide species-specific landmarks for some structures (Fig. 192). The brain of the leatherback is housed deeply, except for the pineal, which extends dorsally in a cartilaginous cone-like chamber adjacent to the pink spot on the middorsal surface of the head (Figs. 201-202).

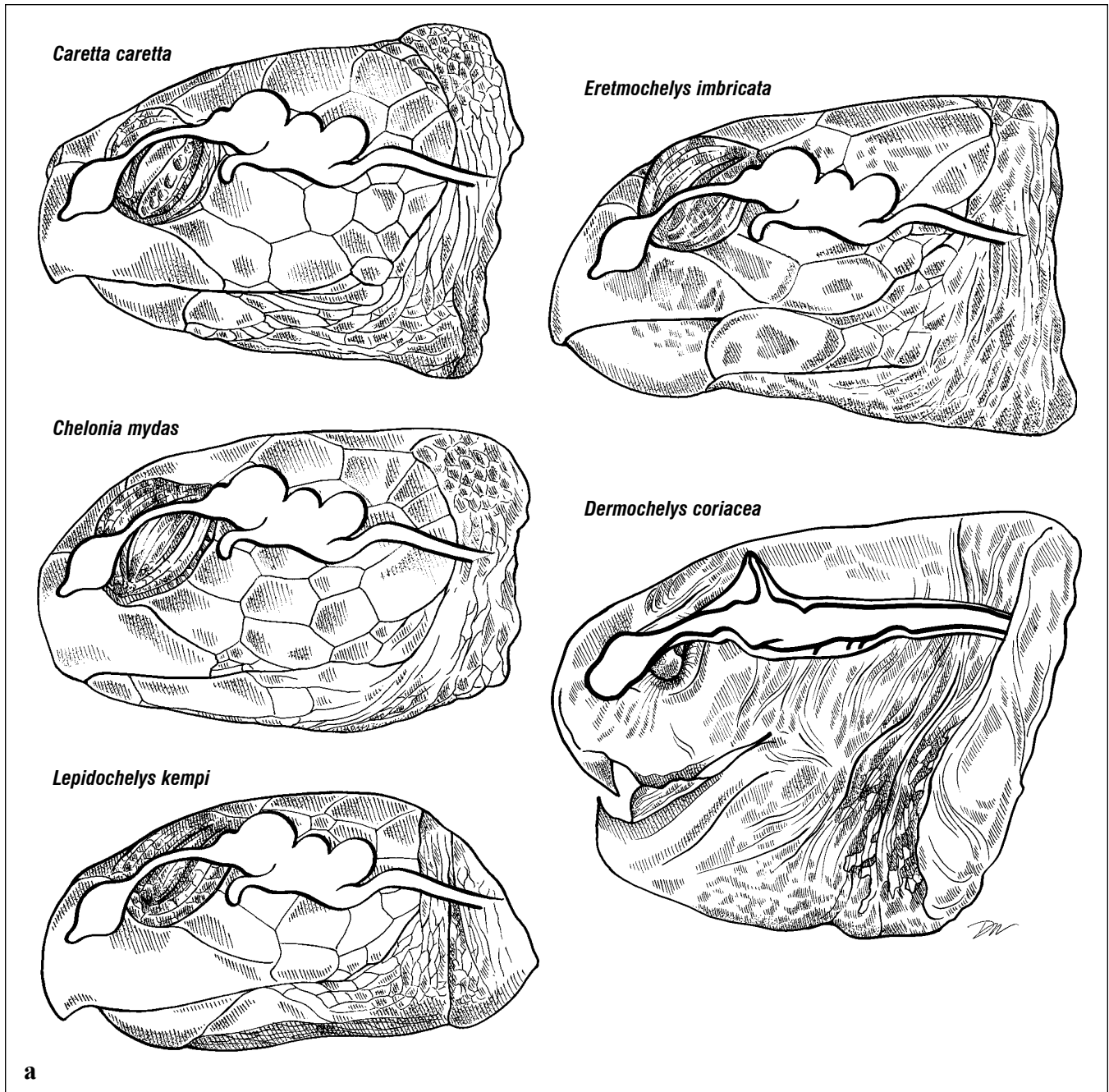
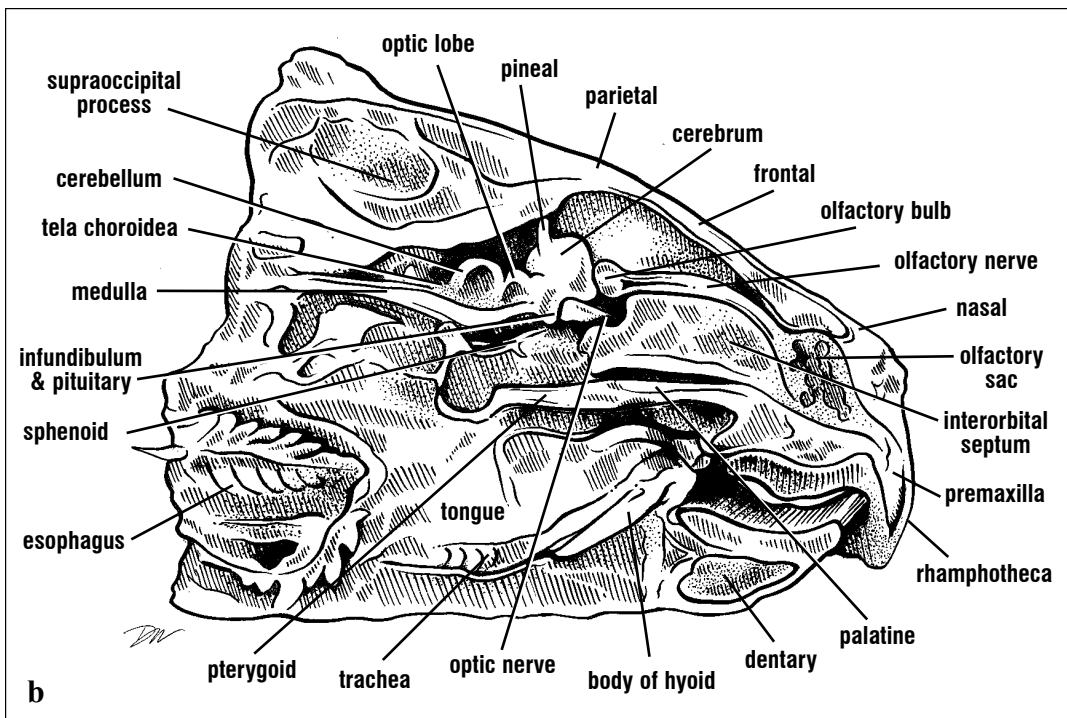
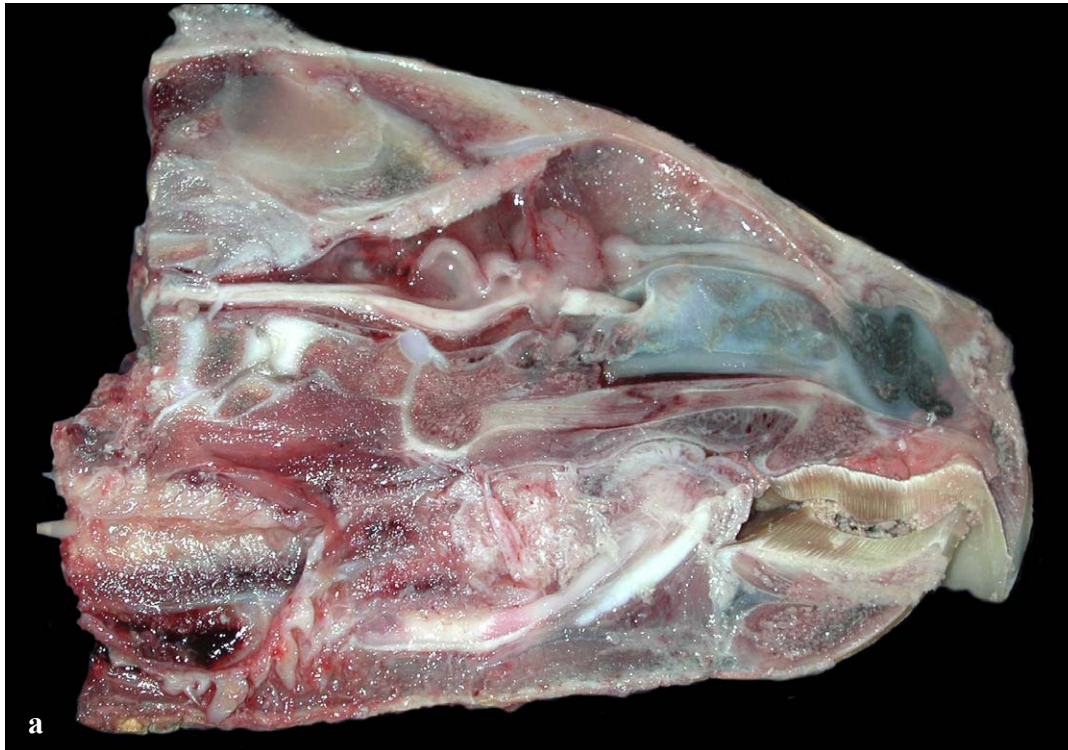
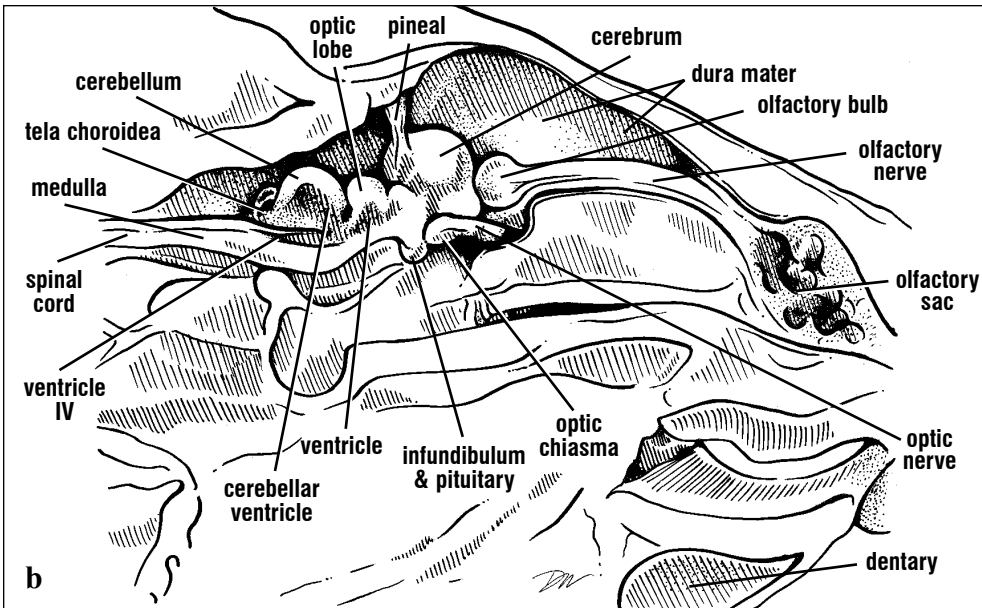
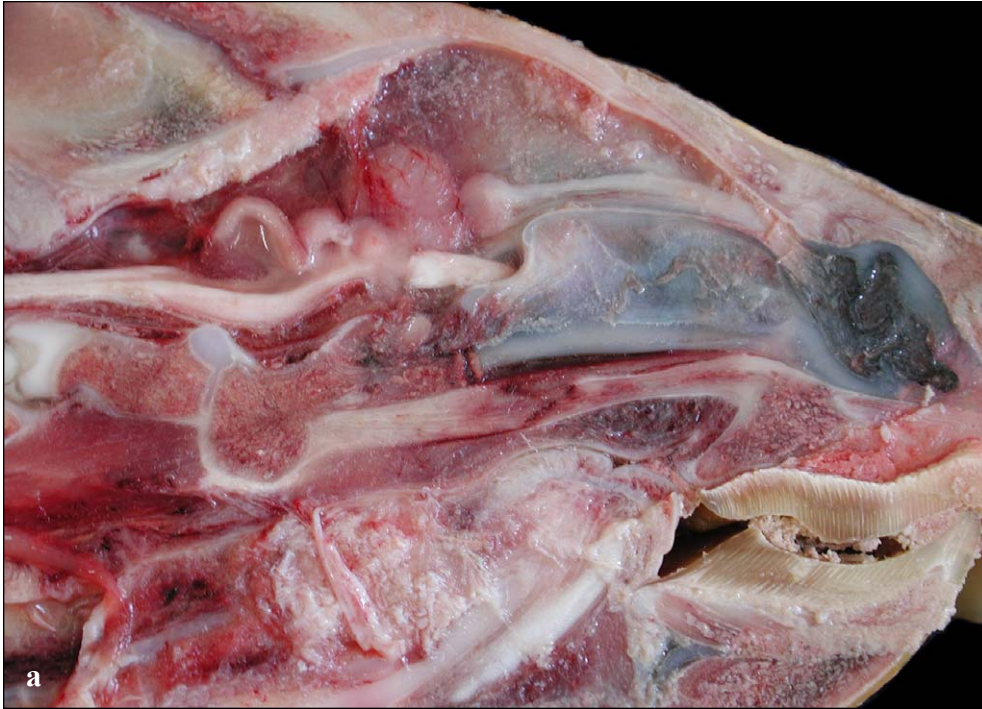

Fig. 192. Brain landmarks for marine turtles. Overlays of brain positions are shown for 5 species. The position of the head scales, the eye, and the ear provide some reference points for identifying the position of the brain, which varies in dorsal-ventral position with species. The brain position of the

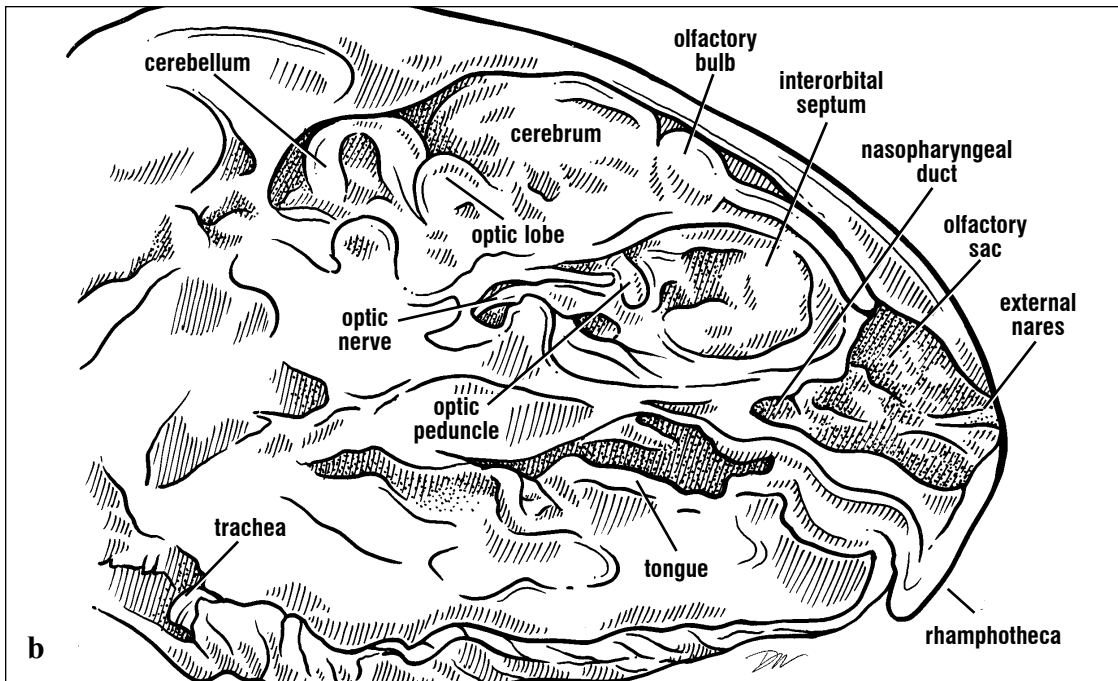
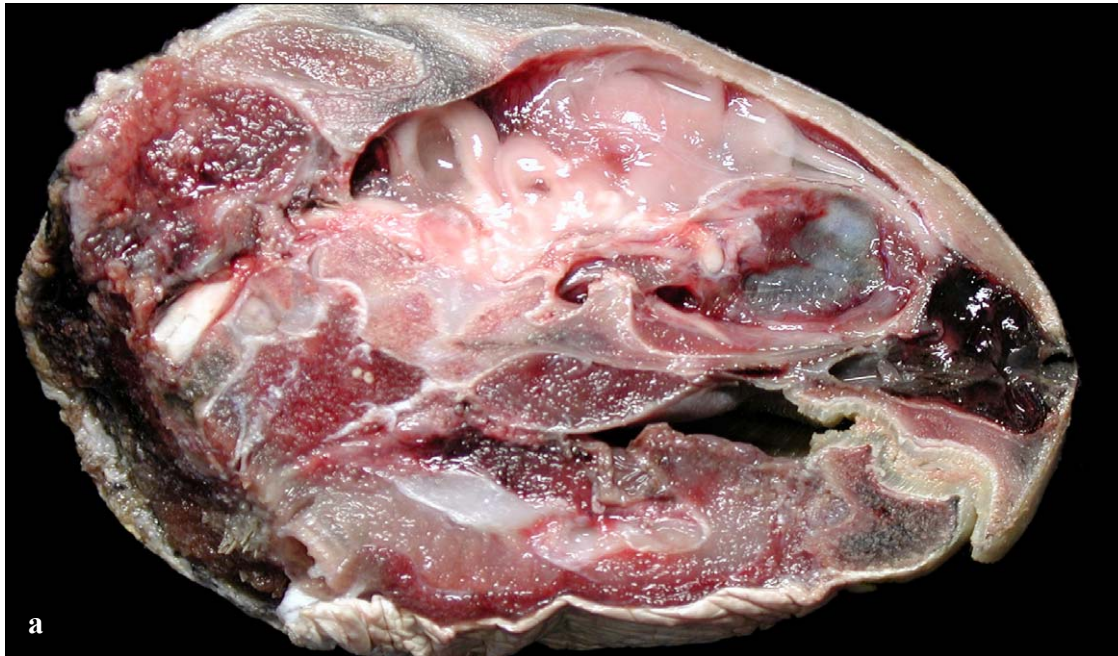leatherback, in this drawing, is based more upon the shape of the braincase because of the poor condition of all leatherback brains examined. The landmarks shown are accurate for large turtles, however the brains of hatchlings and juveniles are disproportionately larger.



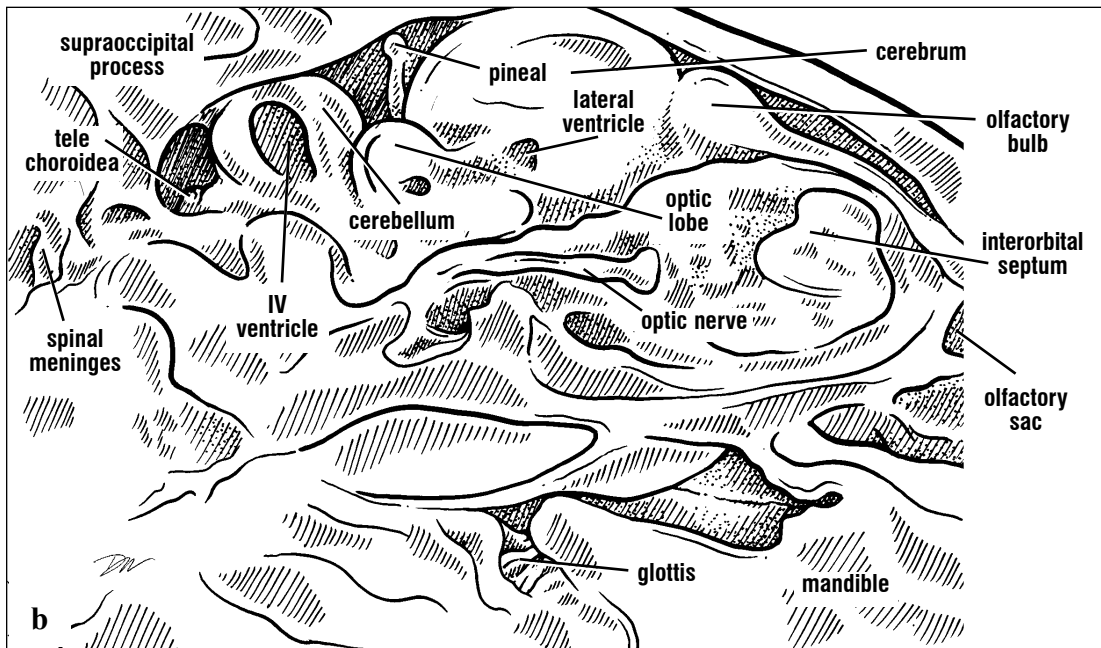
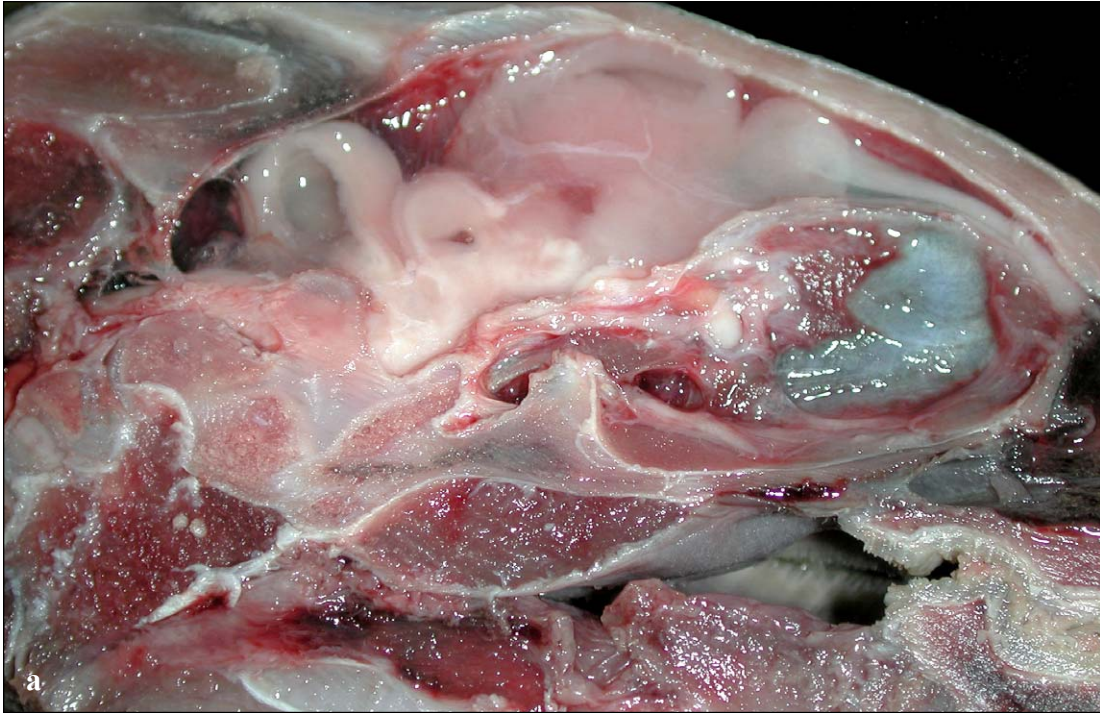Figs. 193a and 193b. Parasagittal view of a loggerhead head. The brain, airways, oral cavity, and esophagus are exposed. The interorbital septum is intact and the optic nerve is seen passing through its foramen. There is a large subdural space, above the cerebrum and olfactory nerve, in loggerheads.



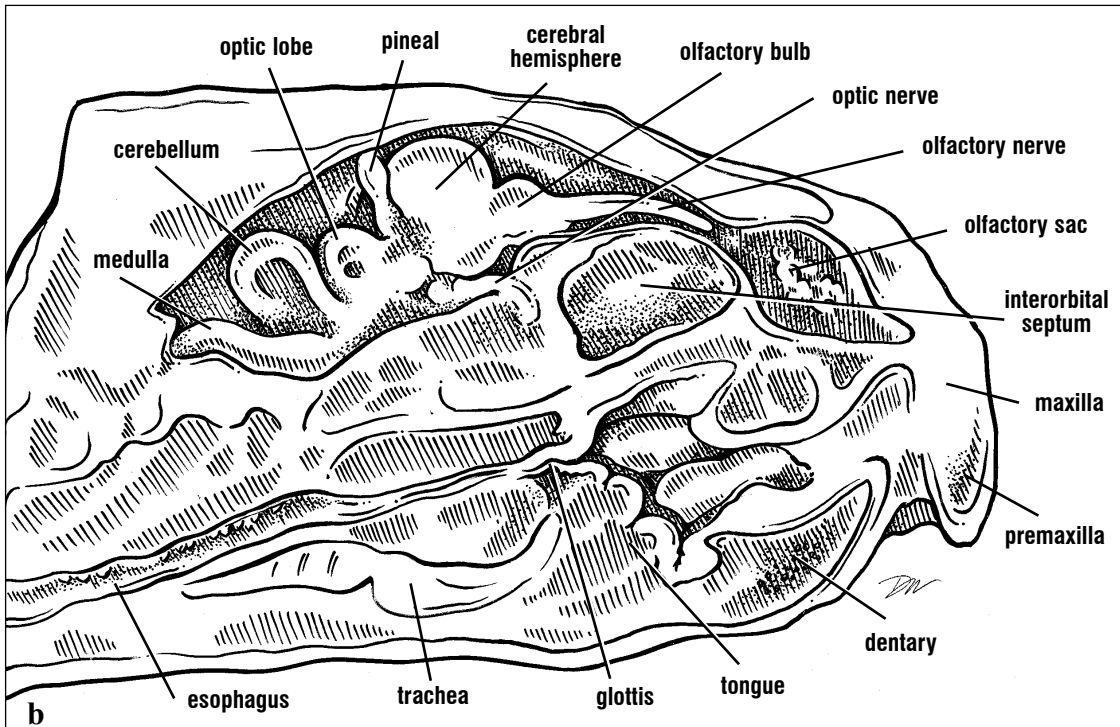
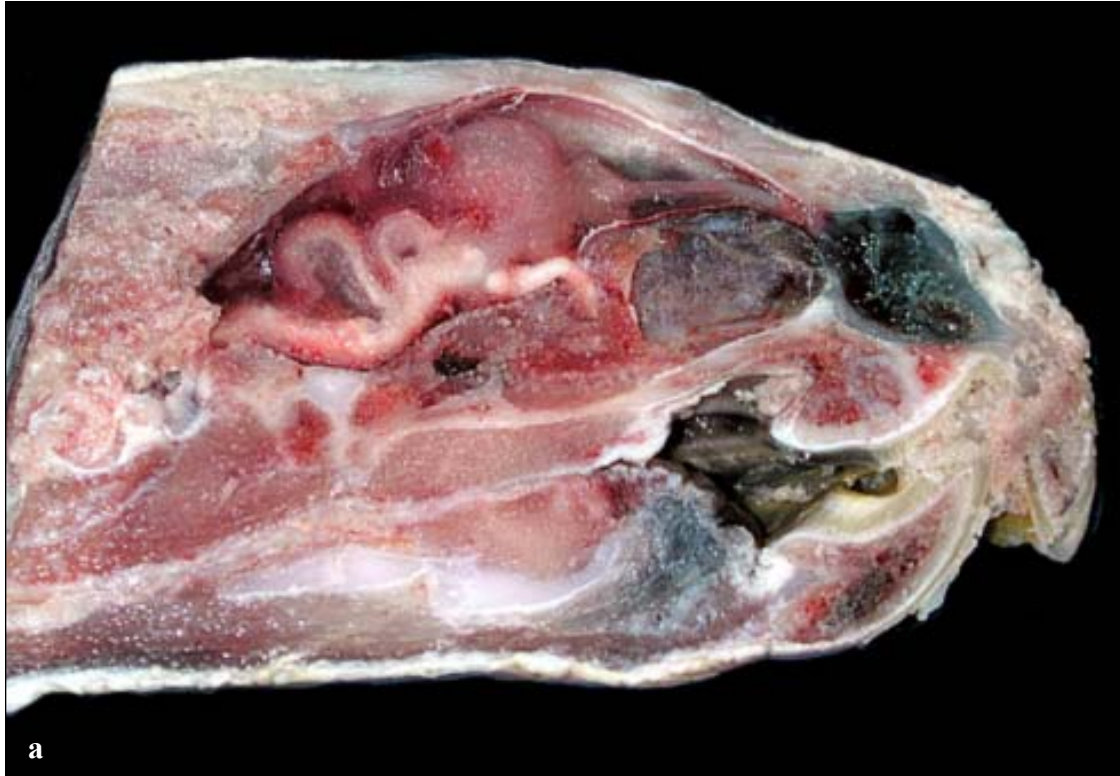Figs. 194a and 194b. Parasagittal cut through the head of a subadult loggerhead, close up. The positions of the brain, its parts, and the large subdural space containing cerebral spinal fluid relative to the dorsal skull are clear. The lateral ventricles are not exposed by this cut; the third ventricle and cerebral aqueduct are seen ventral to the optic lobe. The cerebellar ventricle is part of the 4th ventricle. Ventrally, the infundibulum leads to the pituitary (dorsal to the palate). The pituitary is housed in a bony socket, the sella tursica.



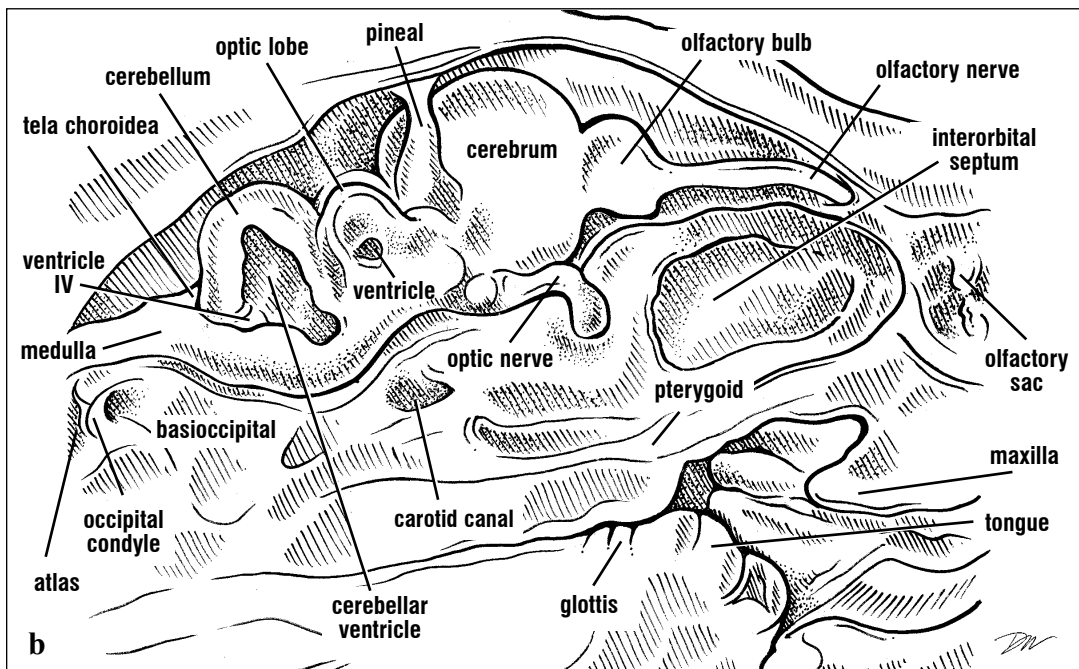
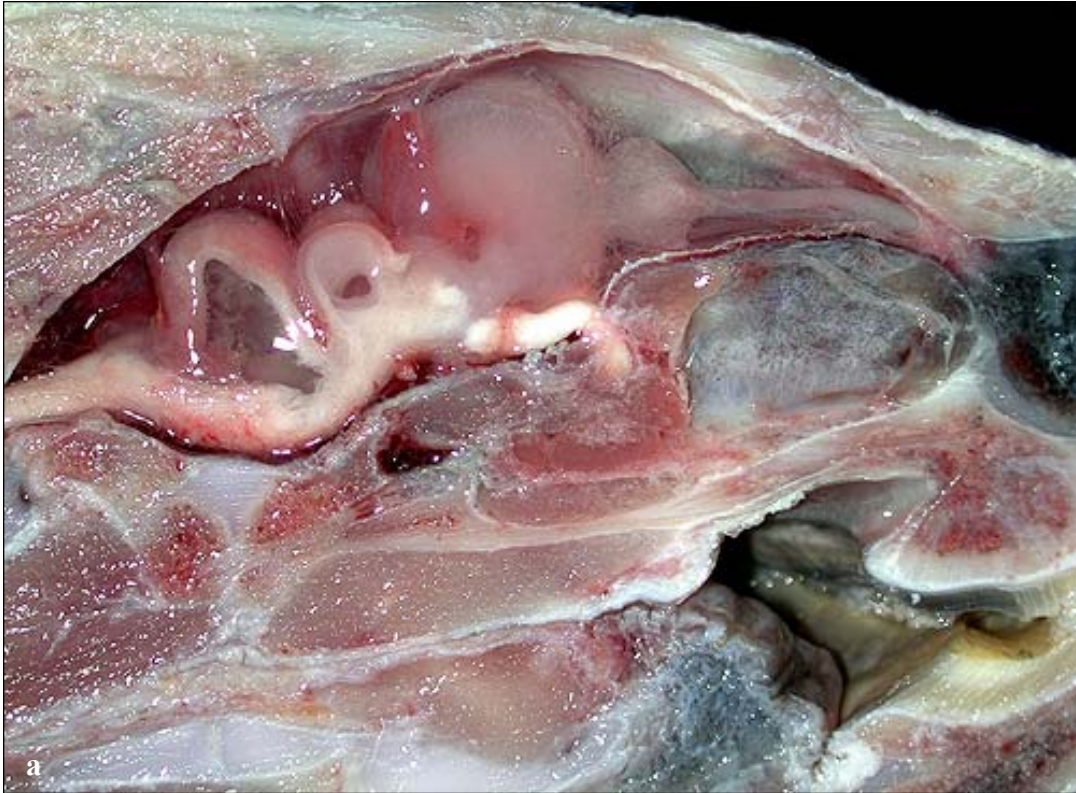Figs. 195a and 195b. Parasagittal cut through an immature green turtle head. This view shows the spatial relationships of the CNS to other head structures. The brain is located close to the dorsal skull. The cut removed part of the interorbital septum so that the eye muscles are exposed dorsal to the palate and posterior to the olfactory sac. The intact olfactory nerve can be seen extending to the olfactory sac.



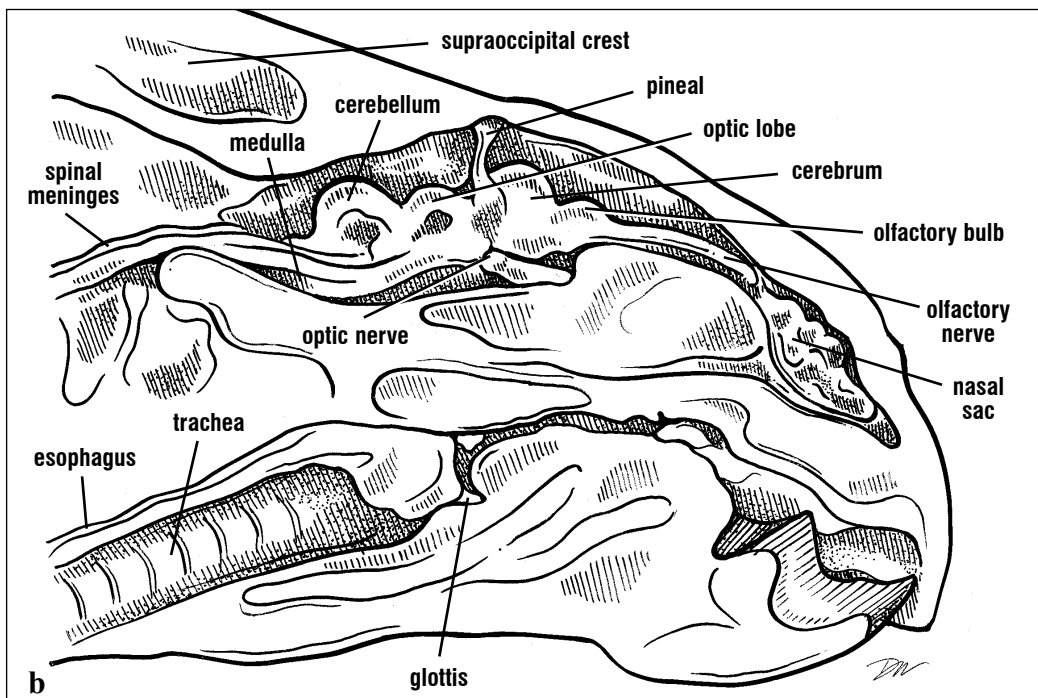
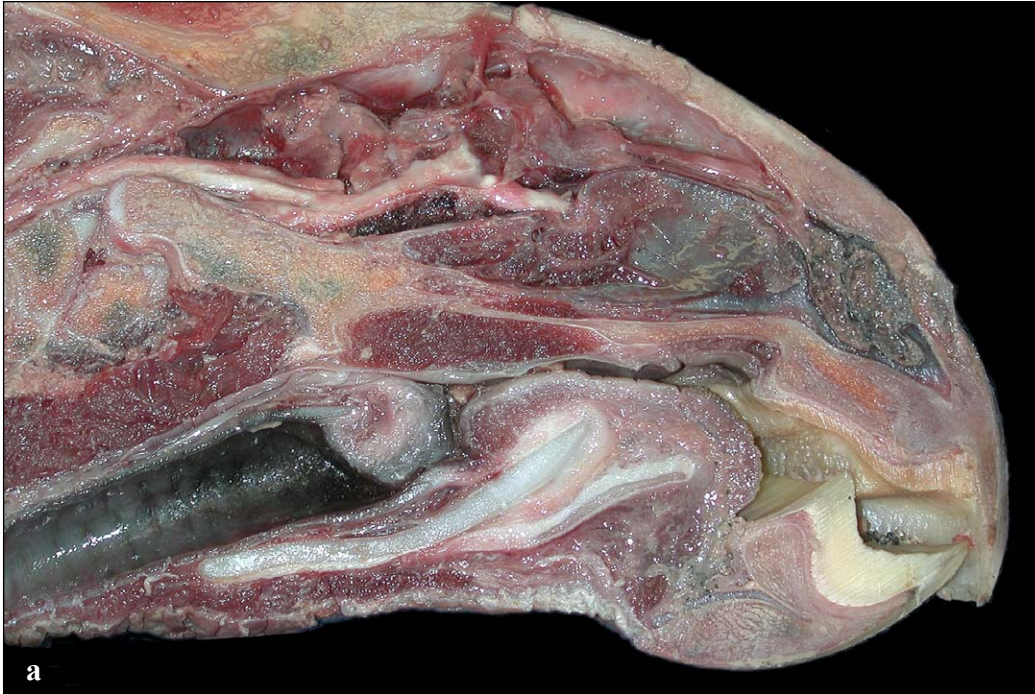Figs. 196a and 196b. Parasagittal cut through a subadult green turtle head (close up). The brain is located very close to the dorsal skull in green turtles. The lateral ventricles are just exposed by the parasagittal cut; part of the cerebral aqueduct is seen within and ventral to the optic lobe. The cerebellar ventricle, part of the fourth ventricle, is exposed.



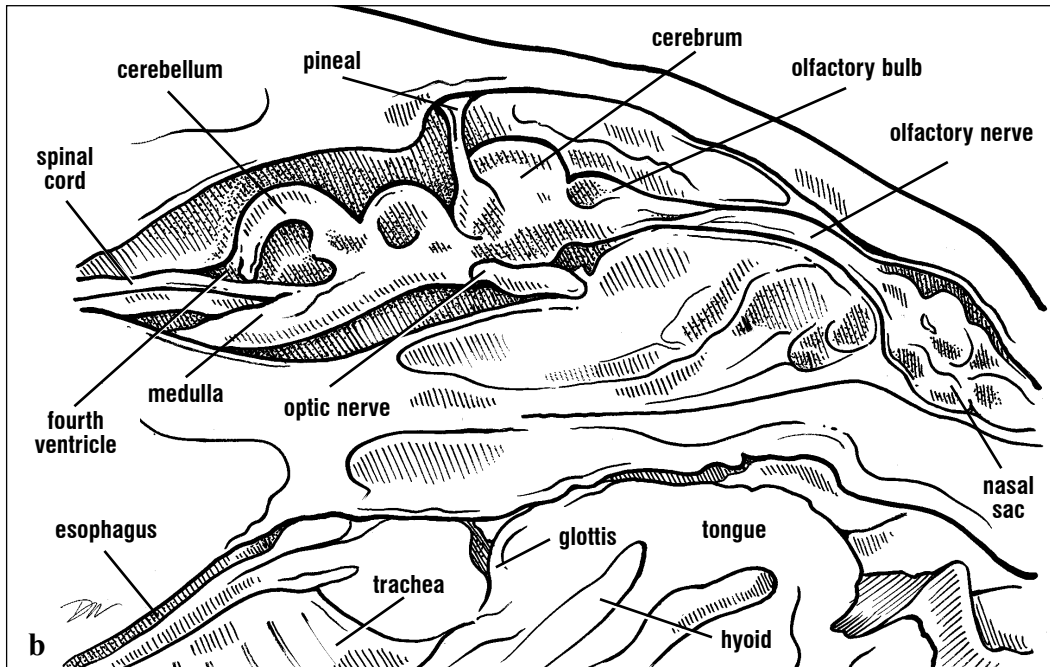
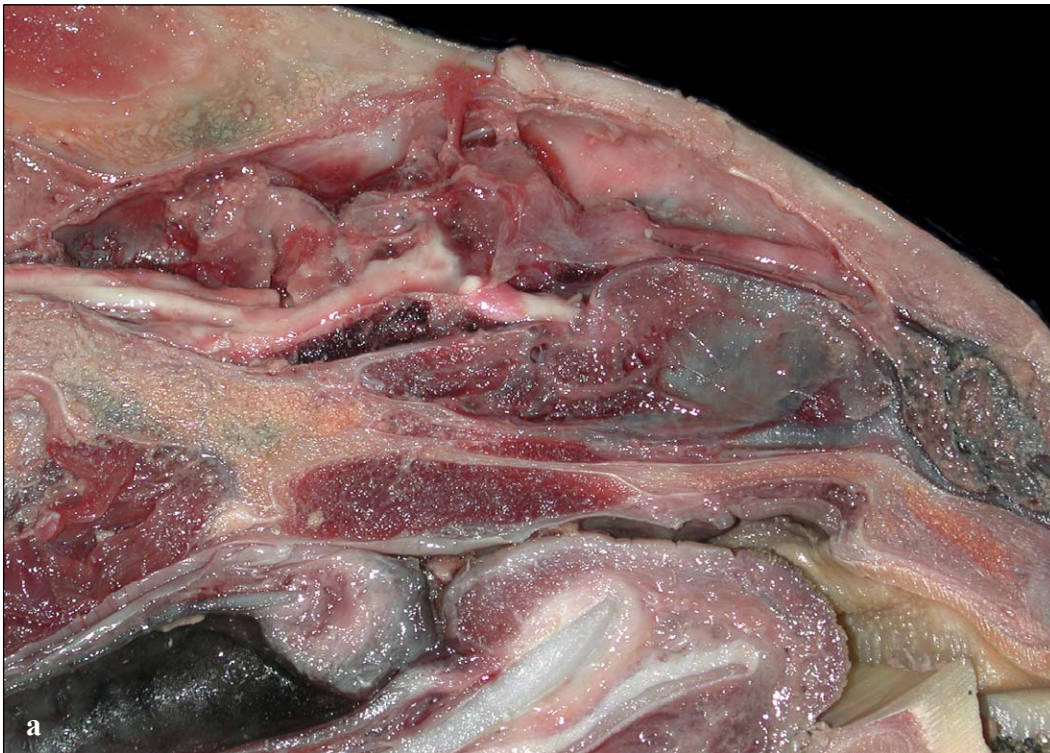Figs. 197a and 197b. Parasagittal cut through the head of an immature Kemp's ridley. The anterior half of the brain is flexed slightly dorsally in this species.



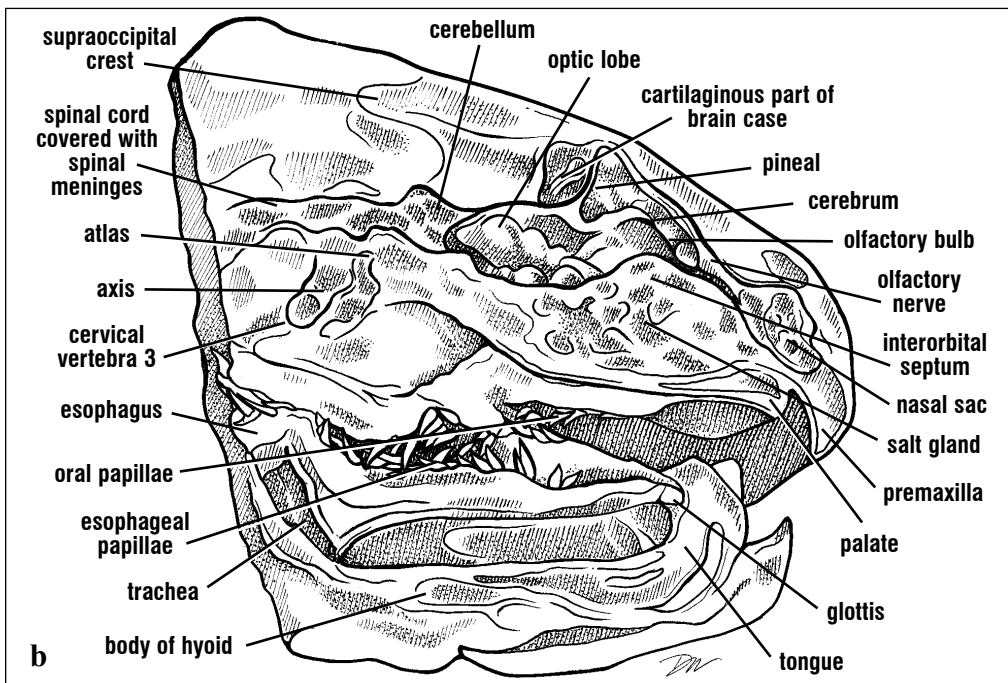
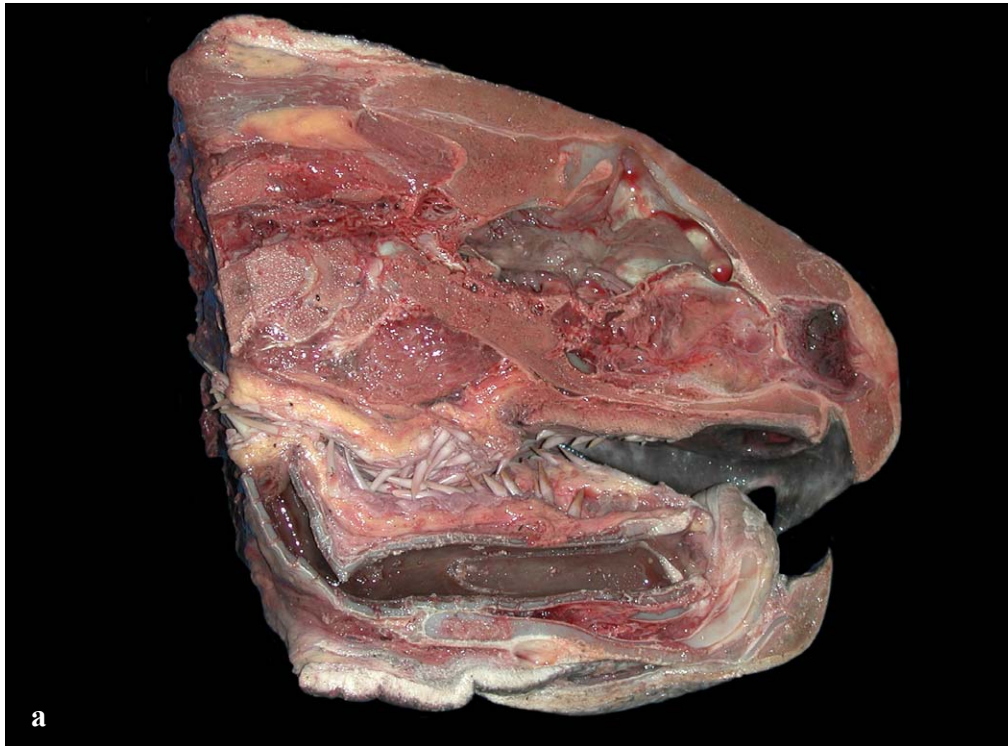Figs. 198a and 198b. Parasagittal cut near the midline of a juvenile Kemp's ridley turtle (close up). The cerebral hemispheres are closer to the skull roof bones in ridleys than in the other cheloniid species. The cut was positioned so that the optic chiasma (at the posterior end of the optic nerve) was bifurcated. The pituitary is not seen in this section.



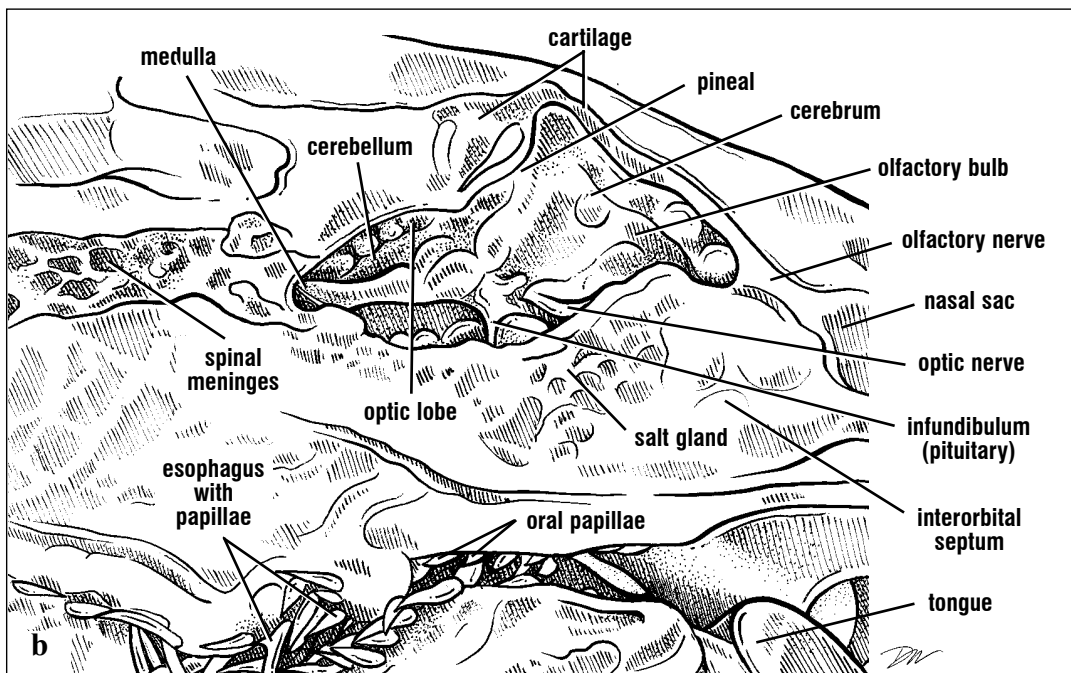
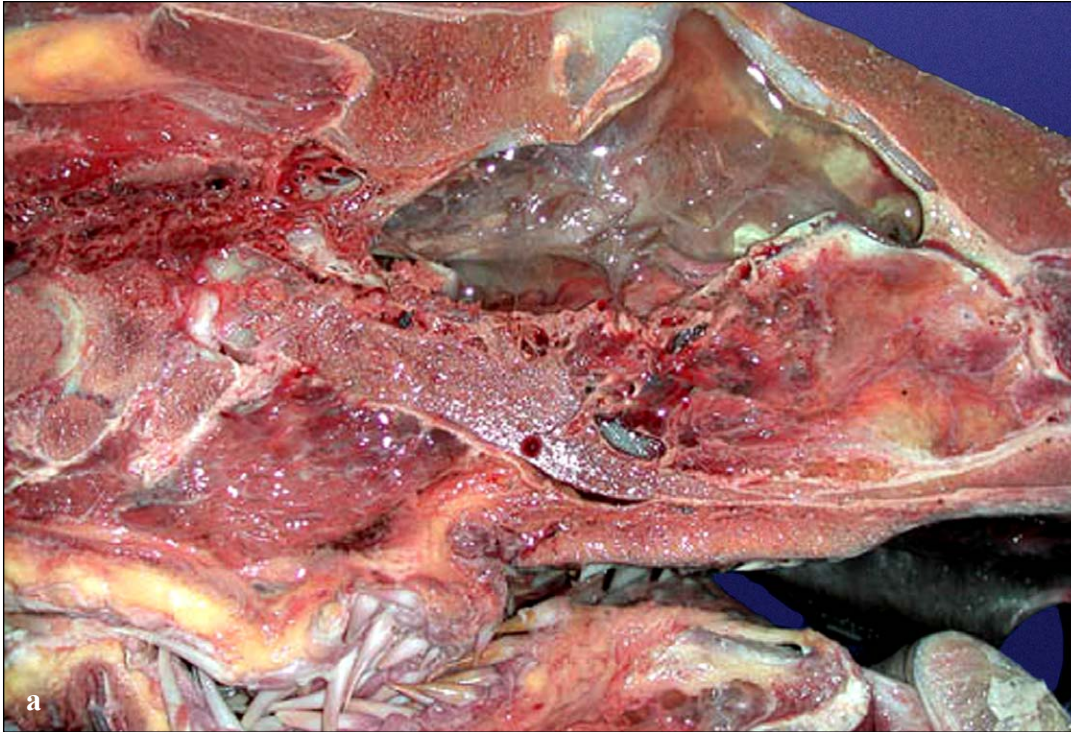
Figs. 199a and 199b. Parasagittal section through a hawksbill head. The brain is not as closely positioned to the skull roof in hawksbills as in other cheloniids. The pineal gland is clearly exposed in this dissection. Other parts of the brain are partially decomposed so their structure is slightly collapsed. The partial collapse makes the spinal meninges more distinct. The trachea and oral cavities are clearly exposed. The esophagus is collapsed in this specimen.



Figs. 200a and 200b. Parasagittal cut near the midline of a subadult hawksbill turtle (close up). The subdural space is relatively large in the hawksbills. In this dissection, the medulla was sliced so a portion is displaced ventrally to an abnormal position. Structures from other systems are clearly exposed in this dissection. The tongue, glottis, and trachea are shown with the supporting hyoid skeletal structure.



Figs. 201a and 201b. Midsagittal section of an adult leatherback head. The brain-case is largely cartilaginous around the dorsal and anterior aspects of the fore-brain and midbrain. The parietal and frontal skull bones cover this cartilaginous portion of the braincase. The brain is partially decomposed and has collapsed. The extremely hypertrophied salt gland is visible where a portion extends medial to the eye.



Figs. 202a and 202b. A midsagittal cut of an adult leatherback head (close up). The brain is partially decomposed, however the pineal is still attached to the skull roof dorsally and the infundibulum remains attached to the pituitary ventrally. The largely cartilaginous positions of the braincase are typical of leatherbacks.

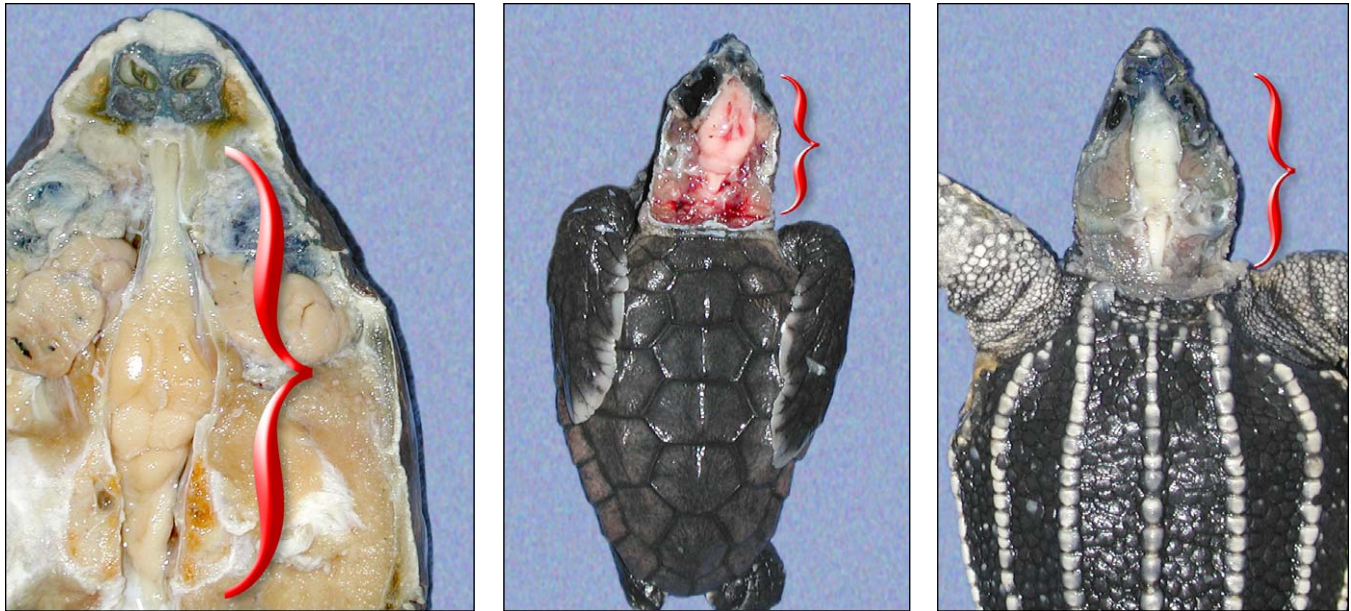


Fig. 203. Dorsal views of the brains of hatchling and juvenile turtles shows the negative allometric growth of the brain relative to the size of the head. Hatchlings have disproportionately large brains.

The relative sizes of parts of the brain vary through ontogeny. The brain is proportionately larger in hatchlings and juveniles than in subadults and adults (Fig. 203). The olfactory nerves become proportionately longer and the cerebral hemispheres, optic lobes, and cerebellum are proportionately smaller in subadult and adult turtles.

Peripheral Nerves -- The **spinal nerves** form the **peripheral nervous system**. They leave the spinal cord as paired dorsal and ventral nerve roots and exit the vertebrae via **intervertebral foramina**. The dorsal nerves are composed of **somatic** and **visceral sensory** nerve fibers and may contain motor fibers as well; the ventral roots are generally composed of both **somatic** and **visceral motor** nerve fibers. These nerves function as the autonomic nervous system. The autonomic nervous system of turtles has both **sympathetic** and **parasympathetic** components. However, these are not anatomically segregated as "thoracolumbar" sympathetic and "craniosacral" parasympathetic regions as in mammals. Hence, nerves arising along the length of the spinal cord may have both sympathetic and parasympathetic components.

Two networks of interconnected spinal nerves, the **brachial plexus** and **sacral** (= lumbosacral) **plexus**, are associated with control of the limbs. They are poorly described in the literature on sea turtles. In cheloniids they are formed by ventral nerve roots and their branches. The brachial plexus (Figs. 204-206) arises at the level of cervical vertebrae VI-VIII in sea turtles. These cervical nerves form a complex network innervating the pectoral, arm (humerus), and flipper muscles (Table 1) as well as sending branches to the respiratory muscles. Most muscles receive innervation from more than one branch of the plexus. A ventral branch of nerve VI makes a large contribution to the **median** nerve. Nerves VII & VIII give rise to the **inferior brachial** nerve, which immediately divides to form the **superficial radial** nerve and the **deep radial** nerve to the anterior shoulder and dorsal flipper. Next, the **supracoracoideus**, **subscapular**, and **ulnar** nerves arise and travel to those pectoral muscles and the ventral side of the flipper. The **deltoideus** nerve arises primarily from nerves (VI and VII).

There are no descriptions available for the brachial and sacral plexuses of *Dermochelys*.

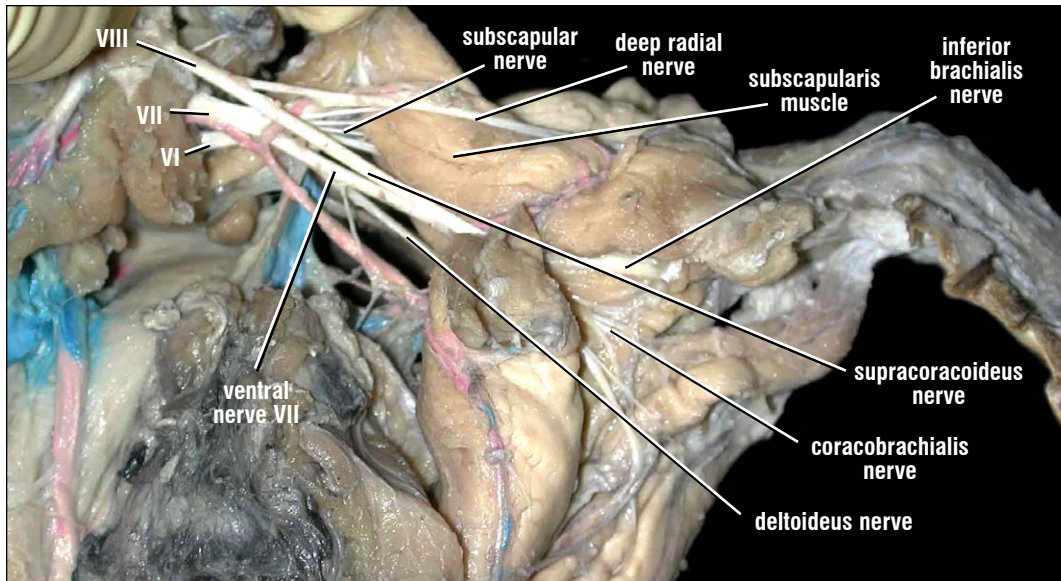


Fig. 204. The brachial plexus of a hawksbill. The brachial plexus arises from the most posterior cervical vertebrae. Its nerves innervate the pectoral muscles and flippers. The carapace and connective tissues have been removed to provide this posterodorsal view of the brachial plexus. Its 3 rami arise from the intervertebral foramina and immediately undergo a series of divisions and interconnections to form the nerves of the brachial plexus.

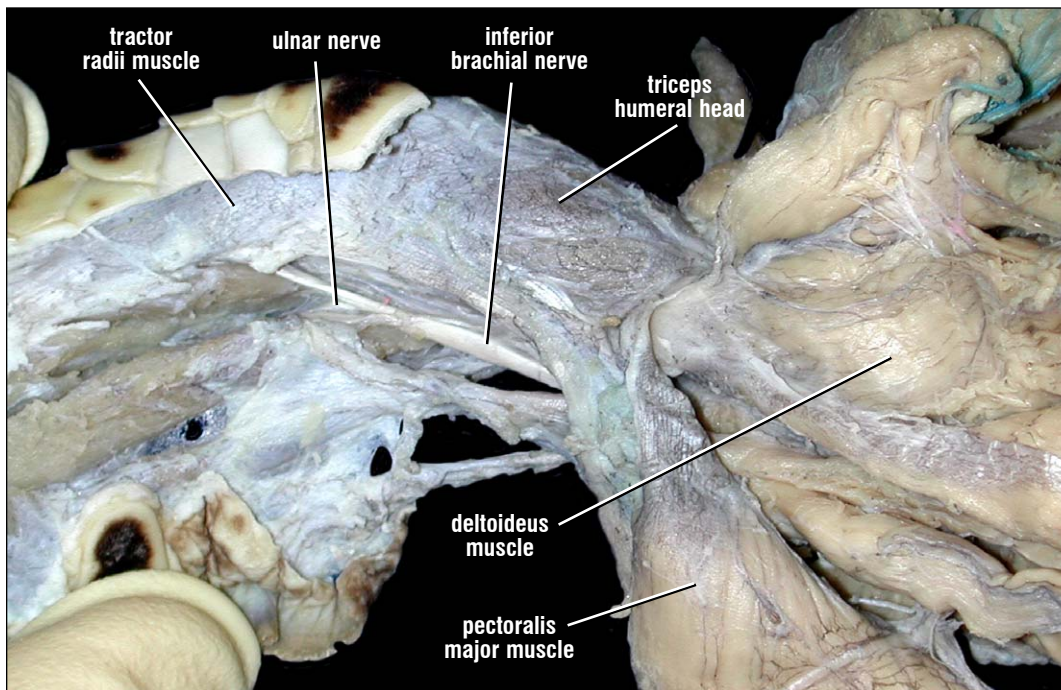


Fig. 205. Branch of the brachial plexus of a hawksbill (ventral view). The inferior brachial nerve of the brachial plexus travels along the ventral and anterior aspect of the flipper. The ulnar nerve is seen branching off. The other main nerve of the arm, the median nerve, is deep to the inferior brachial nerve and cannot be seen.

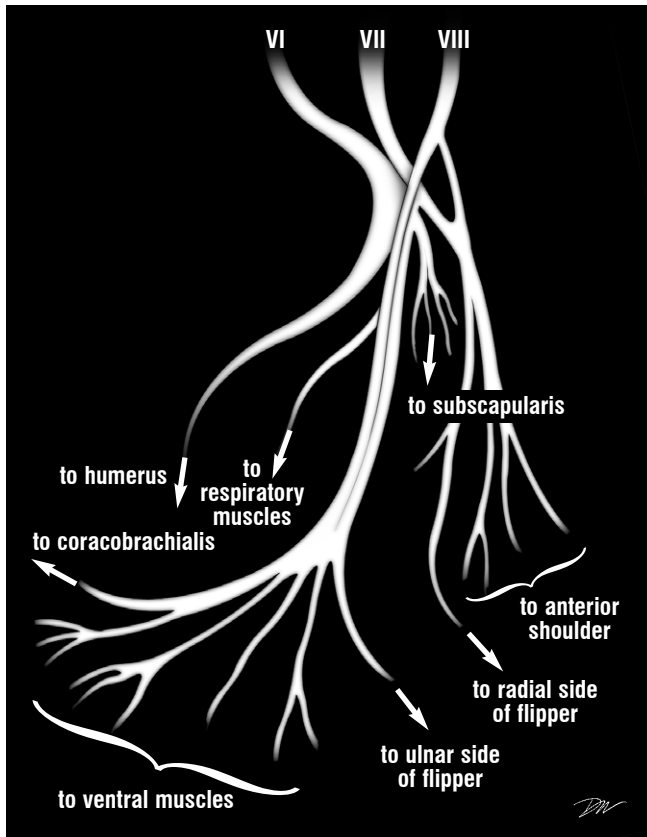


Fig. 206. *Diagram of the right brachial plexus based upon cheloniids. The three roots of the brachial plexus and their interconnections to the flipper and shoulder musculature are shown. Branches to ventral muscles go to the pectoralis, biceps superficialis, biceps profundus, and the deltoideus. Larger branches are shown as thicker lines. The most distal branches are not shown.*

The sacral plexus (Figs. 207-208) arises as 4 (sometimes 5-6) rami (branches) from spinal nerves XVII-XXI, located on the last dorsal and sacral vertebrae. These nerves interconnect and subdivide several times as they send nerves to the inguinal, pelvic, and hind leg muscles (Table 1). Many muscles receive multiple innervations. The more posterior nerves roots give rise to the

obturator nerve, going to the ventral pelvic muscles, and the **ichiadicus** nerve, which runs medial to the ilium and then divides to form the **peroneal** and **sciatic** nerves. The anterior two nerve roots interconnect provide major innervations (via **crural**, **femoral**, and **tibial** nerves) to the inguinal muscles, thigh adductors, and leg extensors.

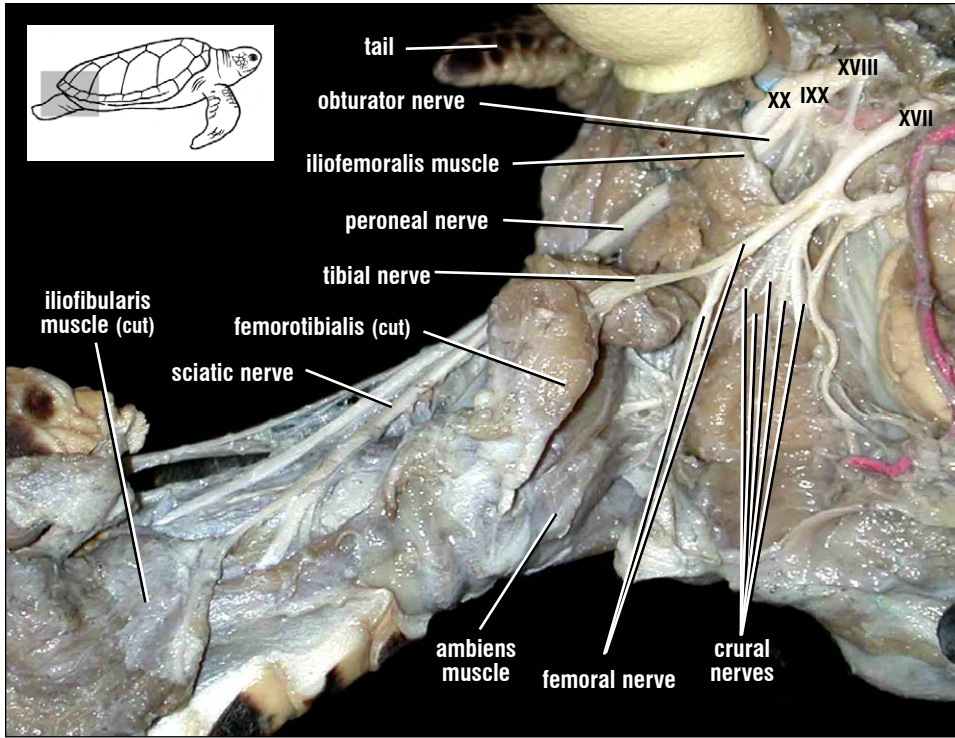


Fig. 207. The sacral plexus of a hawksbill. This lateral view of the sacral plexus shows four roots giving rise to the interconnecting nerves that innervate the hind limb and respiratory muscles of the inguinal region. The most posterior branch of the sacral plexus extends posteriorly, medial to the ilium, and then travels along the posterior hind limb. It gives rise to the sciatic, tibial and peroneal nerves that innervate many of the distal hind limb muscles.

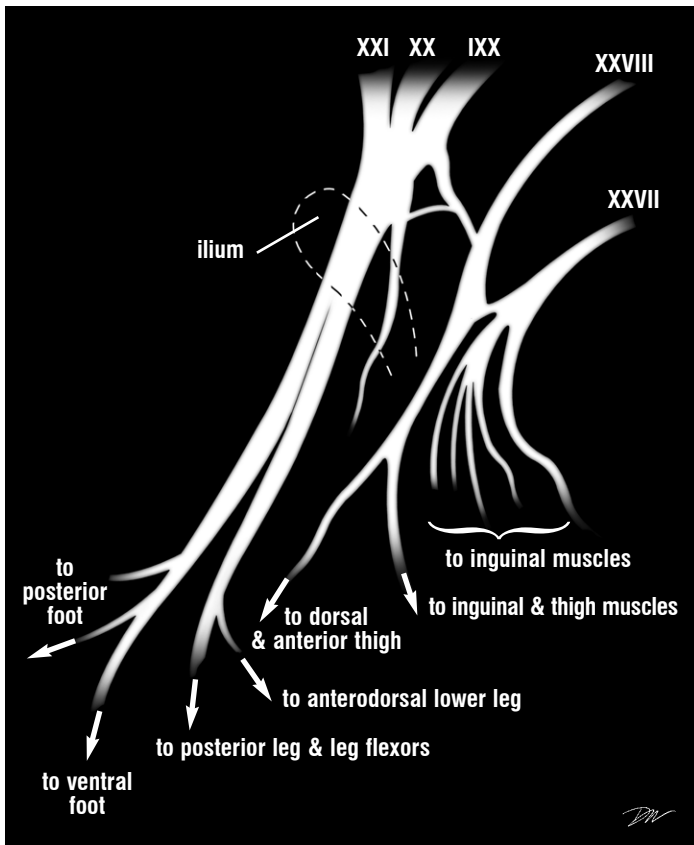


Fig. 208. Diagram of the right sacral plexus (lateral view) based upon cheloniids. The roots of the sacral plexus and their interconnections to the pelvic, inguinal, and hind limb musculature are diagrammed. Thicker lines represent larger branches. The most distal branches are not shown. The lone branch medial to the ilium is the obturator nerve to the ventral pelvic muscles.

NERVOUS SYSTEM

Brachial Plexus	Innervations
Inferior brachial nerve	Tractor radii
Superficial radial nerve	Latissimus dorsi
Deep radial nerve	Latissimus dorsi Supratoracoideus Testoscapularis
Supratoracoideus nerve	Supratoracoideus Pectoralis major Biceps brachii (profundus and superficialis)
Subscapular nerve	Subscapularis
Axillary (= Deltoideus) nerve	Deltoideus (ventral parts) Brachialis
Radial nerve	Latissimus dorsi Teres major Tractor radii Triceps brachii (humeral head) Respiratory muscles
Ulnar nerve	Deltoideus (dorsal head) Latissimus dorsi Subscapularis Extensor radialis Medial flipper muscles Extensors of digits
Median nerve	Coracobrachialis Flexor carpi ulnaris Flexors of digits
Sacral Plexus	Innervations
Crural nerve	Inguinal muscles Thigh protractors (Triceps femoris complex)
Femoral nerve	Puboischiofemoralis Dorsal hip muscles
Obturator nerve	Ventral hip muscles Caudiliofemoralis Ischiotrochantericus Adductor femoris Flexor tibialis (internus & externus) Pubotibialis complex
Ischiadicus nerve	Posterodorsal hip muscles
Sciatic nerve	Gastrocnemius Iliofemoralis Ventrolateral foot extensors
Peroneal nerve	Triceps femoris (ambiens, femorotibialis, Iliotibialis) Gastrocnemius Foot flexors
Tibial nerve	Flexor tibialis (internus & externus) Ambiens Pubotibialis Inguinal muscles Foot extensors

Table 1. Major innervations by the nerves of the brachial and sacral plexuses. Nerves are named using mammalian nerve terminology.

Sense Organs

Chemical, visual, acoustic, and vestibular senses of sea turtles are concentrated in the head.

The **tongue** (Fig. 209) is a muscular organ covered by a mucous membrane. Taste buds are present but are poorly characterized. The tongue lacks obvious lymphoid tissue at its posterior, as is seen in mammals.

The **nose** includes **external nares** leading to an **olfactory (nasal) sacs**. The olfactory sac communicates via the nasopharyngeal duct to the internal choanae (internal nares; Figs. 195 and 210). The olfactory sacs and **choanal folds** are covered with a ciliated sensory epithelium. The olfactory epithelium, located posterodorsally in the nasal cavity, is innervated by the olfactory nerve leading to the olfactory bulb (Figs. 189, 193-201). The **vomerinal organ** (Jacobsen's organ) of turtles is not typical in its structure. This specialized sense organ, usually associated with detection of airborne and substrate-borne odor molecules, is not recessed in a separate pit as in snakes and some lizards. It is widely distributed anterolaterally and ventrally in

the olfactory sac. The vomeronasal organ is distinguished from olfactory epithelium by region and histological characteristics rather than gross appearance. It is innervated by nerves running to

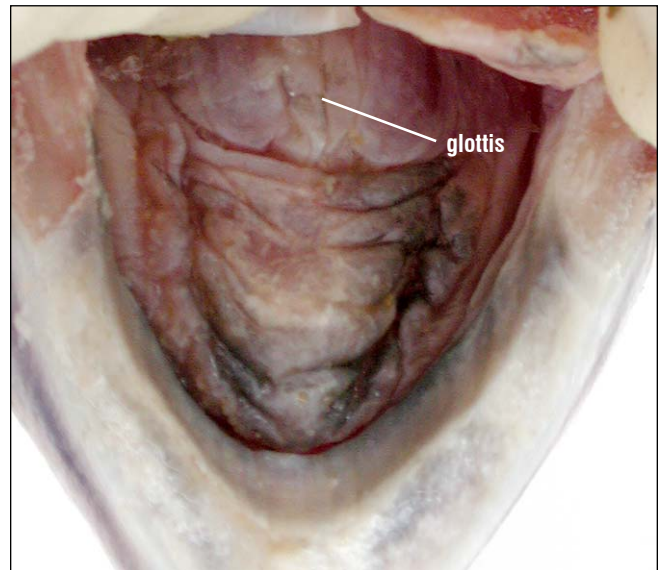


Fig. 209. Dorsal view of the tongue of the Kemp's ridley. The tongue is muscular and attached to the floor of the mouth. The surface is grossly smooth. The epithelium is covered in small, short, flat papillae.

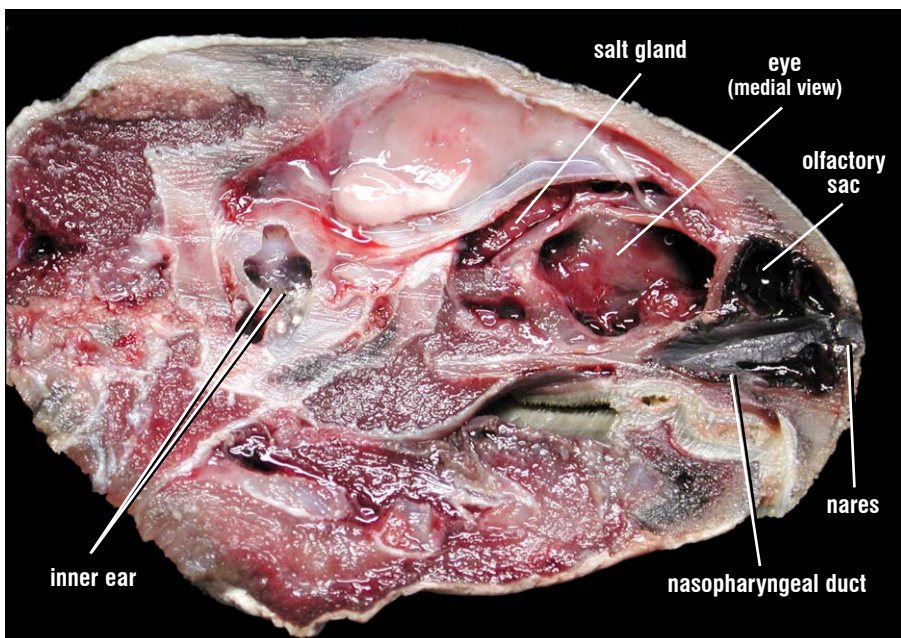


Fig. 210. The sense organs of a green turtle. The nares lead to large pigmented olfactory sacs. There are several choanal folds on the walls of the olfactory sac, which lack bony supports. The olfactory sac leads, via the nasopharyngeal duct to the internal choanae. The olfactory nerve is cut in this dissection and has fallen ventrally. The inner cavity is cut ventral to the brain; the cochlea is also cut and part is exposed at the ends of the inner ear pointers. The middle ear is located more laterally and hence is not seen in this view.

SENSE ORGANS

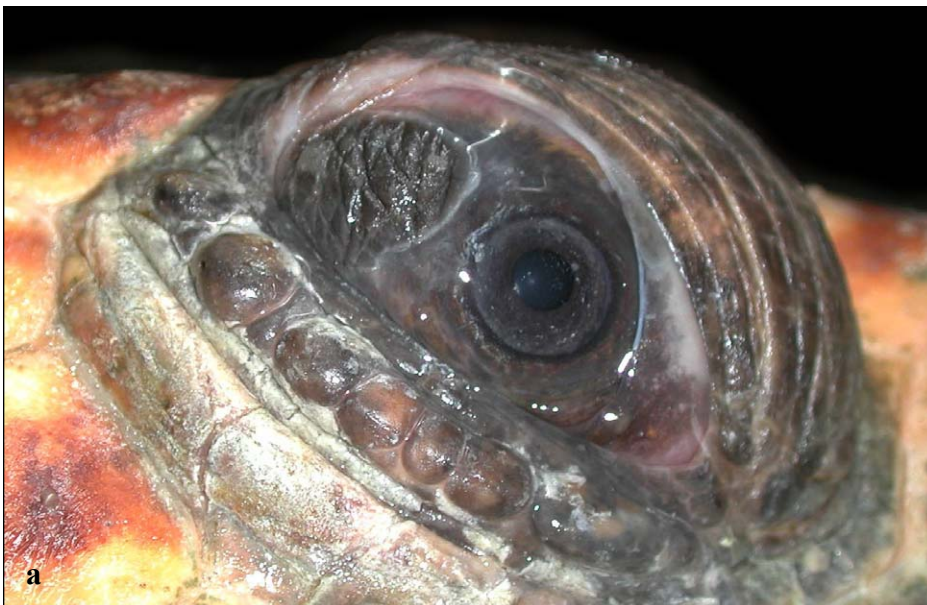the accessory olfactory bulb (effectively the dorsal part of what is grossly called the olfactory bulb).

A series of small spike-like papillae line the lateral margin of the internal choane in *C. mydas*. These papillae are absent or poorly developed in other species.

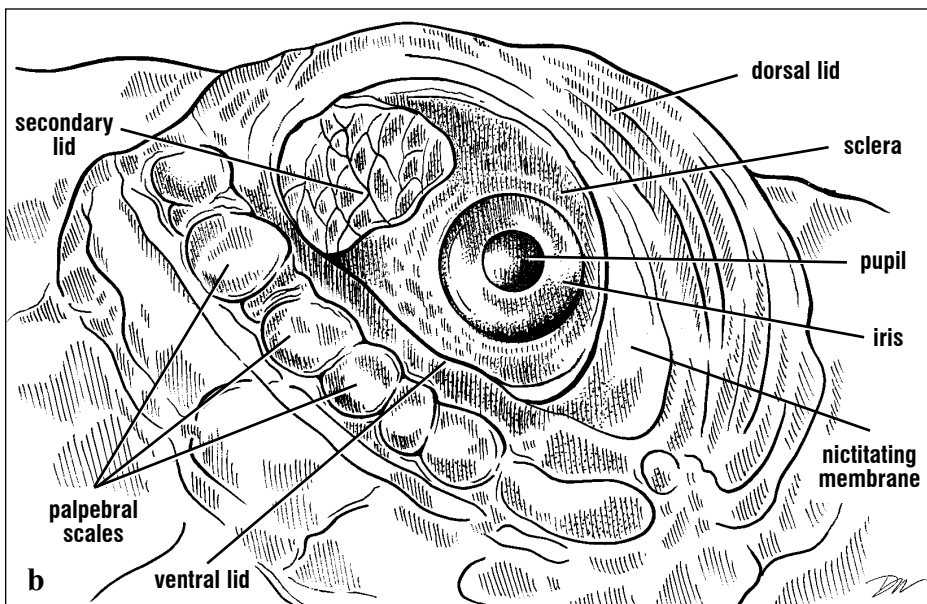
The anterior tissue lining the nares is highly vascular and erectile in adult sea turtles. It appears not to

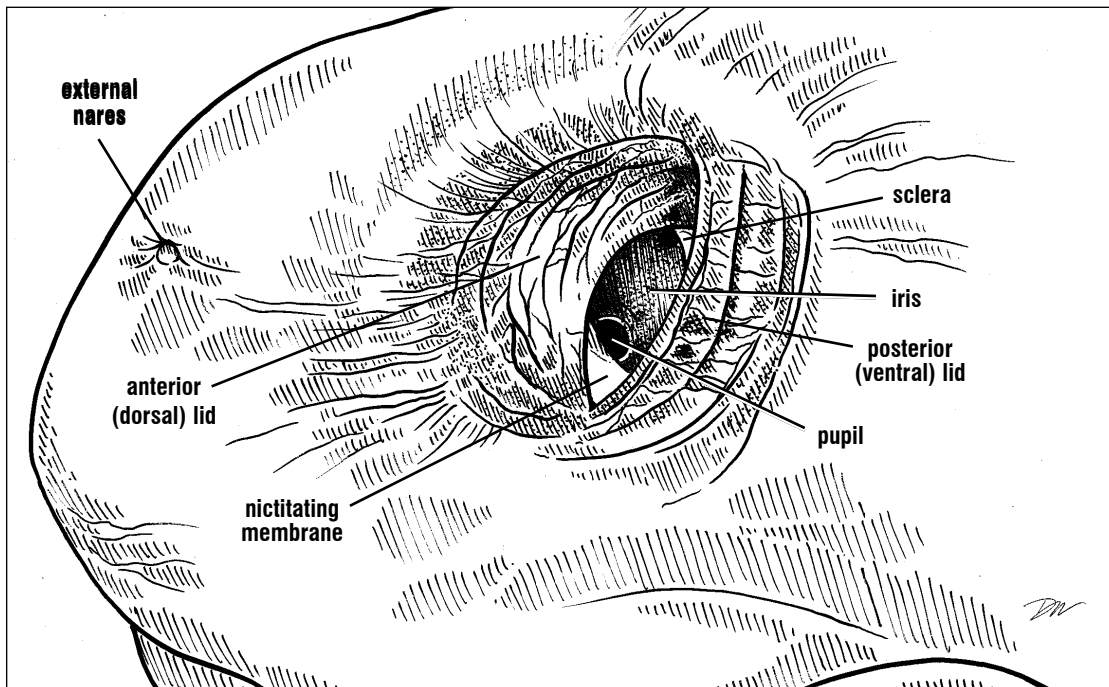
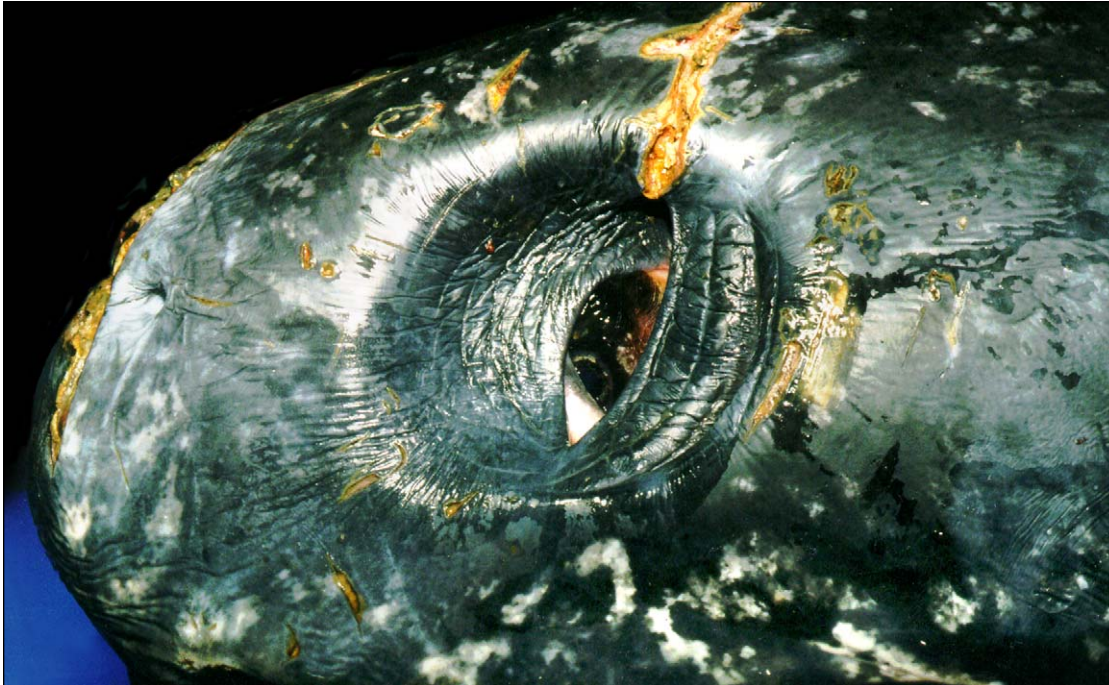have a sensory function but instead has the ability to seal the nostrils when the turtles are submerged.

The **eyes** of sea turtles are round and housed in bony orbits. The eye is protected by **dorsal** and **ventral lids**. The ventral lid is continuous with the **conjunctiva**, which forms its inner surface. The **nictitating membrane**, at the anterior and ventral corner of the eye, also is continuous with the conjunctiva (Figs. 198-200).



Figs. 211a and 211b. *Eye and lids of a loggerhead.* The eyes are located dorsally and anterolaterally. They have overlapping fields of view (hence, binocular vision). The dorsal and ventral lids are keratinized and mobile. The secondary lid is also keratinized but not mobile. The cornea, not labeled, is a clear portion of the sclera that overlies the iris and pupil. Palpebral scales are found in the margins of the ventral lid in cheloniids, but not in Dermochelys.





Figs. 212a and 212b. *Leatherback eye. The lids of the leatherback eyes are positioned as more anterior and posterior lids than dorsal and ventral lids.*

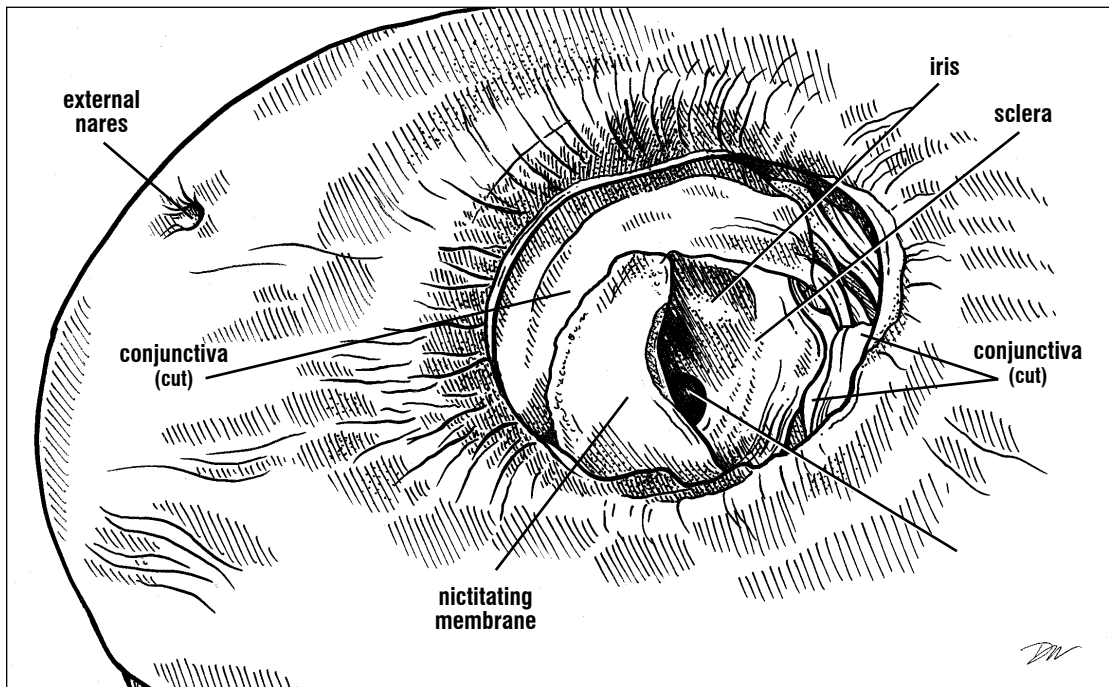
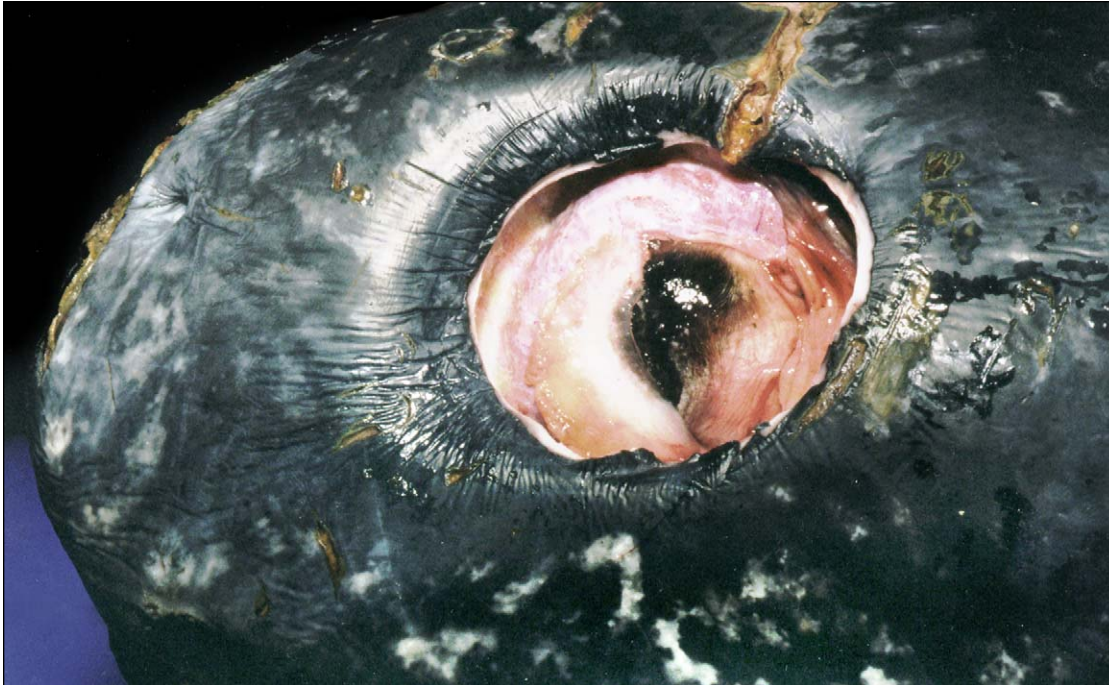

Fig. 213. *Leatherback eye dissection. The lids of this leatherback eye were removed to show the extent and position of the nictitating membrane.*

SENSE ORGANS

The wall of the eye (or globe) is composed of 3 major layers: the **sclera**, **uvea**, and **retina**, surrounding the viscous **vitreous body**. The eye is supported medially by cartilage and laterally by **scleral ossicles** (Figs. 82-84). The outer-most layer is the **sclera**. The eye muscles attach to the sclera (Figs. 215-216). The **superior oblique muscle** inserts dorsally and it is innervated by the **trochlear nerve**. The **superior rectus** muscle attaches posteriorly. Ventral to these muscles is the

attachment of the **internal rectus** muscle. Anteriorly, the **pyramidalis** muscle extends from the eye to the eyelids and nictitating membrane. Deep and ventral to the pyramidalis muscle are the **inferior oblique** and **inferior rectus** muscles. The **external rectus** muscle is located posteriorly and ventrally and is innervated by the **abducens nerve**. The superior rectus, inferior rectus, inferior oblique and internal rectus muscles are all innervated by the **oculomotor nerve**.

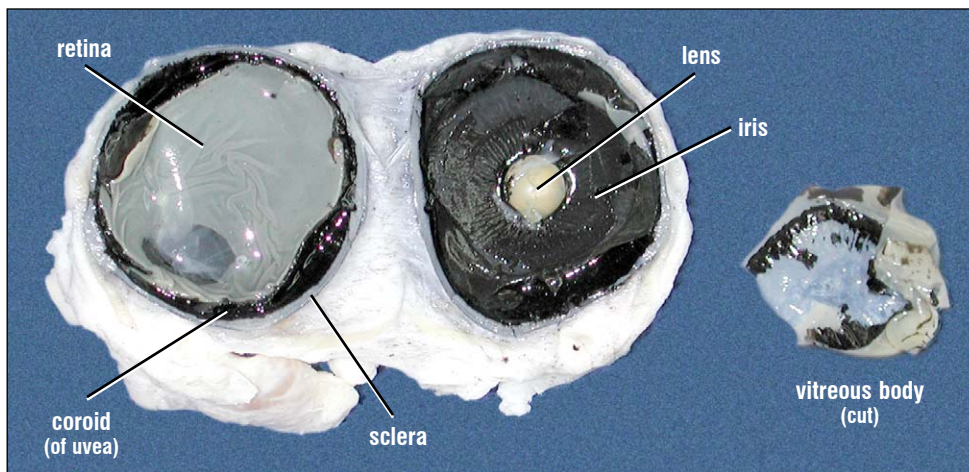


Fig. 214. *Sagittal section of a loggerhead eye. The eye is cut into medial and lateral halves. The retina and back of the eye are on the left. The inside of the iris, lens, and pupil are in the middle of the photo. Part of the vitreous body was removed and placed on the right.*

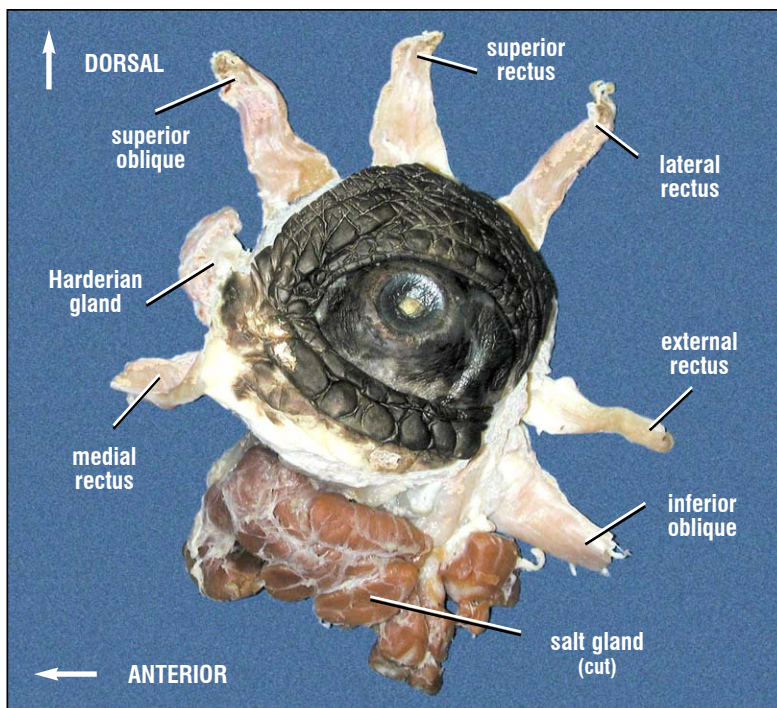


Fig. 215. *Lateral view of a loggerhead left eye. The extrinsic eye muscles are extended radially in this picture to show their relative insertion points. Normally their origins would converge on the interorbital septum.*

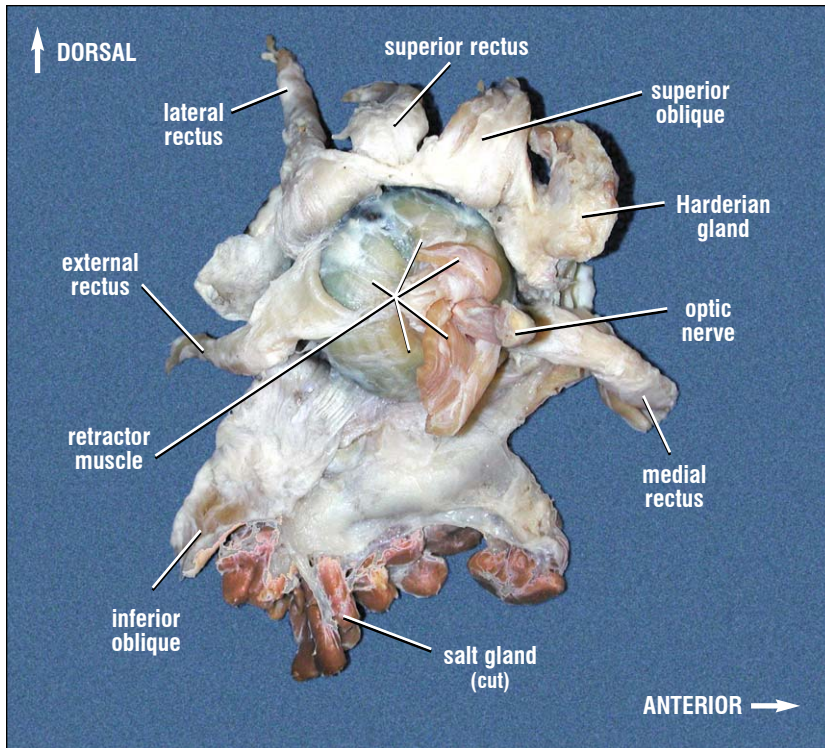


Fig. 216. Loggerhead left eye (medial view) showing extrinsic eye muscles. The extrinsic eye muscles are responsible for eye movements. Also shown is the Harderian gland, which lubricates the eye and a portion of the salt gland (an organ primarily responsible for salt excretion and maintaining water balance). The retractor muscle surrounds the optic nerve and positions the eye deeply or shallowly in the orbit.

The sclera, often termed the "white of the eye" in vertebrates, is partially pigmented in most sea turtles. The sclera is clear at the front of the eye; there it is termed the **cornea**. Internal to the sclera is the uvea, composed of the **choroid**, **tapetum lucidum**, **ciliary body**, and the **iris** (Fig. 199). The choroid is pigmented and extends from the iris to the retina. It includes the reflective material (tapetum lucidum) that is responsible for "eye-shine". The reflective material enhances the eye's sensitivity under low light conditions. The ciliary body (not shown), is responsible for changing lens shape during visual accommodation. It extends from the choroid near the front of the eye, to the attachments that suspend the lens. The iris is pigmented brown or black and extends from the choroid across the front of the eye. The **limbus** (= limbas) is the tissue between the cornea and the sclera. Because the cornea and sclera are continuous with one another, the limbus represents a transitional zone that is usually described histologically (not labeled in the figures). The free border of the iris forms the edge of

the **pupil**. The **lens** is strongly curved in sea turtles (Fig. 214). It is suspended behind the pupil and iris by "ligaments" attached to striated muscles of the ciliary bodies. The chamber of the eye is filled with a clear viscous liquid, the **vitreous body**.

The eyes are photoreceptors that are capable of color and shape discrimination. The **retina** is the sensory layer of the eye; it detects color as well as brightness. The retina is composed of several cell layers and includes several types of rods and cones, each containing photopigments.

The **ears** of sea turtles are responsible for hearing and equilibrium. Each ear consists of an external **tympanum** covered by a tympanic scale that stretches across the **otic notch** (= auditory canal) formed by the quadrate, quadratojugal and squamosal bones (Fig. 28). There is middle and inner ear but no outer ear. The **middle ear** is involved in sound transduction while the **inner ear** functions in sound reception and the detection of

position and acceleration. The middle ear contains a single ear bone, the **stapes** (= columella). The stapes extends from the tympanum via an **extrastapedial process** of cartilage (Fig. 217), through the **tympanic cavity** and **recessus cavi tympani**, to articulate via an expanded footplate (also cartilage) on the **vestibular window** of the **cochlea** (Fig. 218). A Eustachian tube extends to each middle ear from the mouth near the jaw joints (Fig. 165).

The inner ear of turtles is composed of the cochlea and 3 semicircular canals, all of which are encased in bone. The cochlea is involved in sound transduction and is innervated by the auditory nerve; it transmits sound information to the brain. The semicircular canals sense the head's position and movement by detecting changes in acceleration in the three planes. One canal resides in each plane (sagittal, coronal, and axial) in each ear.

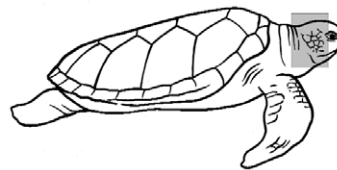
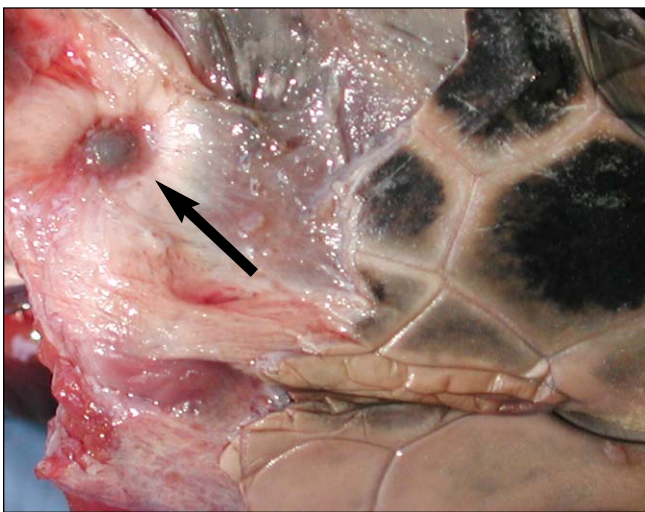


Fig. 217. *The tympanum of a ridley ear. The tympanic scale has been removed to expose the tympanum and the distal-most aspect of the extrastapedial process (at arrow).*

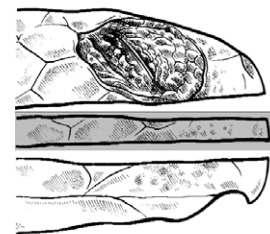
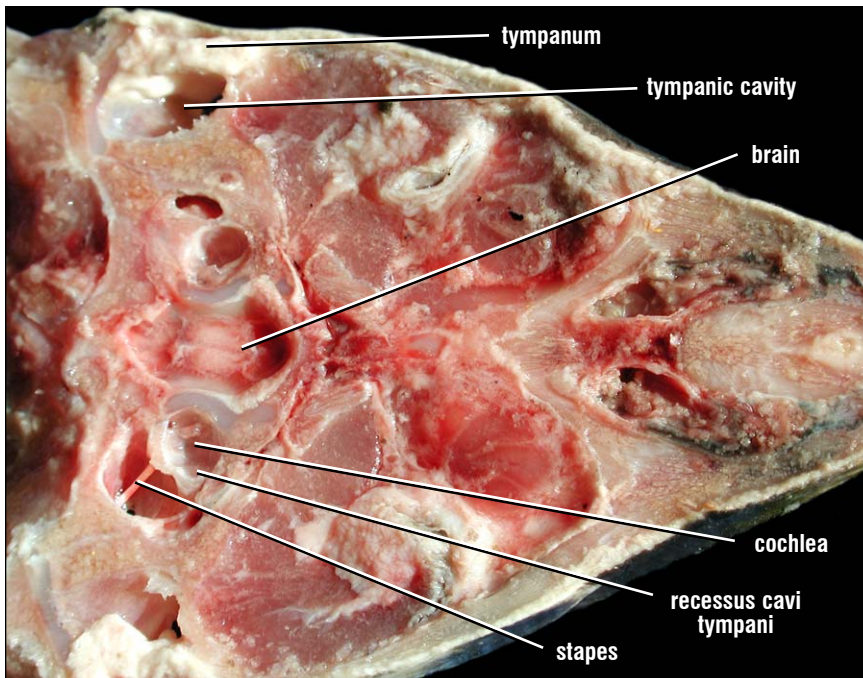


Fig. 218. *Ventral view of a ridley ear. The coronal section exposes the tympanic cavity (= the otic notch of a skull) and, more medially the recessus cavi tympani. The footplate of the stapes articulates with the vestibular window.*

Urogenital Anatomy

The **urogenital system** (UG) is made up of the **kidneys**, **ureters**, **gonads** and their ducts, the **urinary bladder**, and derivatives of the **genital papilla** (penis or clitoris) in the floor of the cloaca. The kidneys function in removal of nitrogenous wastes (excretion) and maintaining water and electrolyte balance (osmoregulation). The ureters transport nitrogenous wastes to the cloaca where it either drains into the urinary bladder or is eliminated. The gonads (**ovaries** or **testes**) produce gametes and their ducts

Excretory System. The kidneys are paired, lobular, elliptical red structures that are located retroperitoneally (between the peritoneum and the shell). Sea turtle kidneys are **metanephric**, meaning (1) they arise from the posterior part of the nephric ridge in the embryo and (2) the kidney tubules are drained by ureters (metanephric ducts). The ureters extend from the kidney, through the peritoneum and empty into the dorsal cloaca on each side. Ureters are located on the ventral

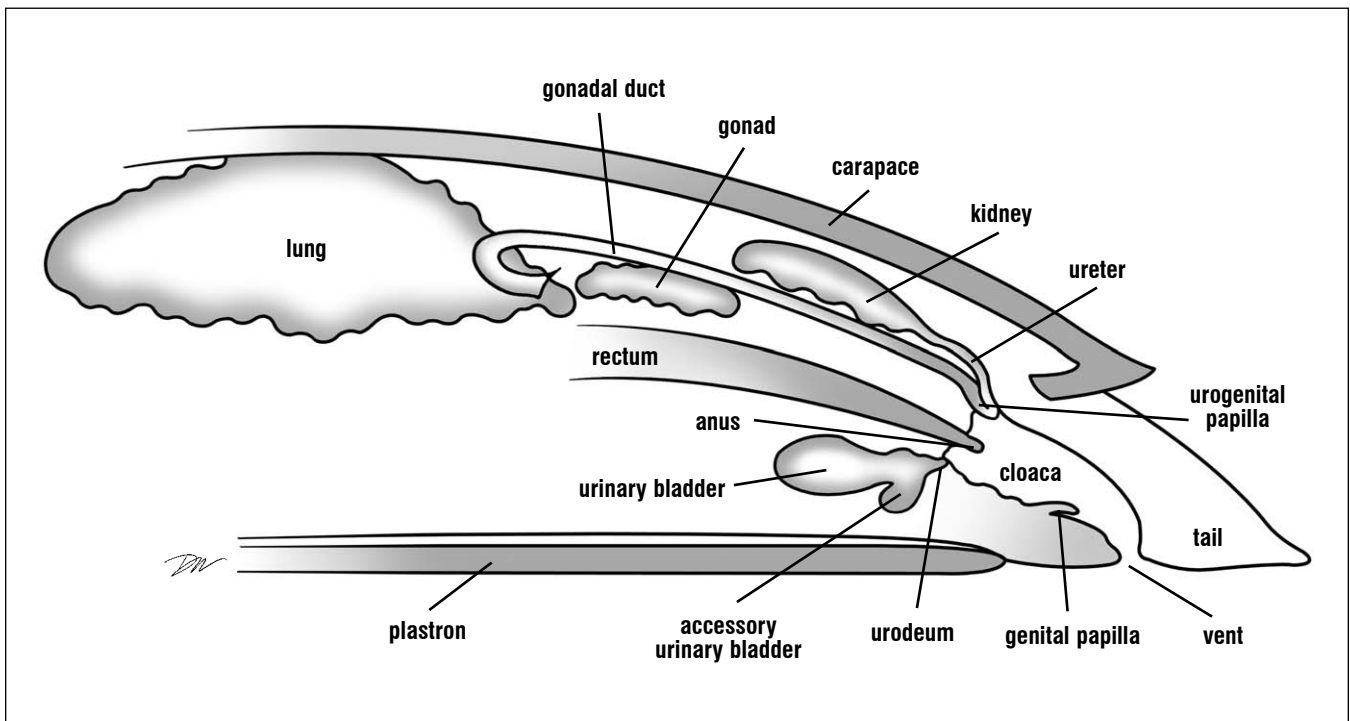


Fig. 219. Diagram of the Urogenital System. The relative positions of the kidneys, gonads (undifferentiated for diagrammatic purposes),

accessory ducts, urinary bladder, rectum and cloaca are shown. Anterior is to the left.

transmit eggs or sperm to the cloaca. They are reproductive structures. The urinary bladder functions in water and urine storage. The cloaca is the common chamber into which the ureters, gonadal ducts, rectum, and bladder empty. The cloaca leads to the outside of the body via the vent.

surface of each kidney. They drain uric acid, ammonia, and water to the cloaca. Each ureter enters the cloaca with a gonadal duct via a **urogenital papilla** in the **urodeum** portion of the cloaca (Figs. 219 - 220).

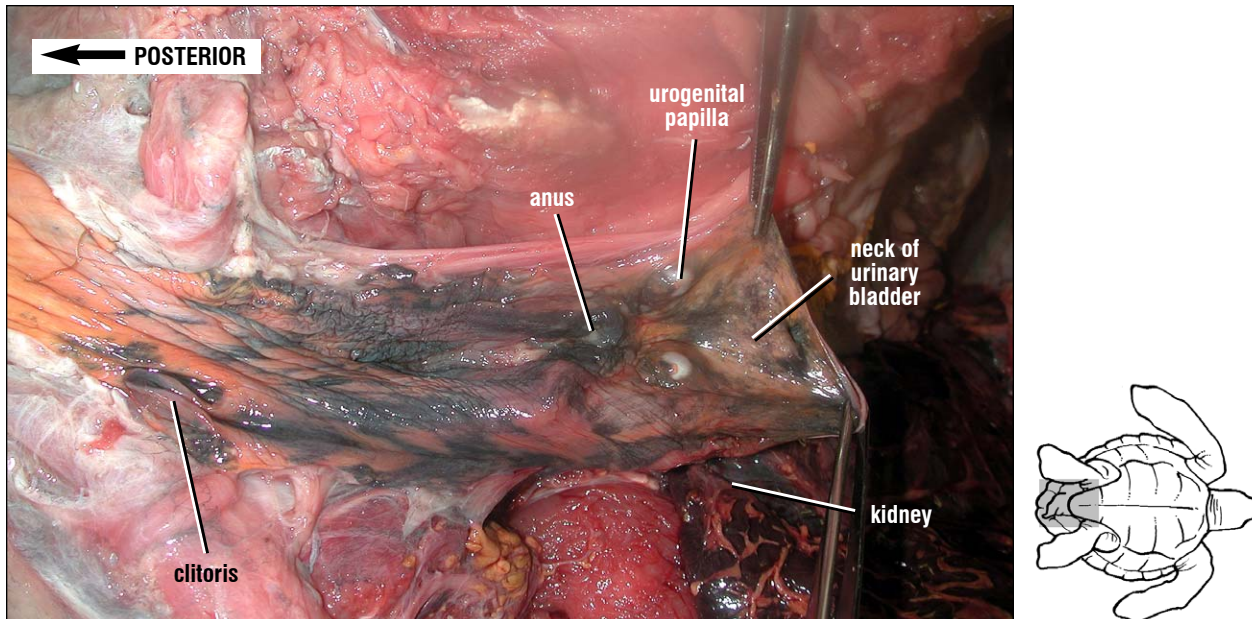


Fig. 220. Lateral view of the cloaca of an immature hawksbill. The lateral wall of the cloaca has been cut away to show the urogenital papillae from the oviducts and ureters, the opening to the urinary bladder, and the dorsally positioned anus from the rectum. The urinary and genital ducts enter the cloaca adjacent to one another in females. They are small and located as the lateral walls of the urogenital papillae.

The kidneys of sea turtles lack a distinct **cortex** and **medulla**. Sea turtle nephrons are composed of a **renal capsule**, **proximal tubule** (which is linked to water transport and protein synthesis), an **intermediate segment** (function unknown), **distal convoluted tubule** (responsible for fluid reabsorption) and **collecting tubule** (draining to the ureters). There is no loop of Henle as is found in mammalian nephrons. Unlike higher vertebrates, marine turtles retain the ability to form new functional nephrons as they mature (and perhaps throughout life).

Blood flows through the kidneys from afferent vessels entering (renal arteries and iliac veins), and efferent vessels leaving (renal portal and renal veins) the kidneys. Water and mineral waste (a filtrate) is removed from the blood at the renal corpuscle (glomerulus plus renal capsule).

The urinary bladder is a highly elastic, single,

sack-like structure located along the midline of the pelvis. It opens via a single opening to the ventral floor of the cloaca (Figs. 219-221). The bladder is located ventrally and urine, water, and sometimes other waste products may enter it via the cloaca. This anatomical position and the connection of the cloaca to the outside sometimes allows materials other than urine (e.g., fecal material, parasites, or, in females, eggs) to enter opportunistically.

Sea turtles have two small **accessory urinary bladders** connected to the urinary bladder; each located lateral to the neck of the urinary bladder and dorsal to the pubis (Fig. 221). They are seldom filled and often are missed in dissections.

Gonads. The gonads of both species are located dorsally in the body cavity, posterior to the lungs, and ventral to the kidneys and peritoneal wall (Figs. 222 and 223).

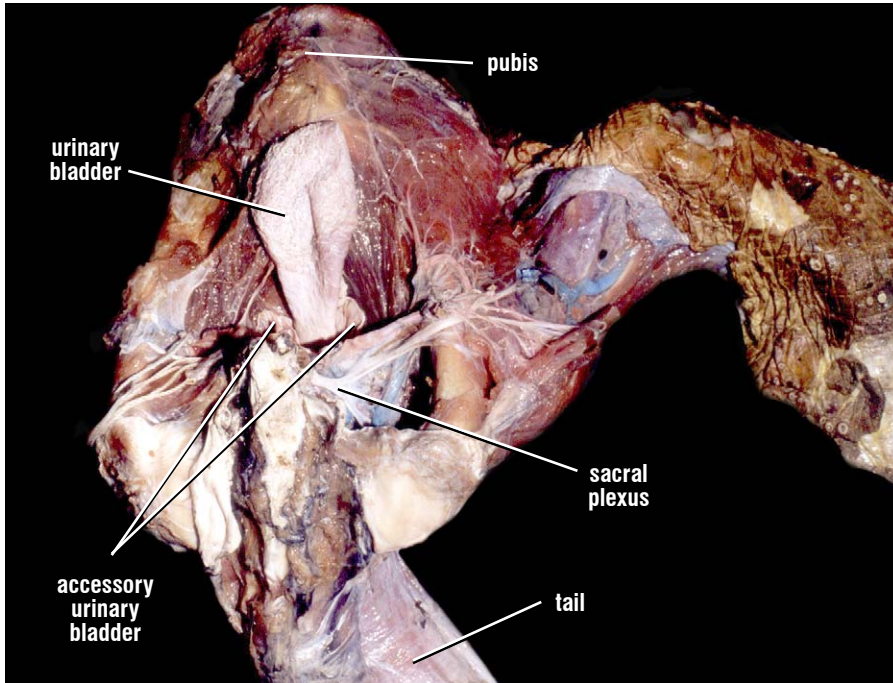
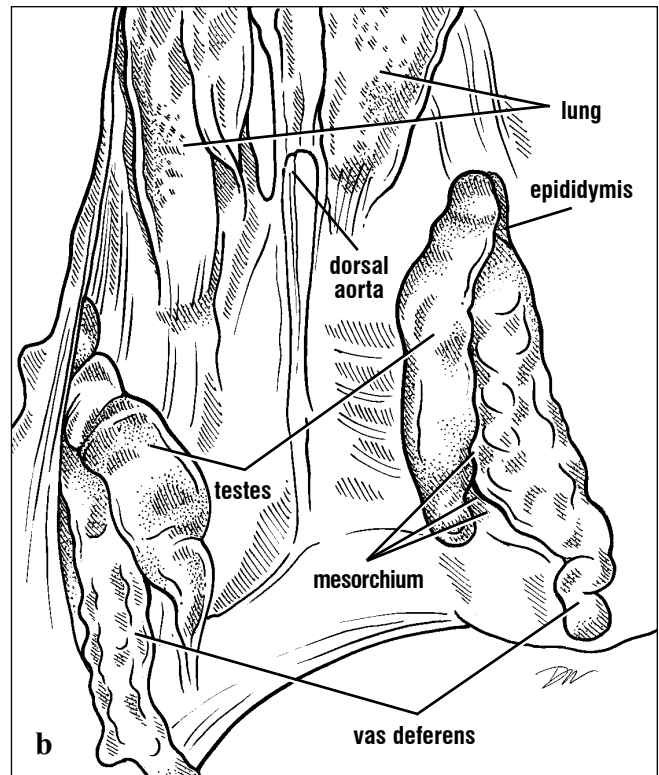
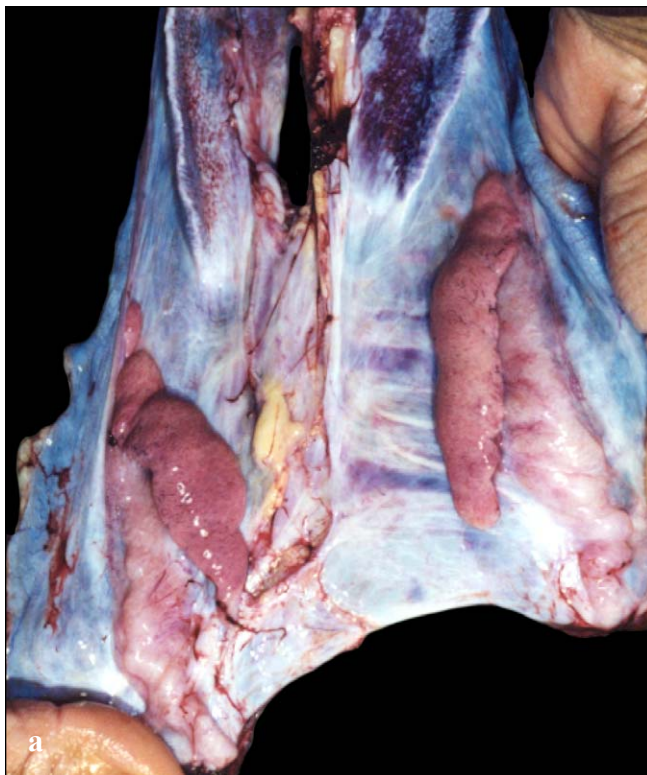
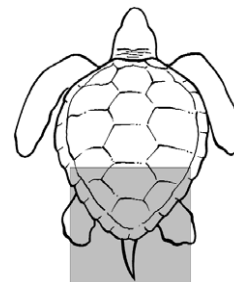
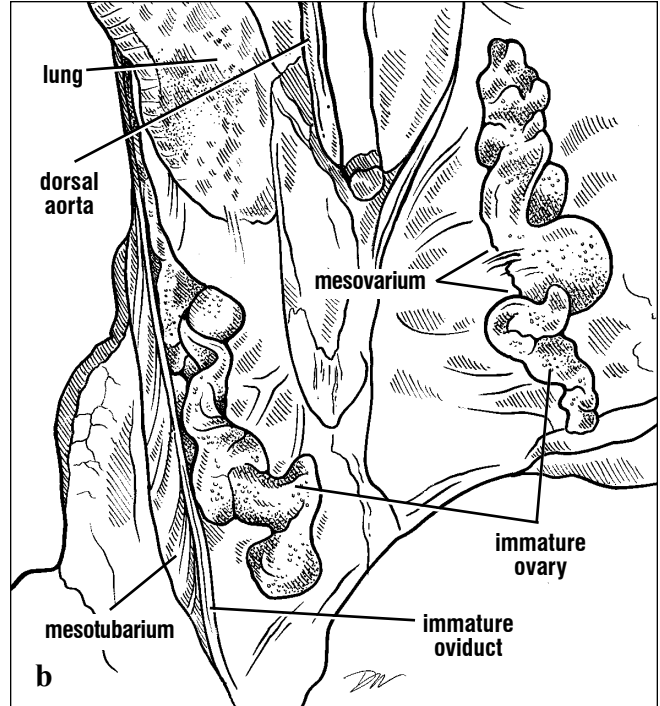
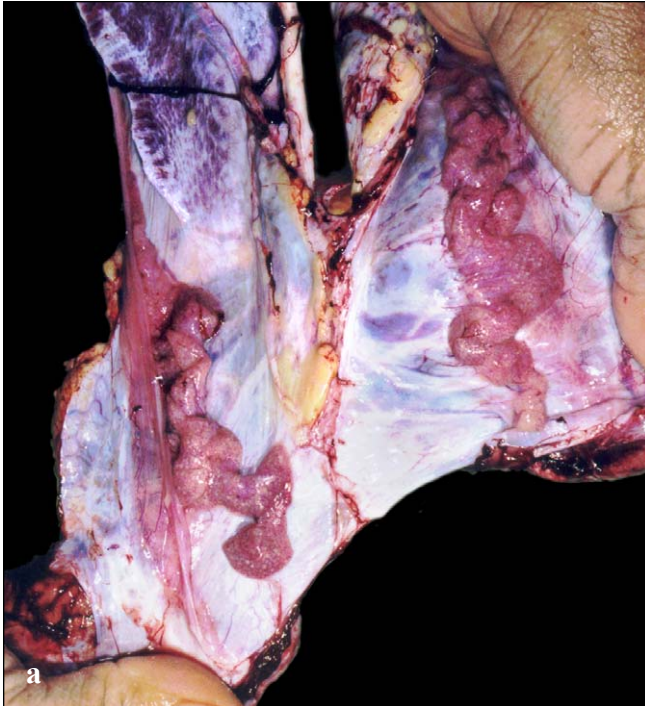

Fig. 221. Dorsal view of the urinary bladder and dorsal pelvis of a male loggerhead. The empty urinary bladder and accessory bladders are shown free of connective tissues. The ilia are found laterally; the sacral and proximal caudal vertebrae are present dorsally. The sacral plexus is exposed in part.



Figs. 222a and 222b. Testes of an immature green turtle. The testes are attached to the peritoneal wall by their flat dorsal surface. Lateral and slightly

dorsal to each testis is an epididymis, which leads to a vas deferens. The surface of the testis is smooth in immature turtles.



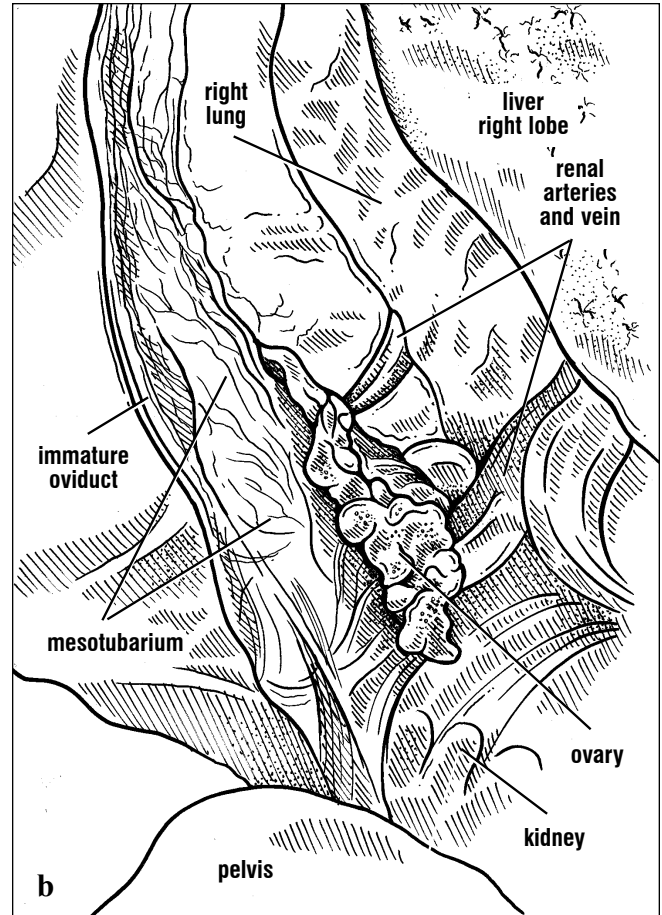
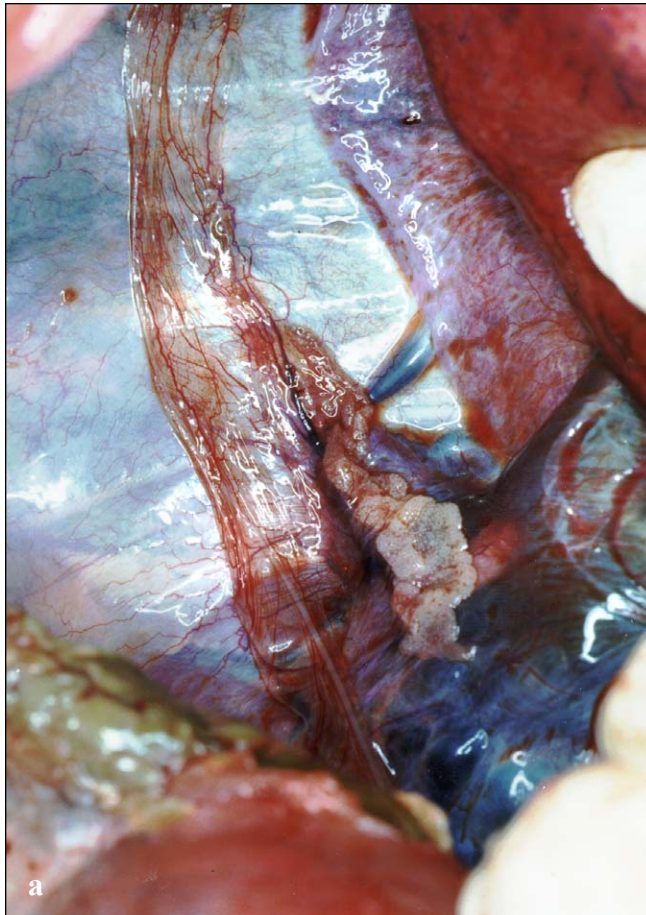Figs. 223a and 223b. Ovaries of an immature green turtle. The ovaries are attached to the peritoneal wall by their lateral edges. The surface

of the ovary is granular. Lateral to the ovary is the immature oviduct, which is suspended by the mesotubarium.

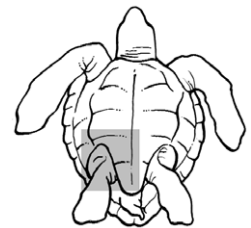
Female: The female reproductive tract consists of paired ovaries, oviducts (also called **Müllerian ducts**), and the suspensory ligaments or mesenteries (**mesovarium**, **mesosalpinx**, and **mesotubarium**). The ovary and oviduct change in size and composition with age and between breeding and nonbreeding seasons.

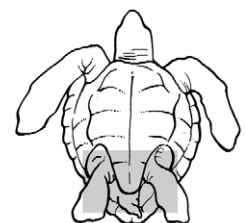
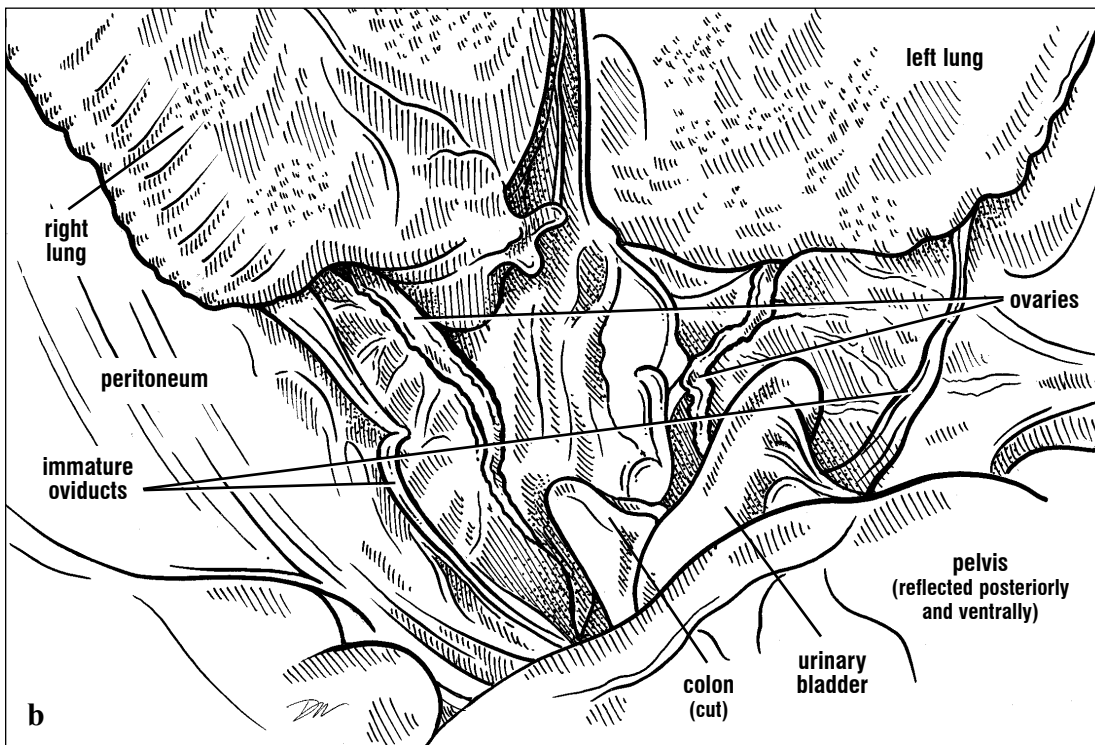
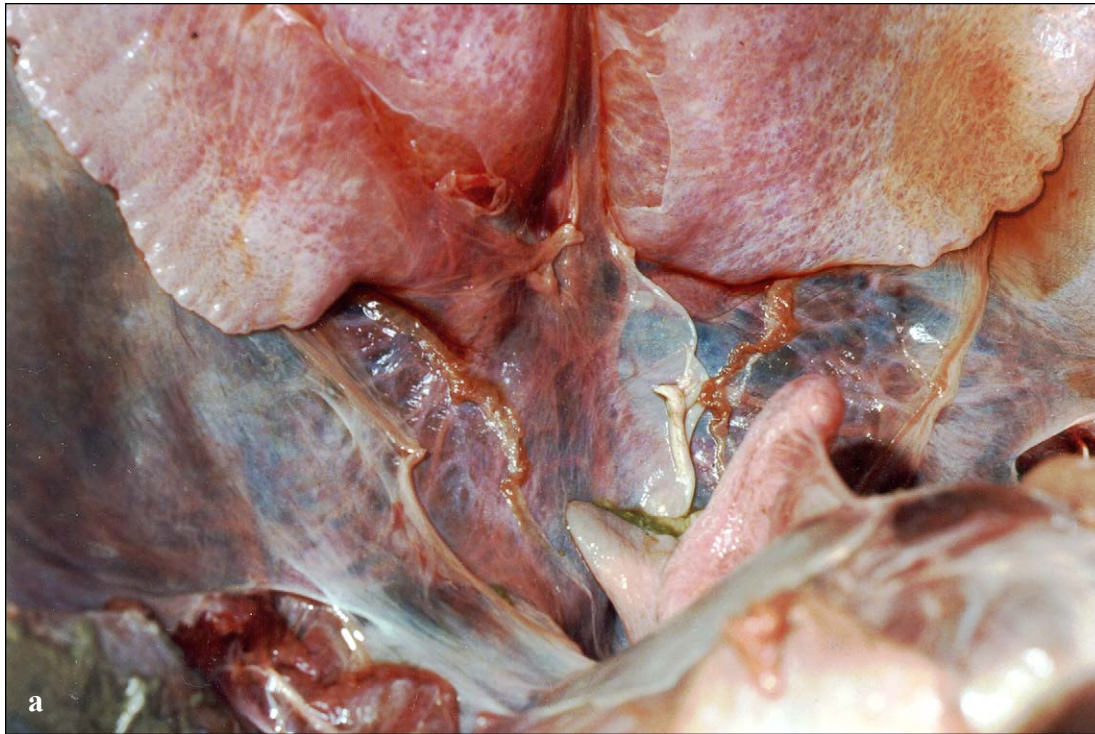The cranial pole of the ovary is located just posterior to the lung and extends posteromedially toward the cloaca. Along its medial and dorsal

surface, it is attached by the mesovarium to the peritoneum that overlies the kidney (Fig. 224) Another ligament, the mesotubarium, extends from the ovary to the oviduct. The oviduct lies lateral to the ovary and extends anteriorly, before curving medially and ending in a funnel shaped opening, the ostium. The ostium, which receives ovulated follicles, is supported by the mesosalpinx. There are no tubules connecting the ovary directly to the oviduct. The posterior end of each oviduct joins the urodeum of the cloaca (Fig. 225).



Figs. 224a and 224b. Ovary and accessory ducts of a juvenile green turtle, (ventral view). This immature ovary has a granular surface. Its follicles have not yet added significant amounts of yolk. The immature oviduct is a thin, flat tube supported in the mesentery (mesotubarium). Engorged renal arteries and veins can be seen extending from the kidney, anatomically dorsal to the ovary, and toward the midline.




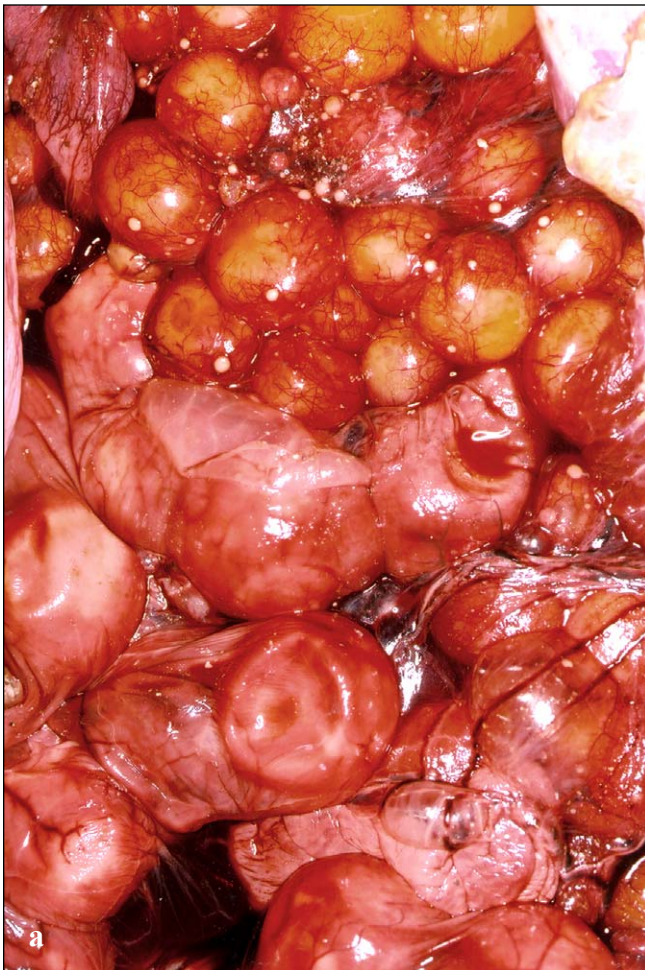


Figs. 225a and 225b. Immature ovary and oviduct (ventral view). The immature ovary is thin and located more medially than the oviduct. The immature oviduct extends anteriorly then turns posteriorly. The ostium is formed at the expanded end. The oviduct, mesotubarium, and mesosalpinx are reflected laterally.

UROGENITAL SYSTEM

In hatchlings, the ovaries are difficult to distinguish from testes. If histology is unavailable, the attachment of the mesovarium to the ovary edge and the lack of a coiled vas deferens suggest that the gonad is an ovary. In older turtles, the gonad will be pink and will have a grainy texture as small follicles become more distinct. As turtles approach maturity, some follicles increase in size and start to accumulate bright yellow yolk. In sexually mature turtles, mature follicles tend to cluster along the cranial aspect of the ovaries. Immature follicles are most concentrated in the

posterior third of the ovary. Mature turtles that have nested previously will have large follicles that are ~2-3cm in diameter and scars from previously ovulated follicles, **corpora albicans** (Fig. 226). Recently ovulated follicles leave active scars, each is called a **corpus luteum**. The corpus luteum becomes a corpus albicans after it ceases to produce the hormone progesterone. The ages of corpora albicans are difficult to judge, however larger ones are generally more recent than smaller ones. It is safest to use this information simply to determine if the turtle had nested previously or not.



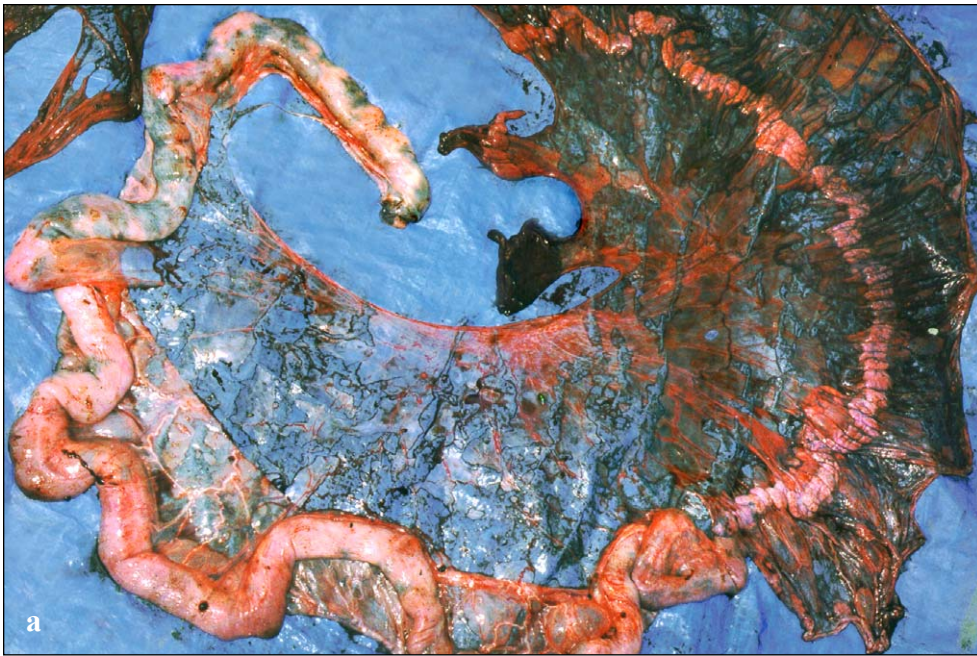
Figs. 226a and 226b. Eggs, follicles, and corpora albicans in a reproductively active loggerhead. This oviduct holds shelled eggs. Above the oviduct

are several sizes of maturing follicles and the scars (corpora albicans) remaining from the sites of ovulated follicles.

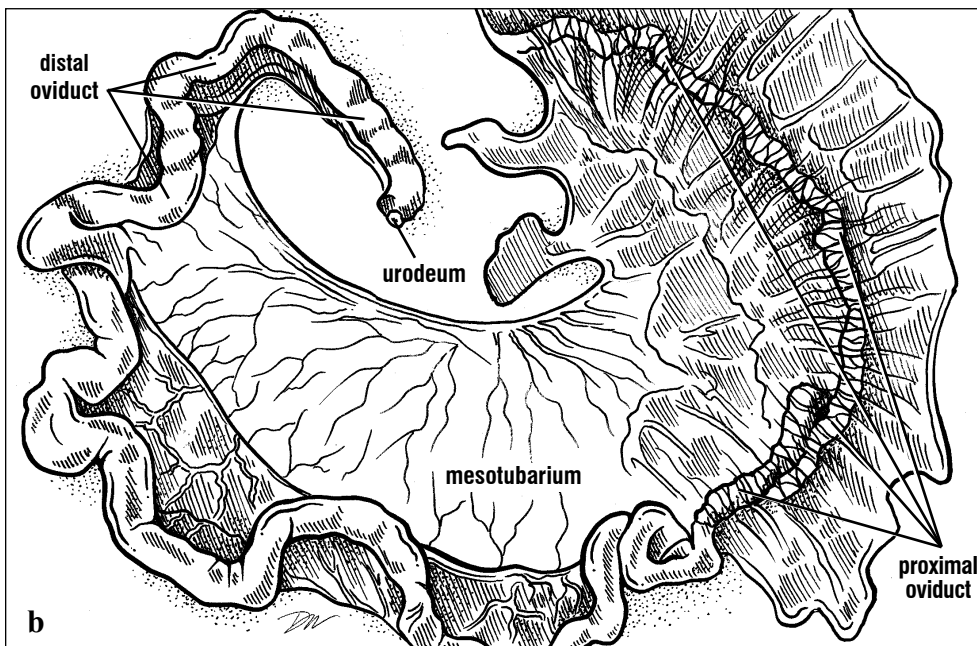
UROGENITAL SYSTEM

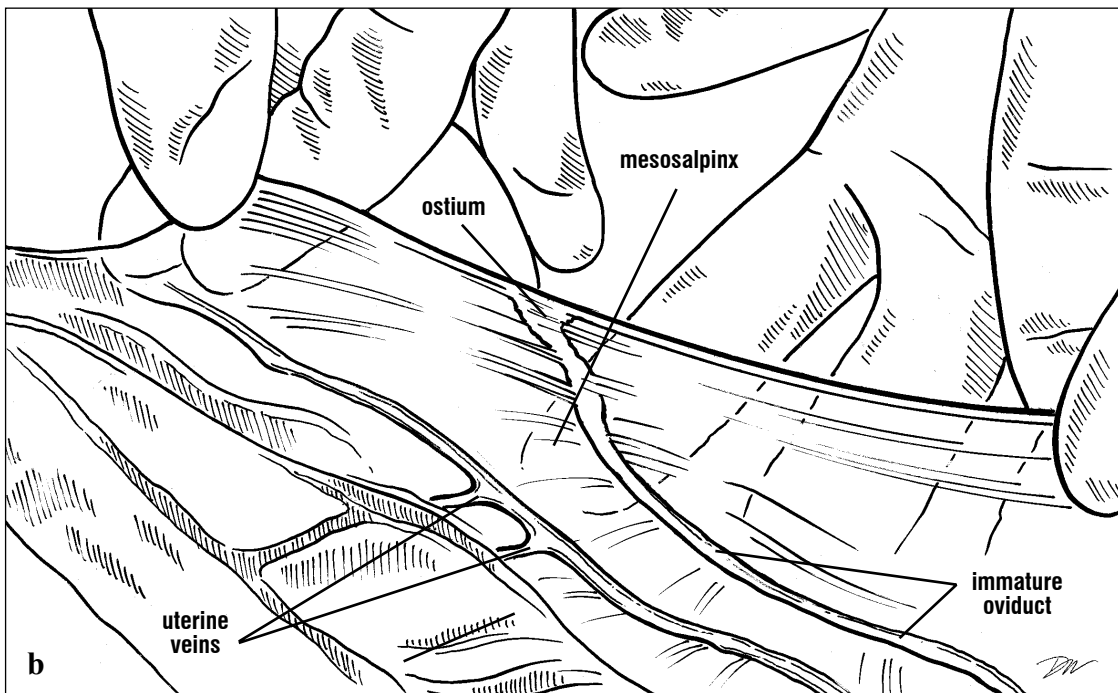
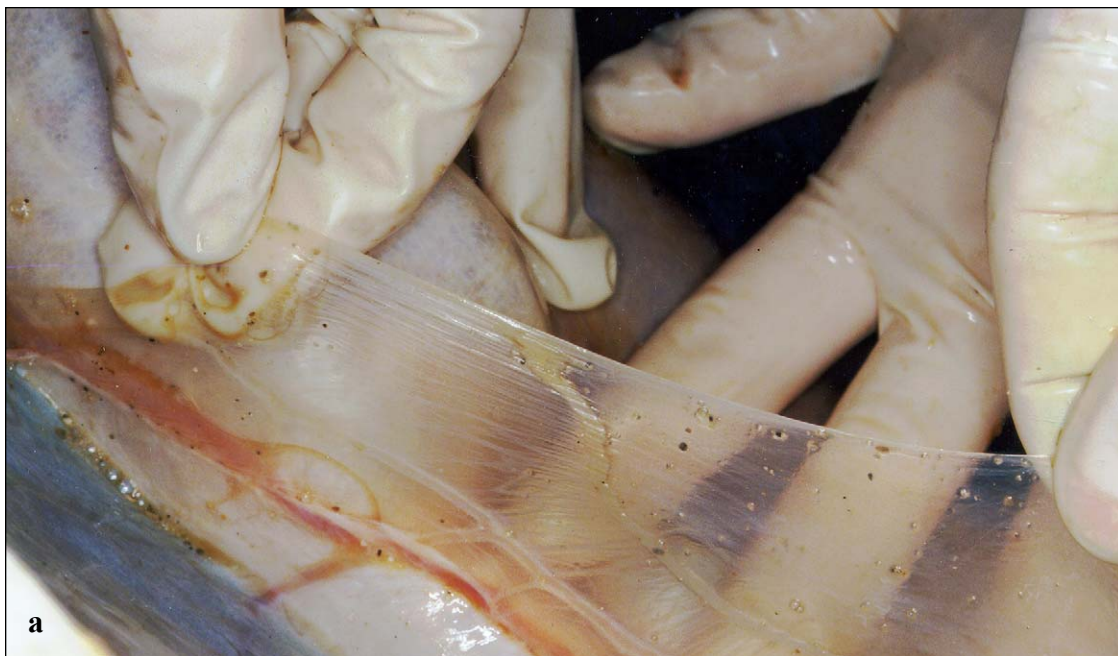The oviduct of immature turtles is a thin walled tube (Figs. 224-225). As females mature, the walls of the oviduct thicken and the lumen increases in diameter. It appears folded along its length when not active (Fig. 227). The oviduct can be described functionally (but not in gross structure) as having 5 regions: the ostium (or infundibulum), aglandular

segment, magnum, shell gland, and vagina. The ostium remains thin-walled but increases in size (Figs. 228-229). The oviduct of mature females is muscular and mobile. It is assumed that the ostium migrates across the ovary surface collecting the ovulated follicles.

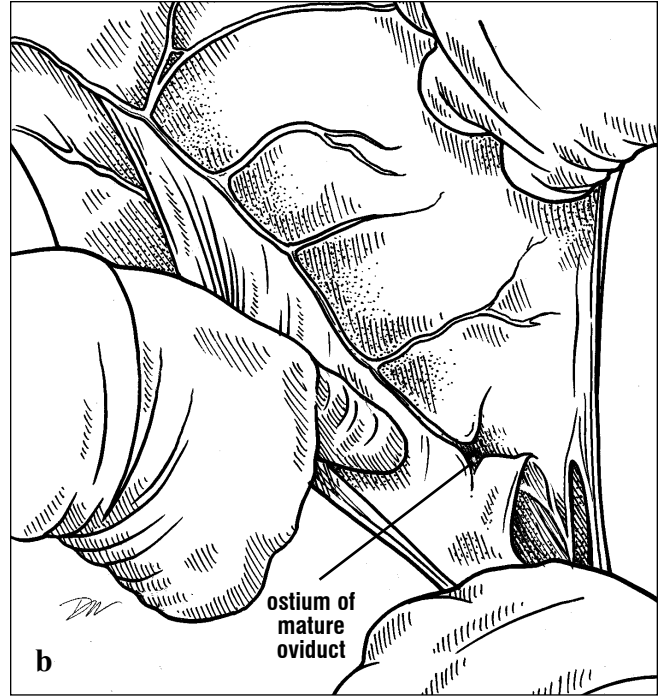
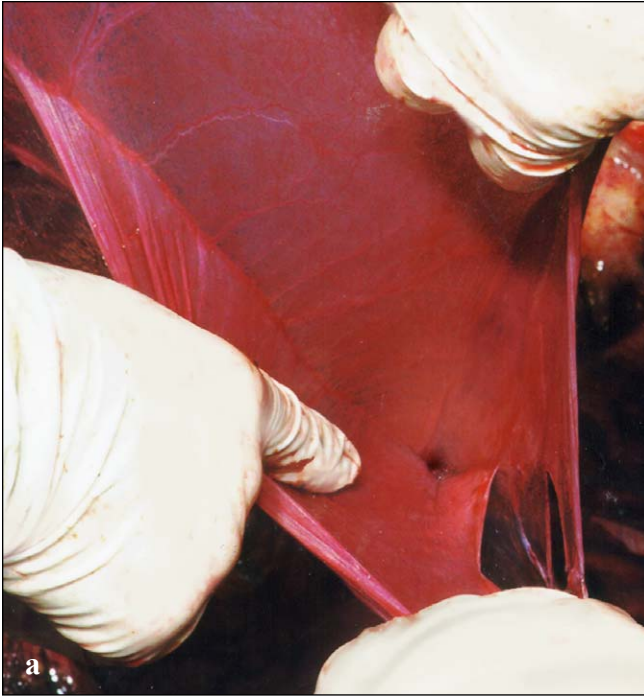


Figs. 227a and 227b. *Mature oviduct of a leatherback. The mature oviduct has a large lumen and the walls have undulatory folds. The mesosalpinx and mesotubarium enlarge to accommodate the mature structures. The distal ends would normally enter the cloaca. The proximal end is the site of the ostium.*





Figs. 228a and 228b. *The ostium of an immature oviduct. The ostium is flattened when not active; the funnel-shaped opening is small in young turtles.*



Figs. 229a and 229b. *The ostium of a mature oviduct. The ostium of this leatherback's oviduct is large, funnel-shaped and thin walled. The base*

of the ostium opens into the aglandular part of the proximal oviduct.

In preparation for nesting, an entire clutch of follicles matures and ovulates together. Once in the ostium, each follicle travels past the aglandular segment and into the magnum (anterior glandular region) where it is coated with layers of albumen. After about 3 days, the follicles pass to the shell gland where the protein and carbohydrate shell membrane (chorion) and the aragonite shell matrix are secreted. The shell calcification takes about 6 to 7 days. Eggs pass to the vagina where they remain until deposition, several days later. During deposition, the posterior oviduct allows eggs to pass to the cloaca, then out the vent into the nest. The cloaca forms a tubular orifice in nesting turtles. The structures that form this "egg tube" are unknown.

Males: The male reproductive tract consists of paired **testes**, **epididymi**, **deferent ducts** (vas deferens = ductus deferens), suspensory ligaments (**mesorchium** from the body wall to the testis), and a single **penis**. Müllerian ducts may persist as

a pair of small, flat, thin-walled tubes in some males. When present, they are located along the lateral body wall (suspended by a mesotubarium) from the duct to the testis or peritoneum overlying the kidney. They will often extend toward the anterior third of the body, lateral to the lung.

The testis is fusiform shaped (Fig. 222). The cranial pole is located just posterior to the lung; it extends posteromedially toward the cloaca. Along its dorsal surface, it is attached by the mesorchium to the peritoneum overlying the kidney. The testis is light tan or yellow in some species and gray to pink in others. Sperm are produced in the testis and are conveyed via very small efferent ductules to the epididymis, which lies lateral or posterolateral to the testis. The vas deferens leads from the epididymis to the cloaca at the base of the penis, demarked by the **corpra cavernosum** (Fig. 222). The testis, epididymis, and vas deferens change in size and form with age and between

UROGENITAL SYSTEM

breeding and nonbreeding seasons (Fig. 230). Testes in mature breeding males are often twice as long as their diameter and filled with white fluid (sperm and accessory gland fluid).

spermaticus; Fig. 231). During mating, the corpora cavernosa are supplied with blood via the hypogastric and internal iliac veins. When erect, the walls of the urethral groove meet dorsally to

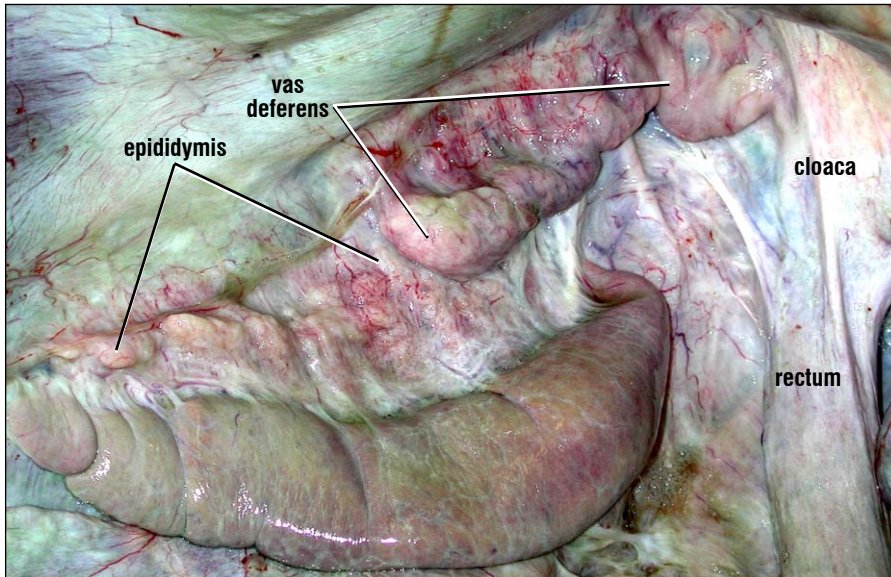
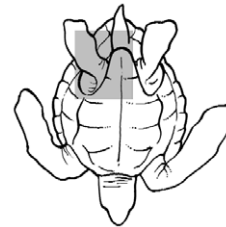


Fig. 230. *Mature loggerhead testis and accessory ducts (posteroventral view). The testes, epididymis, and vas deferens in a mature male during breeding season. The vas deferens lead to the base of the penis in the ventral floor of the cloaca.*



The genital papilla elongates into the penis during maturation. The penis is retracted except during mating, trauma, or death; it lies in the ventral floor of the cloaca. It is composed of a pair of **corpora cavernosa** and a "urethral groove" (= sulcus

form a functional tube through which sperm and fluids pass. Some species have ornamented structures (e.g., spines or flaps that have a triradiate form) on or near the glans penis at the distal tip (Fig. 232).

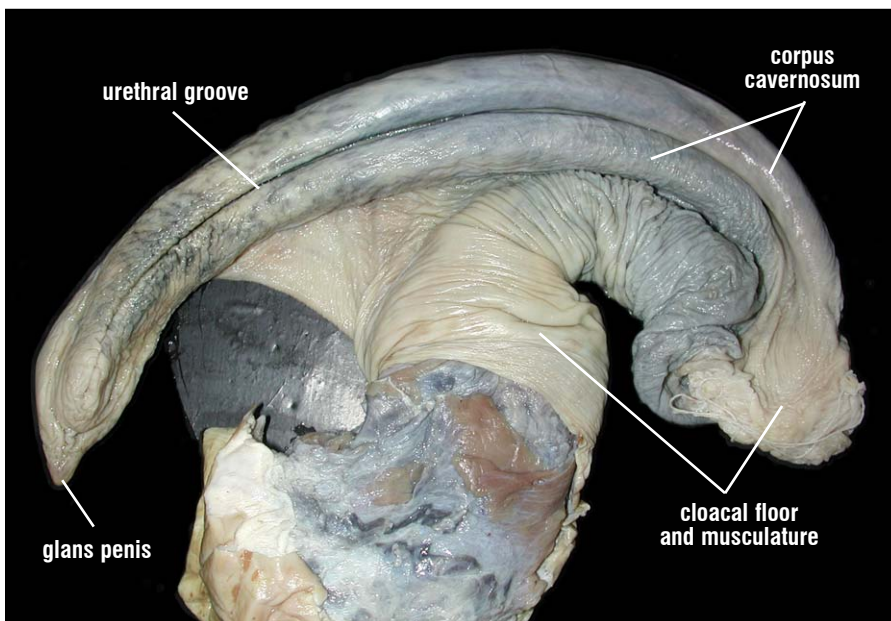


Fig. 231. *Adult loggerhead penis (dorsal view). The marine turtle penis is part of the ventral floor of the cloaca. The two corpora cavernosa function in penile erection and elongation. The urethral groove, between the two cavernous bodies conveys sperm during mating. The penis is completely housed within the cloaca when not erect.*

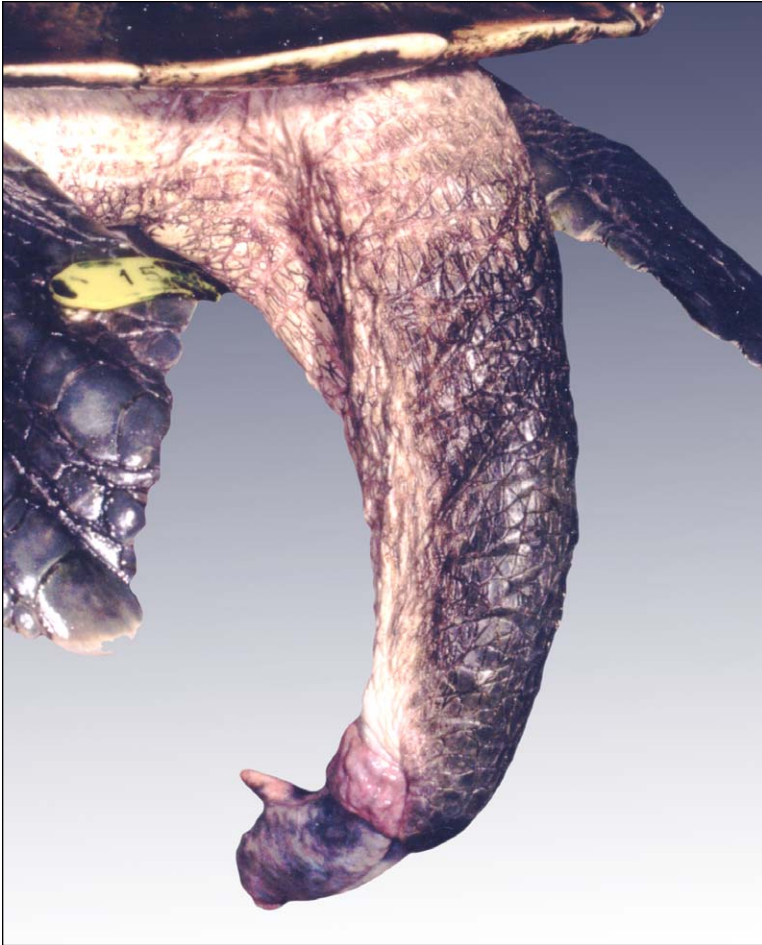

Fig. 232. Tail and penis of a Kemp's ridley. The long tail and distally positioned vent are distinctive of adult male turtles. This animal has a semi-erect penis with a subterminal horn on the ventral lobe of the glans penis. Not all species have ornaments on the penis. Generally, maturing males have a more distally positioned vent than a female of the same body size. However, not all males start maturation at the same size, so the combination of tail length and cloacal position should be used with caution when identifying the sex of the turtle.

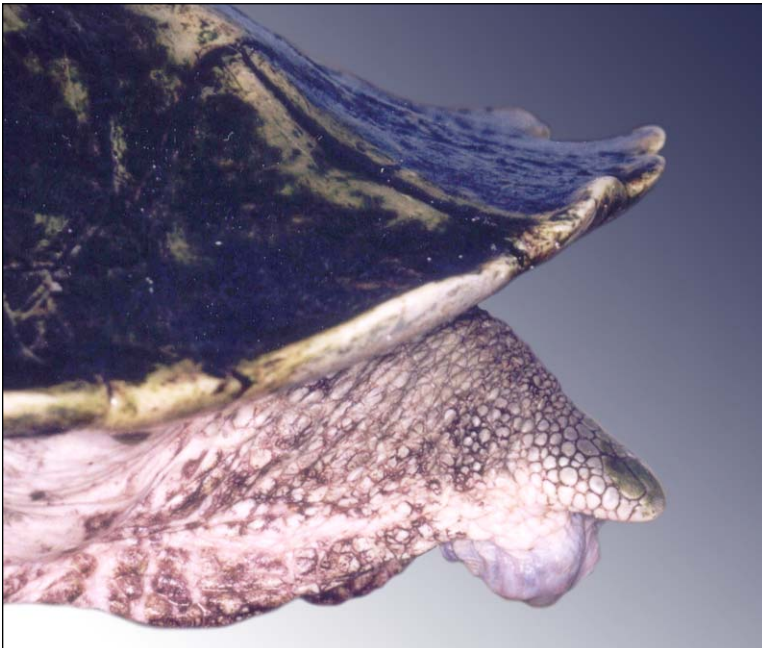
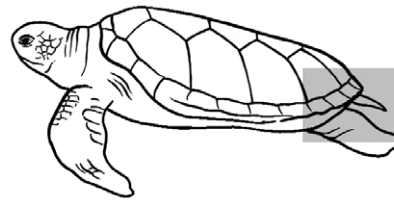


Fig. 233. Tail of an adult female Kemp's ridley. The short tail and cloaca located proximally are characteristic of females and immature males. This female protruded the cloacal opening as is seen in nesting turtles.

Sexual dimorphism. Adult females differ little in external morphology from large, immature males. Typically, females have a short tail and the cloacal opening (**vent**) is located roughly half way between the tip of the tail and the plastron's anal scute (Fig. 232). Within the cloaca, the genital papilla remains small as the clitoris on the floor of the cloaca. (Fig. 219).

In the Western North Atlantic, female loggerheads mature at an average SCL of 92 cm (range: 75-104 cm). Green turtle females mature and nest at an average SCL of 97 cm (range: 83-113 cm) and leatherback females are about 155 cm CCL (very

few nesting females have been measured on U.S. beaches). The minimum size of a nesting female leatherback in the USVI was 133 cm CCL.

Adult males are characterized by a long tail with the cloacal opening near the tip, and strongly curved claws on the second digit. During breeding season, a decornification of the plastron occurs along and to each side of the midline (Fig. 233). The plastron becomes increasingly vascular and edematous. Male leatherbacks, have slightly concave plastrons. There is no evidence of decornification or increased plastral vascularization during leatherback breeding season.

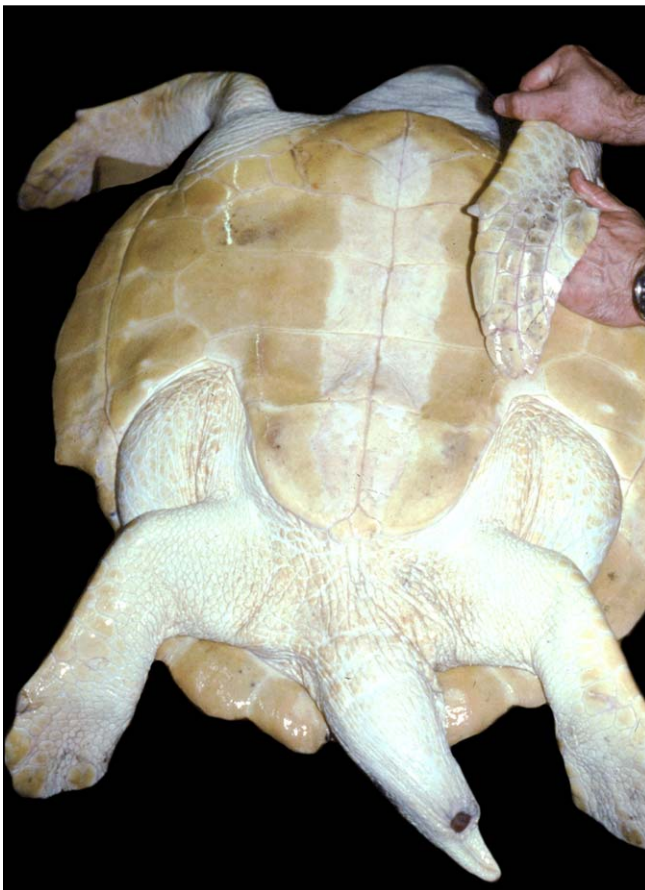

Fig. 234. Sexually mature male ridley. Male sexually dimorphic characteristics include an elongated tail, long curved claws, and, during breeding season, the midventral plastron becomes soft.

SELECTED BIBLIOGRAPHY

- Ashley, L. M. 1955. *Laboratory Anatomy of the Turtle*. Wm. C. Brown Company Publishers. Dubuque, Iowa. 48 pp.
- Barragan, A.R. 1996. Anatomical basis for an intracardiac bloodflow model in sea turtles. pp. 34-37. In: Proceedings of the 15th Annual Symposium on Sea Turtle Biology and Conservation. pp. J. Keinath, D. E. Barnard, J. A. Musick, and B. A. Bell, Compilers. NOAA Technical Memorandum NMFS-SEFSC-387. 355 pp.
- Baur, G. 1891. The pelvis of the testudinata, with notes on the evolution of the pelvis in general. 4(3, 6 February): 345-359. (Clark University).
- Beck, K., Loomis, M., Lewbart, G., Spelman, L., and Papich, M. 1995. Preliminary comparison of plasma concentrations of gentamicin injected into the cranial and caudal limb musculature of the eastern box turtle (*Terrapene carolina carolina*). Journal of Zoo and Wildlife Medicine 26(2):265-268.
- Bellairs, A. d' A. 1960. *Reptiles. Life History, Evolution and Structure*. Harper Torchbooks/ The Science Library. Harper & Brothers. New York. 192 pp.
- Bojanus, L. H. 1970. *Anatomie Testudinis Europaeae*. Facsimile Reprints in Herpetology. 26. C. Gans, I. S. Darevsky, and K. Adler, eds. SSAR.
- Bracegirdle, B. and P. H. Miles. 1978. *An Atlas of Chordate Structure*. Heinemann Educational Books Ltd. The University Press. Oxford. 119 pp.
- Bruner, H. L. 1907/1908. On the cephalic veins and sinuses of reptiles, with description of a mechanism for raising the venous blood-pressure in the head. American Journal of Anatomy. VII: 1-117.
- Burggren, W., W. Mogens, L. Glass, and K. Johansen. 1977. Pulmonary ventilation: perfusion relationships in terrestrial and aquatic chelonian reptiles. Canadian Journal of Zoology. 55(12): 2024-2034.
- Burne, B. A. 1905. Notes on the muscular and visceral anatomy of the leathery turtle (*Dermochelys coriacea*). Proceedings of the Zoological Society of London. 1905: 291-324.
- Callister, R. J., R. Callister, and E. H. Peterson. 1989. Histochemical classification of neck and limb muscle fibers in a turtle, *Pseudemys scripta*: a study using microphotometry and cluster analysis techniques. Journal of Morphology. 199: 269-286.
- Davenport, J. and C. R. Scott. 1993. Individual growth and allometry of young green turtles (*Chelonia mydas* L.). Herpetological Journal. 3:19-25.
- Deraniyagala, P.E.P. 1939. *The Tetrapod Reptiles of Ceylon*. Ceylon Journal of Science, (Colombo Museum Natural History Series). 1:1-412.
- Detwiler, Samuel R. 1943. *Vertebrate Photoreceptors*. The MacMillan Company, New York: 175 pp.
- Duncker, H. R. 1978. General morphology principles of amniote lungs. pp. 1-15. In: *Respiratory Function in Birds, Adult and Embryonic*. J. Piiper, ed. Springer-Verlag, New York.
- Eckert, K. L., K. A. Bjorndal, F. A. Abreu-Grobois, and M. Donnelly (Editors). 1999. *Research and management techniques for the conservation of sea turtles*. IUCN/SSC Marine Turtle Specialist Group Publication No. 4.
- Edgeworth, F. H. 1935. *The Cranial Muscles of Vertebrates*. The University Press. Cambridge. 493 pp.
- Ehrhart, L. M. and B. E. Witherington. 1986. Human and natural causes of marine turtle nest and hatchling mortality and their relationship to hatchling production on an important Florida nesting beach. Florida Game and Freshwater Fish Commission Tech Report No. 1:1-141.
- Evans, H. E. 1995. *Anatomy of Reptiles*. World Veterinary Congress. Japanese Association of Veterinary Anatomy. WVA/WSAVA, Yokohama, Japan.
- Evans, Howard E. 1986. Reptiles. Introduction and anatomy. Chapter 13. In: *Zoo and Wild Animal Medicine*. pp.108-132. 2nd edition. M. E. Fowler, ed. W. B. Saunders Company. Philadelphia. 617 pp.
- Ewert, M. A. 1985. Embryology of Turtles. pp. 75-267. In: *Biology of the Reptilia*. Vol. 14 (Development A), C. Gans, F. Billett, and P.F. A. Maderson, eds. Academic Press. New York. 763 pp.
- Farrell, A. P., A. K. Gamperl, and E. T. B. Fransis. 1998. Comparative aspects of heart morphology. pp. 375-424. In: *Biology of the Reptilia*, Vol. 19 (Morphology G). C. Gans and A. S. Gaunt, eds. SSAR Contributions to Herpetology, Vol. 14. Ithaca. 660 pp.
- Fleetwood, J. N. and J. F. Munnell. 1996. Morphology of the airways and lung parenchyma in hatchlings of the loggerhead sea turtle, *Caretta caretta*. Journal of Morphology. 227:289-304.
- Fox, H. 1977. The urogenital system of reptiles. Chapter 1. pp 1-157. In: *Biology of the Reptilia*, Vol. 6. (Morphology E). C. Gans and T. Parsons, eds. Academic Press. New York. 505 pp.
- Gaffney, E. S. 1972. An illustrated glossary of turtle skull nomenclature. American Museum Novitates. 2486, (9 May): 1-33.
- Gans, C. and G. M. Hughes. 1967. The mechanism of lung ventilation in the tortoise *Testudo graeca* Linné. Journal of Experimental Biology. 47(1):1-20.
- Gaunt, A. S. and C. Gans. 1969. Mechanics of respiration in the snapping turtle, *Chelydra serpentina* (Linné). Journal of Morphology. 128:195-228.

SELECTED BIBLIOGRAPHY

- Gegenbaur, C. 1878. *Elements of Comparative Anatomy*. 2nd ed. (Translated by F. J. Bell and E. R. Lankester). MacMillan and Company. London. 624 pp.
- Grasse, P. P. 1948. Reptiles. Vol. 14. *Traité de Zoologie; anatomie systématique, biologie*. Masson Publ., Paris. 836 pp.
- Hicks, J.W. 1998. Cardiac shunting in reptiles: mechanisms, regulation, and physiological functions. pp. 425-483. In, *Biology of the Reptilia*. Vol. 19 (Morphology G). C. Gans and A. S. Gaunt, eds. SSAR Contributions to Herpetology, Vol. 14. Ithaca. 660 pp.
- Hoffman, C. K. 1890. Reptilien. I. Schildkröten. In: Klassen und Ordnungen des Thier-Reichs. H. G. Bronn, ed. 6. (3):1-442.
- Holtz, P., K. Barker, G. J. Crawshaw, and H. Dobson, 1997. The anatomy and perfusion of the renal portal system in the red-eared slider (*Trachemys scripta elegans*). *Journal of Zoo and Wildlife Medicine*. 28(4):378-385.
- Holtz, P., I. K. Barker, J. P. Burger, G. J. Crawshaw, and P. D. Conlon. 1997. The anatomy and perfusion of the renal portal system in the red-eared slider (*Trachemys scripta elegans*). *Journal of Zoo and Wildlife Medicine*. 28(4):386-393.
- Hyman, L. H. 1979. *Hyman's Comparative Vertebrate Anatomy*. M. H. Wake, ed. University of Chicago Press. Chicago. 788 pp.
- Jones, C. L. 1979. The morphology of the thigh of the mouse with special reference to tetrapod muscle homologies. *Journal of Morphology*. 162:275-310.
- Kardong, K. V. 2001. *Vertebrates: Comparative Anatomy, Function, and Evolution*, 3rd Edition. McGraw-Hill. New York. 762 pp.
- Kuratani, S. 1989. Development of the orbital region in the chondrocranium of *Caretta caretta*. Reconsideration of the vertebrate neurocranium configuration. *Anatomischer Anzeiger (Jena)*. Bd. 169(5): 335-349.
- Lenhardt, M., R.C. Klinger, and J.A. Musick. 1985. Marine turtle middle-ear anatomy. *Journal of Auditory Research*. 25:66-72.
- Lloyd, M. and P. Morris. 1999. Chelonian venipuncture techniques. *Bulletin of the Association of Reptilian and Amphibian Veterinarians*. 9(1):26-29.
- Lönnberg, E. 1902. On some points of relation between the morphological structure of the intestine and the diet of reptiles. *Proceedings of the Zoological Society. Bihang Till K. Svenska Vet.-Akad. Handlingar*. Vol. 28, Part 4 (8):3-51.
- Lutcavage, M. E., P. G. Bushnell, and D. R. Jones. 1990. Oxygen transport in the leatherback sea turtle, *Dermochelys coriacea*. *Physiological Zoology*. 63(5): 1012-1024.
- Lutcavage, M. E., P. G. Bushnell and D. R. Jones. 1992. Oxygen stores and aerobic metabolism in the leatherback sea turtle. *Canadian Journal of Zoology*. 70(2): 48-351.
- Lutcavage, M. E. and P. L. Lutz. Diving Physiology. Chap. 10. pp. 227-296. In: *Biology of Sea Turtles*. P. L. Lutz and J. A. Musick, eds. CRC Press, Boca Raton. 432 pp.
- Lutz, P. L., A. Bergy and M. Bergy. 1989. Effects of temperature on gas exchange and acid-base balance in the sea turtle *Caretta caretta* at rest and during routine activity. *Journal of Experimental Biology*. 144: 155-169.
- Maloney, J. E., C. Darian-Smith, B. Russell, M. Varghese, J. Cooper, and C. J. Limpus. 1989. An evolutionary link for developing mammalian lungs. *Journal of Developmental Physiology*. 12: 153-155.
- Marshall, A. T. 1989. The duct system of the lacrimal salt gland of the green sea turtle, *Chelonia mydas*. *Cell and Tissue Research (1989)* 257: 399-404.
- Miller, Jeffrey. D. 1985. Embryology of Marine Turtles. pp. 269-328. In: *Biology of the Reptilia*. Vol. 14 (Development A), C. Gans, F. Billett, and P.F. A. Maderson, eds. Academic Press. New York. 763 pp.
- Nilsson, S. 1983. *Autonomic Nerve Function in the Vertebrates*. Springer-Verlag. New York. 253 pp.
- Noble, G. A. and E. R. Noble. 1940. *A Brief Anatomy of the Turtle*. Stanford University Press, Stanford. 48 pp.
- Ottaviani, G. and A. Tazzi. 1977. The lymphatic system. Chap.4. pp: 315-462. In: *Biology of the Reptilia*. Vol. 6. (Morphology E), C. Gans and T. Parsons, eds. Academic Press. New York. 505 pp.
- Owens, D. W. Hormones in the life history of sea turtles. Chap. 12. p. 315-341. In: *Biology of Sea Turtles*. P. L. Lutz and J. A. Musick, eds. CRC Press. Boca Raton. 432 pp.
- Owens, D. W. and G. J. Ruiz. 1980. New methods of obtaining blood and cerebrospinal fluid from marine turtles. *Herpetologica*. 36(1): 17-20.
- Parsons, T. S. 1958. The Jacobsen's organ of turtles. *The Anatomical Record* 132(3 November): 486.
- Parsons, T. S. 1970. The nose and Jacobsen's organ. In: *Biology of the Reptilia*. Vol. 2 (Morphology B). C. Gans and T. Parsons, eds. Academic Press, New York. pp. 99-191.
- Parsons, T. S. and J. E. Cameron. 1977. Internal relief of the digestive tract. Chap. 2. pp. 159-179. In: *Biology of the Reptilia*. Vol. 6. (Morphology E). C. Gans and T. Parsons, eds. Academic Press. New York. 505 pp.
- Perry, S. F. 1998. Lungs: comparative anatomy, functional morphology, and evolution. pp. 1-97. In: *Biology of the Reptilia*, Vol. 19 (Morphology G). C. Gans and A. S. Gaunt, eds. SSAR Contributions to Herpetology, Vol. 14. Ithaca, NY, USA, 660 pp.
- Perry, S. F., C. Darian-Smith, J. Alston, C. J. Limpus and J. E. Maloney. 1989. Histological structure of the lungs of the loggerhead turtle, *Caretta caretta*, before and after hatching. *Copeia*. 1989 (4): 1000-1010.

SELECTED BIBLIOGRAPHY

- Pritchard, P. C. H. 1979. *Encyclopedia of Turtles*. T.F.H. Publications, Inc. Ltd. Neptune, NJ. 895 pp.
- Pritchard, P. C. H. 1988. A survey of neural bone variation among recent chelonian species, with functional interpretations. *Acta Zoologica Cracoviensia*. 31(26), 625-686.
- Rabl, C. 1910. Bausteine zu einer Theorie der Extremitäten der Wirbeltiere. I. Teil. II. Bau Entwicklung des Carpus und Tarsus der Schildkröten. Leipzig. Verlag Von Wilhelm Englelmann. 76-289.
- Rainey, W. E. 1981. *Guide to Sea Turtle Visceral Anatomy*. NOAA Technical Memorandum NMFS-SEFC-82. Panama City. 85 pp.
- Raynaud, A. 1983. Animal morphogenesis. A scanning electron microscopic study of the epithelial structures appended to the visceral arches of the embryo of the leathery turtle (*Dermochelys coriacea* V.). *Compté Rendu Academie des Sciences Paris (Series III)*. 296(6): 297-302.
- Romer, A. S. and T. Parsons. 1986. *The Vertebrate Body*. 6th edition. University of Chicago Press. Chicago. 679 pp.
- Rowe, T. 1986. Homology and Evolution of the deep dorsal thigh musculature in birds and other reptilia. *Journal of Morphology*. 189:327-346.
- Ryke, W. de. 1926. The vascular structure of the kidney in *Chrysemys marginata belli* (Gray) and *Chelydra serpentina* (L.). *The Anatomical Record*. 33 (3): 163-177.
- Saito, K., T. Shoji, I. Uchida, and H. Ueda. 2000. Structure of the olfactory and vomeronasal epithelia in the loggerhead turtle *Caretta caretta*. *Fisheries Science*. 66(2): 409-411.
- Sapsford, C. W. 1978. Anatomical evidence for intracardiac blood shunting in marine turtles. *Zoologica Africana*. 13(1):57-62.
- Schaffner, F. 1998. The liver. pp. 485-532. In: *Biology of the Reptilia*, Vol. 19 (Morphology G). C. Gans and A. S. Gaunt, eds. SSAR Contributions to Herpetology, Vol. 14. Ithaca. 660 pp.
- Schumacher, G. H. 1973. The head muscles and hyolaryngeal skeleton of turtles and crocodylians. pp. 101-199. In: *Biology of the Reptilia*. 4 Vol. (Morphology D). C. Gans and T. Parsons, eds. Academic Press. New York.
- Schumacher, G.-H. 1985. Comparative functional anatomy of jaw muscles in reptiles and mammals. *Fortschritte der Zoologie*, Band 30. pp 203-212. In: *Vertebrate Morphology*. H. R. Duncker and Fleischer, eds. Gustav Fischer Verlag. New York.
- Shelton, G. and W. Burggren. 1976. Cardiovascular dynamics of *Chelonia* during apnoea and lung ventilation. *Journal of Experimental Biology*. 64:323-343.
- Solomon, S. E. 1985. The morphology of the kidney of the green turtle (*Chelonia mydas* L.). *Journal of Anatomy*. 140(3):355-369.
- Tanaka, Y. 1998. Structure of the reptilian spleen. pp. 533-586. In: *Biology of the Reptilia*, Vol. 19 (Morphology G). C. Gans and A. S. Gaunt eds. SSAR Contributions to Herpetology, Vol. 14. Ithaca. 660 pp.
- Tanner, W. W. and D. F. Avery. 1982. Buccal floor of reptiles, a summary. *The Great Basin Naturalist*. 43(3): 273-349.
- Thompson, J. S. 1932. The anatomy of the tortoise. *The Scientific Proceedings of the Royal Dublin Society*. 20 (28):359-461.
- Thompson, S. M. 1980. A comparative study of the anatomy and histology of the oral cavity and alimentary canal of two sea turtles: the herbivorous green turtle *Chelonia mydas* and the carnivorous loggerhead turtle *Caretta caretta*. M.S. Thesis. James Cook University. 313 pp.
- Underwood, G. 1970. The Eye. In: *Biology of the Reptilia*. C. Gans and T. Parsons, eds. Vol. 2 (Morphology B), Academic Press, New York. Pp. 1-97.
- Walker, Jr., W. F. 1973. The locomotor apparatus of Testudines. Chap. 1. pp. 1-100. In: *The Biology of the Reptilia*. Vol. 3. (Morphology). C. Gans and T. S. Parsons, eds. Academic Press. New York.
- Walls, G. L. The reptilian retina. I. A new concept in visual-cell evolution. In: *The Vertebrate Eye*. pp. 892-915.
- Wang, T., A.W. Smits, and W. W. Burggren. 1998. Pulmonary function in reptiles. pp. 297-374. In: *Biology of the Reptilia*. Vol. 19 (Morphology G). C. Gans and A. S. Gaunt, eds. SSAR Contributions to Herpetology, Vol. 14. Ithaca. 660 pp.
- Wibbels, T., D. W. Owens, and D. Rostal. 1991. Soft plastra of adult male sea turtles: an apparent secondary sexual characteristic. *Herpetological Review*. 22(2): 47-49.
- Winokur, R.M., 1982. Erectile tissue and smooth muscle in snouts of *Carettochelys insculpta*, Trionchids and other *Chelonia*. *Zoomorphology* 101:83-93.
- White, F. N. 1978. Circulation, a comparison of reptiles, mammals, and birds. pp.51-59. In: *Respiratory Function in Birds, Adult and Embryonic*. J. Piiper, ed. Springer-Verlag, New York.
- Wolke, R. E. and A. George. 1981. *Sea Turtle Necropsy Manual*. NOAA Technical Memorandum NMFS-SEFC-24.
- Wright, A. H. and A. A. Wright. 1958. *Herpetological Terminology*. Tulane University. 34 pp.
- Wyneken, J. 1996. Sea turtle locomotion: mechanisms, behavior, and energetics. Chap. 7., pp. 165-198. In: *Biology of Sea Turtles*. P. L. Lutz and J. A. Musick, eds. CRC Press, Boca Raton. 432 pp.
- Zug, G. R. 1966. The penial morphology and the relationships of Cryptodiran turtles. *Occasional Papers of the Museum of Zoology*. University of Michigan. 647: 1-24.

A

abdominal scutes, 1-2, 4, 31
 abdominal vein, 72, 74-75, 79, 100, 101
 abductors, 59-61
 abducens nerve, 127-128, 150, see cranial nerves
 accessory urinary bladder, 153-156
 acoustic nerve, 151, 152
 acetabulum, 54-56, 152-155
 acromion processes, 35-37, 51-52, 59, 61-63, 74-75, 111, 116
 adductor femoris, 71, 73, 145
 adductors, 56, 60, 65, 68, 70-73, 143
 adenohypophysis, see pituitary
 adrenal arteries, 78, 83-84
 adrenal gland, 42, 84, 106, 124
 afferent renal vessels, 154
 aglandular segment, 160, 162
 airway, 105-107, 109
 albumen, 162
 albumin, 119
 alveolar surface, 26-27
 ampulla of Vater, 111, 113
 anal scutes 1-2, 4, 31
 anatomical position, 1
 anatomical terminology, 1
 angular, 9, 11
 anterior pancreatic veins, 103
 anterior pancreaticoduodenal artery, 78, 80
 anterior subscapular arteries, 77, 141
 aortas, 37-38, 74, 76, 83, 117, 124, 156,
 arteries, 37-38, 41-42, 59, 62-63, 74, 76-86,
 95, 101, 103, 105, 116-118, 124, 154, 156
 astragalus, 56-58
 atlas, 9, 44-45, 136, 139
 atria, see atrium
 atrium, 38, 74, 121
 auditory canal, 9, 11, 151
 auditory nerve, 152
 axial muscles, 68
 axial skeleton, 43
 axillary artery, 38, 77
 axillary nerve, 145
 axillary scale, 122
 axillary vein, 79, 85
 axis, 9, 45, 139
 azygos artery, 86
 azygos vein, 79, 85-86

B

basisphenoid, 9, 12, 125
 BD, see body depth
 beak, see rhamphotheca
 biceps brachii, 59, 61-63, 65, 67, 86, 145
 biventer cervical, 68, 87, 89-93
 bladder, 40-41, 153-155
 body depth, 31
 brachial artery, 77, 99
 brachial plexus, 59, 64, 141-143, 145
 brachial vein, 79, 85

brachiocephalic artery, see brachiocephalic trunk
 brachiocephalic trunk, 38, 74, 76-78, 116,
 brain, 8, 42, 105, 115-116, 125-141, 146, 152
 braincase, 8-9, 12, 41, 115-116, 125, 130,
 139-140
 bronchi, see bronchus
 bronchus, 40-41, 85, 105-107

C

calcaneum, 56-58
 carapace scutes, 1-2, 4-8, 26-27, 102
 carapace length, 28-29
 carapace width, 28, 30
 carapace, 1-2, 4-7, 26-30
Caretta caretta, 4, 6-7, 16-17, 25, 27, 41-
 46, 50-51, 55, 71, 80, 86, 92, 94, 97, 101,
 106, 108, 112, 120, 125, 129-132, 147,
 150-151, 155
 carotid artery, 69, 70, 76-78, 80, 117-118, 136
 caudal artery, 83-86, see vertebral artery
 caudal veins, 79, 102
 caudal vertebrae, 45-46, 155
 cavernous bodies, 161
 cavum arteriosum, 74, 104
 cavum pulmonae, 74, 104
 cavum venosum, 74, 104
 CCL, see carapace length
 CCLmax, see curved carapace length
 CCLmin, see curved carapace length
 CCW, see curved carapace width
 central nervous system, 125-141
 centrale, 52-54
 cerebellum, 42, 126-129, 131-141
 cerebral aqueduct, 126-128, 132, 134
 cerebral hemispheres, see cerebrum
 cerebrum, 42, 127, 129, 131-141
 cervical vertebrae, 9, 44-45, 66, 80, 94,
 141-142
Chelonia mydas, 4-5, 13-15, 25-26, 46, 94,
 98, 104, 110, 112, 119-121, 122-123,
 126, 130, 133-134, 146, 156-157
 Cheloniidae, 2
 Cheloniids, 2-5, 11, 26-27, 35, 42, 46, 49,
 51-53, 55, 62, 64, 71, 88, 104, 106, 110,
 116, 129, 136-137, 141, 143-144, 147
 choroid, 151
 ciliary body, 151
 circulation, 41, 74-104
 circulatory system, 41, 74-104
 CIRCUM, see circumference
 circumference, 32
 claws, 1-2, 5-7, 52, 165
 clitoris, 154, 164-165
 cloaca, 32, 39-42, 75, 83, 102, 108, 114,
 153-154, 157, 160, 162-165
 cloacal veins, 79, 102
 CNS, see central nervous system
 cochlea, 146, 152
 coeliac artery, 78, 80, 82

collecting tubules, 154
 colon, 39-41, 108, 111-112, 114, 121, 158
 columella, see stapes
 common bile duct, 39, 108, 111-113, 119-121
 common cardinal vein, see precava
 common carotids, 77-78
 common iliac arteries, see iliac arteries
 common mesenteric vein, 79, 100, 103
 cones, 151
 conjunctiva, 147, 149
 coracoid processes, 35-37, 51-52, 59, 61-
 64, 66-68, 74-75, 100, 111, 114
 cornea, 147, 151
 corpus albicans, see corpora albicans
 corpus luteum, see corpora luteum
 corpora albicans, 159
 corpora luteum, 159
 corpus albicans, see corpora albicans
 corpus luteum, see corpora luteum
 corpus cavernosum, 162-163
 cortex, 154
 costal arteries, 78-79, 83, 124
 costal scutes, see lateral scutes
 costal veins, 78-79, 83, 10, 102
 cranial nerves, 42, 68, 98, 127-129, 131-
 140, 150-151
 crural nerve, 143-145
 crural veins, 79, 100-101
 CT images, 43, 50
 curved carapace length, 28-29
 curved carapace width, 30
 curved plastron length, 31

D

deferent ducts, see vas deferens
 dentary, 9, 11, 23, 44, 68, 131-132, 135
 dermal ossicles, 49
 dermochelyid, 4-5
 Dermochelyidae 4-5
Dermochelys coriacea, 4-5, 23-25, 42,
 107-108, 111-112, 115, 127, 129-130,
 139-141, 148-149, 160, 162, 165
 descending vena cava, see precava
 diencephalon, 126-127
 digital arteries, 77-78
 digital veins, 85
 distal convoluted tubule, 154
 dorsal aorta, 41, 78, 80, 83-86, 124, 156
 dorsal brachial vein, 78
 dorsal muscles, 65-67, 87-93, 102
 duodenal veins, 79, 100, 103
 duodenum, 39, 80, 82, 108, 111-113, 119-121
 dura mater, 42, 125, see meninges

E

ear, 109, 126, 129-130, 146, 151-152
 efferent ductules, 162
 efferent renal vessels, 79, 154
 entoplastron, 50-52
 epididymi, see epididymis

INDEX

epididymis, 156, 162-163
epigastric arteries, 78, 83-85, 102
epigastric vein, 79, 102
epimeningeal veins, 125
epiphysis, see pineal
epiplastron, 50
Eretmochelys imbricata, 4, 6-7, 21-22, 25-26, 46, 94, 105, 108, 112, 120, 122, 129-130, 137-138, 142, 144, 154
epiphysis, see pineal
esophageal arteries, 77-78
esophageal veins, 98
esophagus, 38-39, 69-70, 77, 83, 98, 108-111, 117, 131, 135, 137-140
ethmoid, 125
Eustachian tube, 109, 152
excretory system, 153-155
external iliac arteries, 78, 84
external iliac vein, 100, 102
external jugular vein, 83, 85-98
external nares, 146, 148
external rectus muscle, 150
extrastapedial process, 152
eye muscles, 150-151
eyelids, 147-149 see lids
eyes, 42-43, 59, 115, 125-126, 130, 133, 146-151

F

facial nerve, 68-69, see cranial nerve
femoral scutes, 1-2, 4, 30
femoral artery, 78, 84, 101
femoral nerve, 142-145
femoral vein, 79, 100
femur, 55-58, 70
fibula, 55-58, 70
flexor tibialis, 71-73, 101-102, 144-145
flippers, 2, 5-7, 31-32, 35, 37-38, 43, 51-54, 59, 61-62, 65-67, 77, 99, 141-143, 145
follicles, 41, 157, 159-160, 162
fontanelles, 46, 48, 50
foot extensors, 71, 145
forebrain, 126-127, 139
forelimb muscles, 62, 65
fourth ventricle, 127, 132, 134, 138
frontal bone, 9, 125, 131, 139
frontal scale, 3
frontoparietal scale, 3, 116

G

gallbladder, 39-40, 80, 113, 119
gastric artery, 78, 80-82
gastric vein, 79, 82
gastropulmonary ligament, 106, 111
genital papilla, 153-154, 163
genital papillae, see genital papilla
glandular segment, 160-162, see oviduct
glenoid fossa, 51-52
glomerulus, 154
glossopharyngeal, 68, see cranial nerves

glottis, 38, 44, 105, 108, 134-140
gonadal arteries, 78, 83-84
gonadal ducts, 85, 153, see vas deferens, oviducts, 41, 156-163
gonadal veins, 79, 100
gonads, 40-42, 83, 85, 100, 153, 155, 159
great vessels, 35, 37-38, 76-77, 80, see aortas, pulmonary trunk
greatest length, 29, see carapace length
green turtle, see *Chelonia mydas*
gubernaculum cordis, 37, 38, 74, 76
gular, 4

H

haemorrhoidal artery, 78, 85
Harderian gland, 114, 150-151
hawkbill, see *Eretmochelys imbricata*
head length, 30
head scales, 3, 130
head width, 30
heart, 35, 37, 38, 72-80, 85, 104, 111, 116-117, 119
hepatic portal system, 100, 102-103, 119
hepatic portal vein, 85, 100, 102-103, 119
hepatic vein, 79, 100, 119
hepatopulmonary ligament, 106
hind limbs, 2, 43, 102, 145
hindbrain, 126-127
hip muscles, 71-73, 102, 145
HL, see head length
humeral, 1-2, 4, 31
humerus, 52-55, 59-60, 64, 67, 77, 141, 143
HW, see head width
hyoid, 9, 38, 43-44, 68-70, 95, 105, 109, 131, 138-141
hyoplastron, 50, 121
hypogastric vein, 79, 102
hypoglossal, 68, 127-128, see cranial nerves
hypoplastron, 50, 121
hypothalamus, 127

I

identification, 4-8, 13-27, 50-51
ileum, 39, 103, 108, 112
iliac arteries, 78, 84-86
iliac veins, 79, 100, 102, 154, 163
ilium, 46, 54-56, 71, 143-144
imbricate, 7
inferior mesenteric vein, 103
inferior oblique muscle, 150-151
inferior rectus muscle, 150-151
inframarginal, 4-5, 7-8, 34, 64, 120-122
infundibulum (brain), see pituitary
infundibulum (oviduct), see ostium
inner ear, 146, 151-152
interanal, see anal scutes
intergular scute, 1-2, 31
intermediate segment, 154
intermedium, 52-54
internal brachial vein, 79, 85

internal choanae, see internal nares
internal iliac arteries, 78, 84-85
internal iliac veins, 163
internal nares, 10, 13, 21, 22, 109, 146
internal rectus muscle, 150
interparietal scutes, 3
iris, 147-150
ischial veins, 102
ischiodic nerve, 145
ischial tuberosity, 72
ischium, 54-56, 71

J

Jacobsen's organ, see vomeronasal organ
jaws, 3, 6, 8, 9, 13, 16, 18-19, 21, 23, 26-27, 44-46, 61, 71
jejunum, 41, 110, 114
jugal, 9, 11-12
jugular vein, 72, 81, 84, 87-100, 120

K

Kemp's ridley, see *Lepidochelys kempii*
kidney, 40-42, 83-84, 86, 100, 102, 104, 106, 114, 124, 153-155, 157, 162

L

lamellar bone, 52, 55
large intestine, 38-39, 41, 84, 108
lateral scutes, 1-2, 4-9, 49
lateral ventricles, 132, 134
leatherback, see *Dermochelys coriacea*
left aorta, 38, 40, 74, 76, 78, 80, 82-83, 118
lens, 150-151
Lepidochelys kempii, 4, 7-8, 18, 20, 25, 27, 41, 46, 51, 67, 94, 106-107, 129, 135-136, 146, 164-165
Lepidochelys olivacea, 4, 7-8, 19-20, 25, 27, 67
leptomenix, 125
lids, 147-149
limbus (= limb), 151
lipoidal veins, 79, 100
liver, 37-40, 74-75, 80-81, 102, 106, 108, 111, 113-114, 119, 121, 157
loggerhead, see *Caretta caretta*
longus colli muscles, 68, 70, 80, 98
loop of Henle, 154
lumbosacral plexus, see sacral plexus
lung, 38-42, 74, 76, 83-85, 104-107, 156-158, 162
lymphatic vessels, 74

M

magnum, 160, 162
marginal scutes, 1, 6-7, 28-29, 34, 46, 49, 89-90, 92, 95, 97, 102, 121
marginocostal artery, 77-78, 83
marginocostal vein, 79, 100, 102
maxilla, 9-11, 16-19, 21, 23, 135-136
maxillary, see maxilla

INDEX

- maximum head length, 30
maximum head width, 30
maximum length, 29
Meckel's cartilage, 11
medulla, see brain or kidney
meninges, 94, 125, 134, 137, 139-140
menix, see meninges
mesencephalon, 127
mesenteric arteries, 103
mesenteric vein, 79, 100, 103
mesentery, 39, 103, 120, 157
mesorchium, 156, 162
mesosalpinx, 157-158, 161
mesotubarium, 156-158, 160, 162
mesovarium, 156-157, 158
metacarpal, 52-54
metanephric duct, 152
metatarsal, 56-58
metencephalon, 126-127
methods for dissection, 32-42
midbrain, 126-127, 139
middle ear, 109, 152
minimum length, 29
Müllerian ducts, see oviducts
muscle function, 59, 145
muscles, 35-37, 43, 52-53, 59-72, 85-87, 90, 92-94, 96-99, 101-102, 107, 132, 141-145, 150-151
myelencephalon, 126-127
- N**
nares, 9, 10, 13, 21-22, 111, 116, 134, 148-151
nasal sac, see olfactory sac
nasopharyngeal duct, 126, 133, 146
neck flexors, 68
nephrons, 154
nerves, 42, 59, 64, 68-69, 71, 73, 127-129, 141-145
nervous system, 59, 71, 125-145
neural bones, 45, 47-48
neurocranium, 8-9, 12, 115
neurohypophysis, see pituitary
nictitating membrane, 147-150
nostrils, see external nares
notch-to-notch length, see minimum length
over-the-curve length, see carapace length
nuchal bone, 45, 48, 51
nuchal scute, 2, 6-7, 28-29, 49, 89-95, 97
- O**
oculomotor nerve, see cranial nerves
olfactory bulb, 42, 127, 129, 131-140, 146
olfactory nerve, 127-128, 131-132, 134-141, 146
olfactory sac, 105, 125-126, 131-140, 146
olfactory tracts, 42, see olfactory nerve
olive ridley, see *Lepidochelys olivacea*
opisthotic, 12, 68, 125
optic chiasma, 127, 132
optic lobes, 42, 126-127, 129, 131-137, 141
optic nerve, 127-129, 131-138, 140, 151, see cranial nerves
orbits, 16, 18-20, 23, 42-43, 147
ostium, 157-158, 160-162
otic notch, 9, 11, 151
ovaries, 41, 83, 153, 156-160, see gonads
over-the-curve measurements, 28-30
over-the-curve length, 28
oviducts, 41, 154, 156-162
- P**
palate, 8, 10, 13-19, 21-27, 109, 132-134, 139
palatine, 10, 131
palpebral scales, 147
pancreas, 38-39, 80, 82, 103, 109, 111, 119-120
papilla (esophageal), 110-111, 139-141, 146
papilla (urogenital), 114, 163, 153-154, 165
parathyroid, 116-118
parietal bone, 9, 11-12, 16, 68, 125, 131, 139
parietal notch, 16, 19, 21, 23
parietal scale, 3, 11-12, 16
pectoral apparatus, see pectoral girdle
pectoral artery, 63-64, 77-78
pectoral girdle, 35, 37, 43, 51, 59-60, 64, 107, 111
pectoral muscles, 36, 59-62, 66, 76-77, 82, 85-86, 100, 111, 121, 141-143, 145
pectoral scute, 1-2
pectoral vein, 63, 79, 86, 100
pelvic girdle, 43, 54-55, 59-60, 107, 114
pelvic muscles, 100, 102, 143-145
pelvic vein, 61, 100
pelvis, see pelvic girdle
penis, 102, 153, 162-164
pericardial sac, 74
pericardial veins, 79, 100
pericardium, 37-38, 63, 74-76, 111
peripheral bones, 42, 45-46, 48, 50, 64
peripheral nerves, 141-145
peritoneum, 35-37, 40, 74, 76, 100, 106, 114, 119, 121, 153, 157, 162
peroneal nerve, 71, 73, 143-145
phalanges, 43, 52-54, 55-58
pia mater, see leptomenix
pineal, 116, 127, 129, 131-132, 134-140
pisiform, 52-54, 67
pituitary, 42, 115-116, 127-128, 131-132, 134, 136, 140
PL, see plastron length
plastron length, 31
plastron, 1-2, 4-6, 31-32, 34-35, 42-43, 46, 50-51, 59, 110, 121-123, 165
pleural bones, 2, 45, 48, 64
popliteal veins, 100-101
pores, 4, 7-8, 35, 121-123
portal systems, 79, 100, 119
postcava, 79, 84, 100
postcentral scutes, 2, 28, see suprapygal scute
posterior muscles, 58-60, 71-74, 102
posterior pancreatic veins, 79, 103
posterior pancreaticoduodenal artery, 80
postorbital bone, 9, 11-12, 18
precava, 76, 79, 85, 88, 98-99
prefrontal bone, 9
prefrontal scale, 2, 4-6
premaxilla, 9-11, 16, 18-19, 21, 131, 134, 139
prootic, 12, 68, 125
proximal tubule, 154
pterygoid, 9-10, 12, 19, 131, 136
pterygoideus muscle, 70
PVTL, see tail length
pubis, 41, 54-56, 59, 61, 111, 154-155
puboischiofemoralis, 71-73, 145
pubotibialis, 71-73, 101, 145
pulmonary artery, 37-38, 74-78, 104-105
pulmonary system, 105-107
pulmonary trunk, 38, 76-78, 84, 104
pulmonary veins, 79, 85, 104
pupil, 147-151
pygal, 45, 48
pyloric sphincter, 39, 81, 108, 111-113
pyramidalis muscle, 150-151
- Q**
quadrate, 11
quadratojugal, 11-12, 69, 151
- R**
radial artery, 77-78
radial nerve, 64, 141-143, 145
radiale, 52
radius, 52-54, 59, 67
Rathke's glands, 120-123
Rathke's pores, 8, 35, 121-123
recessus cavi tympani, 152
rectum, 38-41, 102, 108, 112, 114, 153-154, 163
renal arteries, 78, 83-84, 86, 154, 156
renal capsule, 154
renal corpuscles, 154
renal portal vein, 79, 100, 102, 154
renal veins, 114, 154, 157
respiratory muscles, 59, 62, 64, 141, 142-145
rete system, 85
retina, 150-151
rhamphotheca, 6, 26-27, 30, 131, 132
ribs, 43, 45-51
right aorta, 38, 40, 75-78, 83, 118
rods, 151
- S**
sacral plexus, 71, 141, 143-145, 155
sacral vertebrae, 45-46, 54-55, 143, 155
salt gland, 42, 115, 125, 139-140, 146, 150-151
scales, 1-8, 13, 116, 122-123, 151-152
scapula, 37, 51, 52, 59, 64-67, 77, 83, 85, 88, 99
scapular vein, 79, 85, 99
sciatic artery, 78, 84-85, 101

INDEX

- sciatic nerve, 73, 101, 143-145
scleral ossicles, 43, 150
SCLmax, see carapace length
SCLmin, see carapace length
scutes, 1-2, 4-7, 29, 31, 34, 46, 49, 102, 120-122, 165
SCW, see carapace width
secondary palate, 16-18, 21-23
sella tursica, 115-116, 128, 132
semicircular canals, 152
sense organs, 8, 146-152
sexual dimorphism, 164-165
shell gland, see glandular segment
shell membrane, 162
shoulder muscles, 62, 64, 66-67, 99, 107, 140, 143
sinus venosus, 38, 74, 76, 79, 85, 100, 111, 119
skull, 8-25, 42-44, 115, 128-129, 132-140, 152
small intestine, 38-39, 103, 108, 111-112, 120-121
snout, 5, 8, 13, 16, 18, 20-21, 26-27, 42
species identification, 1-27, 50-51
spinal accessory nerves, 127-129, see cranial nerves
spinal cord, 47, 127, 129, 138-139, 141
SPL, see plastron length
splachnocranium, 8-9
spleen, 39, 82, 103, 108, 119-120
splenial, 9, 11
splenic vein, 79, 103
squamosal, 9, 11-12, 17, 68-69, 151
standard carapace length, 28
standard measurements, 28-32
stapes, 12, 152
statoacoustic nerve, see cranial nerves, acoustic nerve
stomach, 38-39, 80-82, 102-103, 106, 108-112, 119-121
straightline carapace lengths 28-29
straightline measurements, 28-31
subclavian arteries, 38, 76-78, 99, 115-118
subclavian vein, 79, 84, 88
sulcus spermaticus, see urethral groove
superficial limb retractors, 61, 72
superior mesenteric artery, 78, 80
superior oblique muscle, 150-151
superior rectus muscle, 150-151
superior vena cava, 85, 88, see precava
supernumery scales, 3
supracaudal scute, 2, 28, 49
supraoccipital, 9, 16, 30, 68, 70, 125, 131, 134, 137, 139
supraocular scales, see scales
suprapygal bone, 45, 48
suprapygal scutes, see supracaudal
- T**
tail length, 32, 164
tail, 46, 68, 72-73, 83, 85
- tapetum lucidum, 151
tarsals, 56, 57
taste buds, 148
tela choroidea, 125-126, 131-132
telencephalon, 126-127
temporal bone, see squamosal
temporal scale, 3
tendons, 59, 64-65, 67-68, 71, 101
terminology, 1, 85, 145
testes, see testis, gonads
testis, 40-41, 82, 100, 114, 153, 156, 159, 162, 163, see gonads
thalamus, 127
third ventricle, 127, 132, 134
thoracodorsal artery, 99
thymus, 35, 38, 76, 116-118
thyroid artery, 38, 76-78, 116
thyroid, 35, 37-38, 76-77, 85, 116-117
thyroscapular vein, 79, 85
tibia, 57-58
tibial nerve, 71, 143-145
tibial vein, 100
TTL, see tail length
tongue, 38, 44, 68, 105, 108-109, 131, 133, 135-136, 138-140, 146
tools, 33
trachea, 37-41, 69-70, 76, 95-96, 105-106, 109, 111, 117, 131, 133, 135, 137-139
transverse branch, see transverse cervical branch
transverse cervical branch, 87, 94-95
transverse cervical muscles, 68, 86-97
trigeminal nerve, 68, 127-129, see cranial nerves
trochlear nerve, 127, 150, see cranial nerves
tympanic cavity, 152, see otic notch
tympanic scale, 3, 151
tympanum, 151-153
- U**
ulna, 52-54
ulnar artery, 77-78
ulnar nerve, 141-143, 145
ulnare 52-54
ultimobranchial bodies, 116-118
ureters, 41-42, 114, 153-154
urethral groove, 163
urinary bladder, 40-41, 114, 153-155, 158
urinary papilla, 114, 153-154
urodeum, 114, 153, 157, 160
urogenital papilla, 153-154
urogenital system, 41, 153-165
uvea, 150-151
- V**
vagina, 160, 162
vagus nerve, 98, 127-128, see cranial nerves
vas deferens, 41, 156, 159, 162-163
vascular circumflex, 85
- veins, 79, 82, 85-98, 100-104, 114, 119, 125, 153, 157, 161, 163
ventral cervical arteries, 77, 95, 117-118
ventral hip muscles, 71-73, 145
ventral muscles, 59-60, 62, 65, 107, 143
ventral neck muscles, 68-69
ventricle (of brain), 126-128, 132, 134, 136, 138
ventricle (of heart), 38, 74-77, 102-104, 111, 118, 121
vertebrae, 47-48, 141-143, 155
vertebral arch, 45, 47
vertebral artery, 78, 84-85, 95
vertebral body, 9, 45, 47
vertebral branches, 83, 88-96
vertebral column, 41-42, 45, 102, 106-107
vertebral scutes, 1-2, 4, 6, 8, 49
vertebral vein, 79, 88-89, 93, 102
vesicular veins, 78, 100
vestibular, 146, 152
vision, 147-151
vitreous body, 150
vomer, 10, 18-19, 21
vomeronasal organ, 146
VTTL, see tail length
- X**
xiphiplastron, 50