

A Histopathologic Evaluation of Gross Lesions Excised from Commercially Important North Atlantic Marine Fishes

Robert A. Murchelano
Linda Despres-Patanjo
John Ziskowski



U.S. DEPARTMENT OF COMMERCE
National Oceanic and Atmospheric Administration
National Marine Fisheries Service

NOAA TECHNICAL REPORT NMFS

The major responsibilities of the National Marine Fisheries Service (NMFS) are to monitor and assess the abundance and geographic distribution of fishery resources, to understand and predict fluctuations in the quantity and distribution of these resources, and to establish levels for their optimum use. NMFS is also charged with the development and implementation of policies for managing national fishing grounds, development and enforcement of domestic fisheries regulations, surveillance of foreign fishing off United States coastal waters, and the development and enforcement of international fishery agreements and policies. NMFS also assists the fishing industry through marketing service and economic analysis programs, and mortgage insurance and vessel construction subsidies. It collects, analyzes, and publishes statistics on various phases of the industry.

The NOAA Technical Report NMFS series was established in 1983 to replace two subcategories of the Technical Reports series: "Special Scientific Report—Fisheries" and "Circular." The series contains the following types of reports: Scientific investigations that document long-term continuing programs of NMFS; intensive scientific reports on studies of restricted scope; papers on applied fishery problems; technical reports of general interest intended to aid conservation and management; reports that review in considerable detail and at a high technical level certain broad areas of research; and technical papers originating in economics studies and from management investigations. Since this is a formal series, all submitted papers receive peer review and those accepted receive professional editing before publication.

Copies of NOAA Technical Reports NMFS are available free in limited numbers to governmental agencies, both Federal and State. They are also available in exchange for other scientific and technical publications in the marine sciences. Individual copies may be obtained from: U.S. Department of Commerce, National Technical Information Service, 5285 Port Royal Road, Springfield, VA 22161.

1. Synopsis of biological data on the Blue Crab, *Callinectes sapidus* Rathbun, by Mark R. Millikin and Austin B. Williams. March 1984, 39 p.
2. Development of hexagrammids (Pisces: Scorpaeniformes) in the Northeastern Pacific Ocean, by Arthur W. Kendall, Jr., and Beverly Vinter. March 1984, 44 p.
3. Configurations and relative efficiencies of shrimp trawls employed in southeastern United States waters, by John W. Watson, Jr., Ian K. Workman, Charles W. Taylor, and Anthony F. Serra. March 1984, 12 p.
4. Management of northern fur seals on the Pribilof Islands, Alaska, 1786-1981, by Alton Y. Roppel. April 1984, 26 p.
5. Net phytoplankton and zooplankton in the New York Bight, January 1976 to February 1978, with comments on the effects of wind, Gulf Stream eddies, and slope water intrusions, by Daniel E. Smith and Jack W. Jossi. May 1984, 41 p.
6. Ichthyoplankton survey of the estuarine and inshore waters of the Florida Everglades, May 1971 to February 1972, by L. Alan Collins, and John H. Finucane. July 1984, 75 p.
7. The feeding ecology of some zooplankters that are important prey items of larval fish, by Jefferson T. Turner. July 1984, 28 p.
8. Proceedings of the International Workshop on Age Determination of Oceanic Pelagic Fishes: Tunas, Billfishes, and Sharks, by Eric D. Prince (convener and editor), and Lynn M. Pulos (editor). December 1983, 211 p.
9. Sampling statistics in the Atlantic menhaden fishery, by Alexander J. Chester. August 1984, 16 p.
10. Proceedings of the Seventh U.S.-Japan Meeting on Aquaculture, Marine Finfish Culture, Tokyo, Japan, October 3-4, 1978, by Carl J. Sindermann (editor). August 1984, 31 p.
11. Taxonomy of North American fish Eimeriidae, by Steve J. Upton, David W. Redeker, William L. Current, and Donald W. Duszynski. August 1984, 18 p.
12. Soviet-American Cooperative Research on Marine Mammals. Volume I—Pinnipeds, by Francis H. Fay, and Gennadii A. Fedoseev (editors). September 1984, 104 p.
13. Guidelines for reducing porpoise mortality in tuna purse seining, by James M. Coe, David B. Holts, and Richard W. Butler. September 1984, 16 p.
14. Synopsis of biological data on shortnose sturgeon, *Acipenser brevirostrum* LeSueur 1818, by Michael J. Dadswell, Bruce D. Taubert, Thomas S. Squiers, Donald Marchette, and Jack Buckley. October 1984, 45 p.
15. Chaetognatha of the Caribbean sea and adjacent areas, by Harding B. Michel. October 1984, 33 p.
16. Proceedings of the Ninth and Tenth U.S.-Japan Meetings on Aquaculture, by Carl J. Sindermann (editor). November 1984, 92 p.
17. Identification and estimation of size from the beaks of 18 species of cephalopods from the Pacific Ocean, by Gary A. Wolff. November 1984, 50 p.
18. A temporal and spatial study of invertebrate communities associated with hard-bottom habitats in the South Atlantic Bight, by E. L. Wenner, P. Hinde, D. M. Knott, and R. F. Van Dolah. November 1984, 104 p.
19. Synopsis of biological data on spottail finfish, *Diplodus holbrooki* (Pisces: Sparidae), by George H. Darcy. January 1985, 11 p.
20. Ichthyoplankton of the Continental Shelf near Kodiak Island, Alaska, by Arthur W. Kendall, Jr., and Jean R. Dunn. January 1985, 89 p.
21. Annotated bibliography on hypoxia and its effects on marine life, with emphasis on the Gulf of Mexico, by Maurice L. Renaud. February 1985, 9 p.
22. Congrid eels of the eastern Pacific and key to their Leptocephali, by Solomon N. Raju. February 1985, 19 p.
23. Synopsis of biological data on the pinfish, *Lagodon rhomboides* (Pisces:Sparidae), by George H. Darcy. February 1985, 32 p.
24. Temperature conditions in the cold pool 1977-81: A comparison between southern New England and New York transects, by Steven K. Cook. February 1985, 22 p.
25. Parasitology and pathology of marine organisms of the world ocean, by William J. Hargis, Jr. (editor). March 1985, 135 p.
26. Synopsis of biological data on the sand perch, *Diplectrum formosum* (Pisces: Serranidae), by George H. Darcy. March 1985, 21 p.
27. Proceedings of the Eleventh U.S.-Japan Meeting on Aquaculture, Salmon Enhancement, Tokyo, Japan, October 19-20, 1982, by Carl J. Sindermann (editor). March 1985, 102 p.
28. Review of geographical stocks of tropical dolphins (*Stenella* spp. and *Delphinus delphis*) in the eastern Pacific, by William F. Perrin, Michael D. Scott, G. Jay Walker, and Virginia L. Cass. March 1985, 28 p.
29. Prevalence, intensity, longevity, and persistence of *Anisakis* sp. larvae and *Lacis-torhynchus tenuis* metacystodes in San Francisco striped bass, by Mike Moser, Judy A. Sakanari, Carol A. Reilly, and Jeannette Whipple. April 1985, 4 p.
30. Synopsis of biological data on the pink shrimp, *Pandalus borealis* Kröyer, 1838, by Sandra E. Shumway, Herbert C. Perkins, Daniel F. Schick, and Alden P. Stickney. May 1985, 57 p.
31. Shark catches from selected fisheries off the U.S. east coast, by Emory D. Anderson, John G. Casey, John J. Hoey, and W. N. Witzell. July 1985, 22 p.
32. Nutrient Distributions for Georges Bank and adjacent waters in 1979, by A. F. J. Draxler, A. Mattc, R. Waldhauer, and J. E. O'Reilly. July 1985, 34 p.
33. Marine flora and fauna of the Northeastern United States. Echinodermata: Echinoidea, by D. Keith Serafy and F. Julian Fell. September 1985, 27 p.
34. Additions to a revision of the shark genus *Carcharhinus*: Synonymy of *Aprionodon* and *Hypoprion*, and description of a new species of *Carcharhinus* (Carcharhinidae), by J. A. F. Garrick. November 1985, 26 p.
35. Synoptic review of the literature on the Southern oyster drill *Thais haemastoma floridana*, by Philip A. Butler. November 1985, 9 p.

NOAA Technical Report NMFS 37

A Histopathologic Evaluation of Gross Lesions Excised from Commercially Important North Atlantic Marine Fishes

Robert A. Murchelano
Linda Despres-Patanjo
John Ziskowski

March 1986



U.S. DEPARTMENT OF COMMERCE

Malcolm Baldrige, Secretary

National Oceanic and Atmospheric Administration

John V. Byrne, Administrator

National Marine Fisheries Service

William G. Gordon, Assistant Administrator for Fisheries

The National Marine Fisheries Service (NMFS) does not approve, recommend or endorse any proprietary product or proprietary material mentioned in this publication. No reference shall be made to NMFS, or to this publication furnished by NMFS, in any advertising or sales promotion which would indicate or imply that NMFS approves, recommends or endorses any proprietary product or proprietary material mentioned herein, or which has as its purpose an intent to cause directly or indirectly the advertised product to be used or purchased because of this NMFS publication.

Contents

Introduction 1

Materials and Methods 1

Results 1

Lesions of Western North Atlantic Fishes 3

Integument 3

Gill 3

Gastrointestinal tract 4

Gonad 5

Heart 5

Liver 5

Spleen 6

Muscle 6

Miscellaneous 7

Lesions of Eastern North Atlantic Fishes 8

Integument 8

Gill 8

Gastrointestinal tract 8

Heart 8

Kidney 8

Liver 9

Spleen 9

Muscle 9

Miscellaneous 9

Discussion 9

Acknowledgments 14

Literature cited 14

A Histopathologic Evaluation of Gross Lesions Excised from Commercially Important North Atlantic Marine Fishes

ROBERT A. MURCHELANO

*Northeast Fisheries Center,
National Marine Fisheries Service, NOAA,
Oxford, Maryland 21654*

LINDA DESPRES-PATANJO

*Northeast Fisheries Center,
National Marine Fisheries Service, NOAA,
Woods Hole, Massachusetts 02543*

JOHN ZISKOWSKI

*Northeast Fisheries Center,
National Marine Fisheries Service, NOAA,
Highlands, New Jersey 07732*

ABSTRACT

Histopathologic studies of lesions found in commercially important North Atlantic marine fishes are uncommon. As part of a comprehensive Northeast Fisheries Center program ("Ocean Pulse") to evaluate environmental and resource health on the U.S. Continental Shelf from Cape Hatteras to Nova Scotia, grossly visible lesions of the gills, integument, muscle, and viscera of primarily bottom-dwelling fishes were excised and examined using light microscopy.

Several gadid and pleuronectid fishes accounted for most of the lesions observed. Most pathological examinations were incidental to samples taken for age and growth determination and evaluation of predator/prey relationships. Several gadids, with either gill, heart, or spleen lesions, were sampled more intensively.

Gill lesions principally affected gadids and were caused by either microsporidans or an unidentified oocyte-like cell. The majority of gastrointestinal lesions consisted of encapsulated or encysted larval worms or microsporidan-induced cysts. Few heart lesions were found. Integumental lesions included ulcers, lymphocystis, and trematode metacercariae. Liver lesions almost always consisted of encapsulated or encysted larval helminths. Necrotic granulomata were seen in muscle and microsporidan-induced granulomata in spleen.

Although not numerous, histologically interesting lesions were noted in integument, heart, liver, spleen, and muscle of several fish species. Histologic study of tissues excised from a variety of demersal and pelagic fishes from the eastern North Atlantic (France, Germany, Spain) revealed assorted integumental, renal, hepatic, and splenic lesions.

Small sample size and non-random sampling precluded obtaining a meaningful quantitative estimate of the prevalence of the observed lesions in the population at risk; however, a useful census has been made of the types of lesions present in commercially important marine fishes.

INTRODUCTION

Much attention has been given recently to the health status of commercially important marine fishes. Although several pollution-associated diseases have been identified (Sindermann 1979; Sindermann et al. 1980; Murchelano 1982), statistical analyses and laboratory experimentation to corroborate the validity of field observations often are lacking or inconclusive. Despite these limitations, identification of the diseases present in the population at risk is necessary before baselines can be established to assess future changes. Surveys of fish disease prevalence, supplemented with simultaneous environmental studies, may yield useful data. Incidental to the conduct of seasonal stock assessment surveys in the western North Atlantic from Cape Hatteras to Nova Scotia, grossly visible integumental, respiratory, and visceral lesions were excised for laboratory study. The histopathology of these lesions and of others from fishes sampled in the eastern North Atlantic are the subject of this report.

MATERIALS AND METHODS

Randomly selected stations in depth-defined strata are sampled bi-annually (spring, fall) on the U.S. Continental Shelf between Cape Hatteras and Nova Scotia to determine fish abundance and distribution. Research vessels (*Albatross IV*, *Delaware II*) make 30-min tows at each station using a standard No. 36 Yankee otter trawl. After sorting and weighing the catch, requisite examinations are made to provide data on species composition and abundance, age and growth, fecundity, maturity, and food habits. From 1979 to 1982, fishes sampled for age, growth, and food habit studies were also examined for the presence of gross gill, integumental, muscle, and visceral lesions. Biologists were asked to excise lesions from organs which deviated distinctly from the norm in color, configuration, and size. Prior to sampling they were advised to necropsy 10-15 fishes of a given species to determine normal organ variability. Lesions were excised as time permitted. Although this method was practically expedient, there can be little doubt that, eventually, sampling emphasized the excision of cysts, nodules, and other grossly recognizable anatomic modifications ("lumps and bumps"). A total of 350 lesions were excised and fixed in 10% seawater formalin in appropriate containers. At the laboratory, tissues were routinely dehydrated, embedded in paraffin, sectioned ($\sim 6 \mu\text{m}$), and stained (hematoxylin and eosin—H&E; azure eosin—AZE; periodic acid Schiff—PAS; Ziehl-Neelsen—ZN; Feulgen; Grocott).

In 1979, 1980, and 1982, tissues with lesions were obtained from fishes from the German Bight and North Sea, the Atlantic coasts of France and Spain, and the English Channel. These tissues were obtained on cruises conducted specifically to estimate fish disease prevalence. The tissues were prepared for microscopic examination as described above.

RESULTS

Altogether, 416 lesions were examined microscopically—350 from fishes of the western North Atlantic and 66 from fishes from the eastern North Atlantic. Tables 1 and 2 list the fish species examined and the number of lesions excised from particular tissues.

Table 1.—Number of grossly visible lesions excised from fish of the western North Atlantic, sampled on stock assessment cruises in 1979-82.

Fish examined (N=350)	No. lesions									
	Gill	Gonad	Gut	Heart	Integument	Liver	Muscle	Spleen	Misc.	Total
American plaice (9) (<i>Hippoglossoides platessoides</i>)					7		2			9
Cod (107) (<i>Gadus morhua</i>)	23	1	11	19	20	10	4	31	2	121
Cusk (2) (<i>Brosme brosme</i>)							2			2
Goosefish (4) (<i>Lophius americanus</i>)			1			1			2	4
Haddock (36) (<i>Melanogrammus aeglefinus</i>)	18		5		3	1	3		6	36
Mackerel (4) (<i>Scomber scombrus</i>)	1		3							4
Ocean pout (7) (<i>Macrozoarces americanus</i>)					5		2			7
Pollack (11) (<i>Pollachius virens</i>)	2		1		1	5	1	1		11
Redfish (3) (<i>Sebastes marinus</i>)							3			3
Red hake (28) (<i>Urophycis chuss</i>)	18		2		4	4				28
Silver hake (32) (<i>Merluccius bilinearis</i>)	20	2				5	1		2	30
White hake (26) (<i>Urophycis tenuis</i>)	11	1	7		4	1	2			26
Windowpane (8) (<i>Scophthalmus aquosus</i>)		1	4		3					8
Winter flounder (40) (<i>Pseudopleuronectes americanus</i>)	1		15		21	3				40
Yellowtail flounder (33) (<i>Limanda ferruginea</i>)			12		8	12			1	33
Total	94	5	61	19	76	42	20	32	13	

Table 2.—Number of grossly visible lesions excised from fish of the eastern North Atlantic, sampled on cruises in 1979, 1980, and 1982.

Fish examined (N=66)	No. lesions										
	Gill	Gonad	Gut	Heart	Integument	Kidney	Liver	Muscle	Spleen	Misc.	Total
Blue whiting (8) (<i>Gadus poutassou</i>)	6						4				10
Cod (10) (<i>Micromesistius poutassou</i>)	1	1		1	1	4	4	2	7		21
Dab (12) (<i>Limanda limanda</i>)			1		10			1			12
Flounder (7) (<i>Platichthys flesus</i>)					6			1			7
Goosefish (8) (<i>Lophius piscatorius</i>)										8	8
Mackerel (16) (<i>Scomber scombrus</i>)	1	1	6			3	4		8		23
Whiting (5) (<i>Merluccius merluccius</i>)	2		1				3				6
All	10	1	2	8	17	7	15	4	15	8	

Lesions of Western North Atlantic Fishes

Integument—Integumental lesions accounted for 21% of the gross abnormalities observed, and ulcers and lymphocystis for 44% and 20%, respectively, of the skin lesions. More ulcers were found in cod (*Gadus morhua*) than in any other species. Ulcers were of varying size and either solitary or multiple. Histologically, their appearance was similar in all species. Epidermis contiguous to the ulcer tended to be hyperplastic and spongiotic. In the dermis, scales were either degenerate or not present, and scale pockets were edematous. Areas of granulomatous inflammation extended from the dermis to the hypodermis and at times into subjacent muscle. Inflammatory tissues contained congested blood vessels as well as frank hemorrhage. Bacteria were sometimes present (usually topically). When adjacent muscle was affected, the fibers were either atrophic or necrotic, and leukocytic infiltrates were present. Ulcers with large areas of fibrous tissue were presumed to be resolving.

Lymphocystis was found only in American plaice (*Hippoglossoides platessoides*) and winter flounder (*Pseudopleuronectes americanus*). Lymphocystis lesions were evident as foci of hypertrophied cells containing Feulgen-positive (Fig. 1), finely granular, basophilic, intracytoplasmic inclusions. Cell nuclei were either karyorrhectic or not present. Frequently, the enlarged cells were bordered by erythrocyte cuffs. The dermis was fibrotic and contained infiltrates of mononuclear leukocytes and areas of hemorrhage. The covering epidermis usually was markedly hyperplastic. "X" cell lesions were found in the dermis of two ocean pout (*Macrozoarces americanus*) (Fig. 2). Histologically, they consisted of masses of "X" cells separated by connective tissue trabeculae. The lesions' microscopic appearance was similar to that of cod pseudobranch adenomas (Wellings 1969; Lange 1973).

Gill—In the fishes examined from the western North Atlantic, gill lesions were most numerous and accounted for 26% of the abnormalities noted. In 44% of the gill lesions, the causative agent could

not be identified but consisted of a large oocyte-like cell occupying the intralamellar space (Fig. 3). The cell was clearly demarcated by a well-defined PAS-negative wall. Proliferation of fibrous tissue around the cell in some instances caused lamellar fusion. The fibrous tissue contained small, well-defined blood vessels as well as large, blood-filled lacunae. Examination of AZE, Grocott, and Feulgen-stained sections was not informative. The oocyte-like cell was noted in gill tissues of cod, haddock (*Melanogrammus aeglefinus*), red hake (*Urophycis chuss*), silver hake (*Merluccius bilinearis*), and white hake (*Urophycis tenuis*). The second most common gill lesion noted was caused by microsporidians (17%) and found only in cod and haddock (Morrison and Sprague 1981) (Fig. 4). Interlamellar cysts were well-defined and, other than the elaboration of a connective tissue capsule, caused no appreciable host response. The only other grossly evident gill lesions were found in cod. In six fish (6%) with severely eroded gills, histologic changes included epithelial hyperplasia, necrosis, and mononuclear infiltration, congestion, and hemorrhage. Denuded gill filaments were colonized by an abundant and morphologically diverse bacterial flora. Blood vessels in the affected areas contained numerous mononuclear leukocytes. Macrophages were present in necrotic tissue areas. Four of the gills were colonized by microsporidians. All eroded gills contained chitinous tissue fragments which probably were crustacean in origin. It is likely, therefore, that the lesions observed were caused by parasitic copepods. The only other lesion noted on cod was a pseudobranch adenoma. At present, the primary constituent cell ("X" cell) of this tumorous mass is believed to be amebic (Dawe et al. 1979; Dawe 1981). Gill lesions incidentally noted (those not associated with an obvious gross lesion) included chronic, non-specific, granulomatous inflammation (cod, haddock, white hake), and ones caused by *Trichodina* (cod), *Oodinium* (cod), and encysted trematode metacercariae (white hake). In many instances (23%), grossly visible nodular lesions on gills (cysts, nodules), because of their small size and solitary occurrence, did not survive the preparative procedures required for microscopic examination.

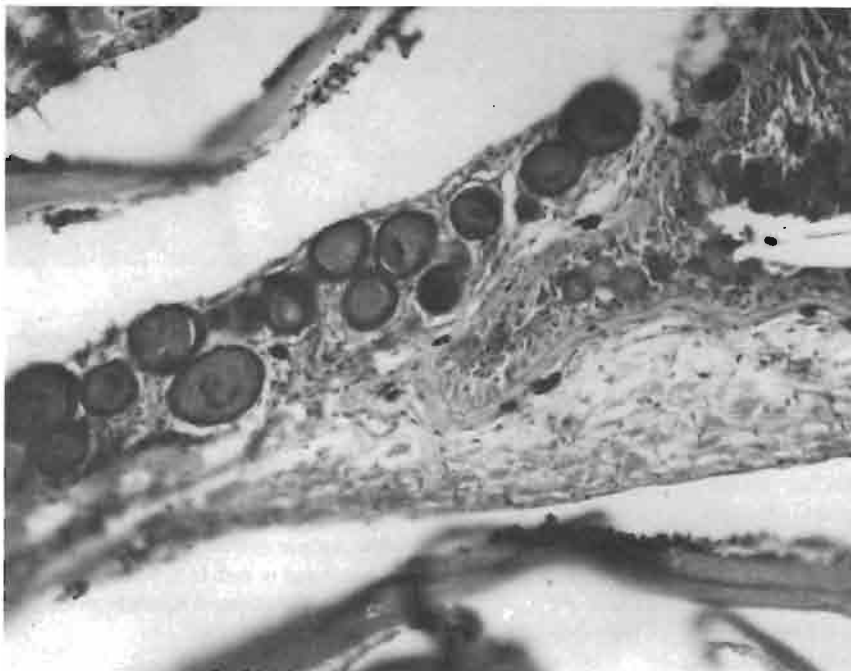


Figure 1.—Hypertrophic fibroblasts characteristic of lymphocystis containing viral inclusions in scale pocket of American plaice (H&E, $\times 200$).

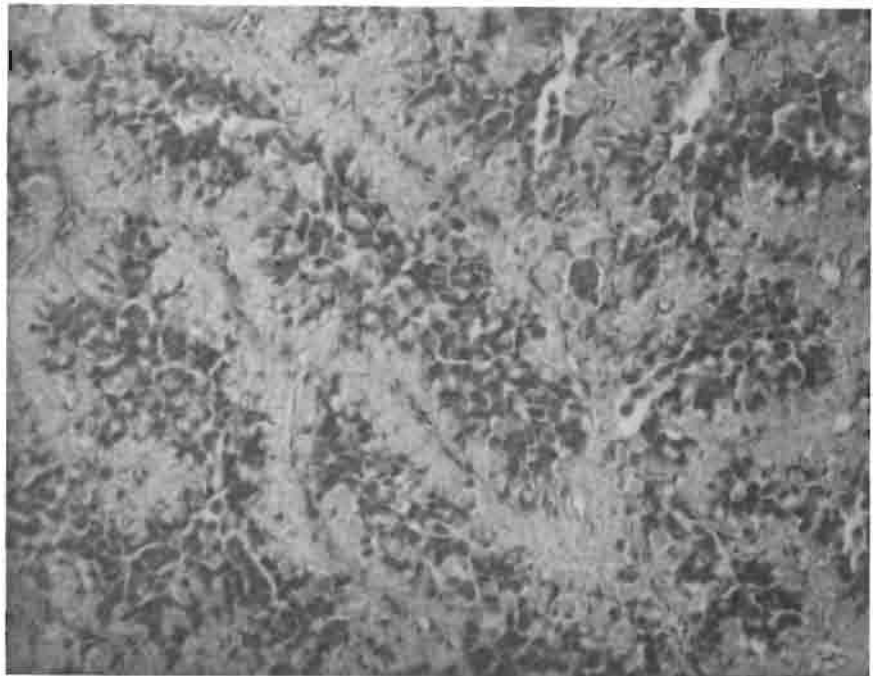


Figure 2.—Cord containing “X” cells in dermis of ocean pout (H&E, × 200).

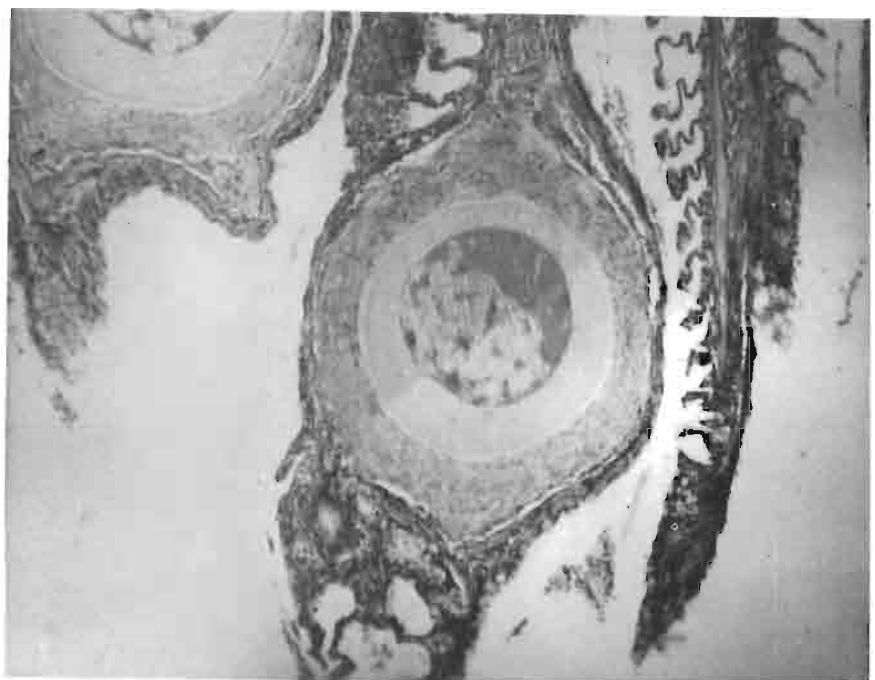


Figure 3.—Unidentified oocyte-like cell in gill of cod (H&E, × 100).

Gastrointestinal tract—There were 61 gastrointestinal tract lesions, of which 25 (4%) were caused by encysted larval cestodes. Thirty-three percent of the cestode cysts were found in yellowtail flounder (*Limanda ferruginea*). Other fishes with larval cestode cysts included cod (3), haddock (3), mackerel (*Scomber scombrus*) (2), red hake (1), silver hake (1), white hake (2), windowpane flounder (*Scophthalmus aquosus*) (3), and winter flounder (1). In several instances, sections disclosed obvious cystic structures which lacked worms. Larval cestodes in the serosa of the digestive tract caused essentially no host response other than the elaboration of a thin capsule. However, some cestodes in the muscularis of the gut caused extensive inflammation and muscle necrosis. Most of the cellular infiltrate

consisted of mononuclear leukocytes, macrophages, and occasionally eosinophiles. The worms eliciting this response did not always appear to be dead. Ten lesions (16%) of the gastrointestinal tract were caused by microsporidians (*Glugea stephani*) (Fig. 5), all found in the intestinal tract of the winter flounder. The number and size of the cysts varied extensively. Cysts were located either in the serosa or in the muscularis and, when numerous, were enclosed in a fibrous, connective tissue matrix. Intramuscular cysts caused substantial compression of the subjacent mucosa and in rare instances appeared to cause mucosal ulceration. The submucosa frequently contained leukocyte infiltrates.

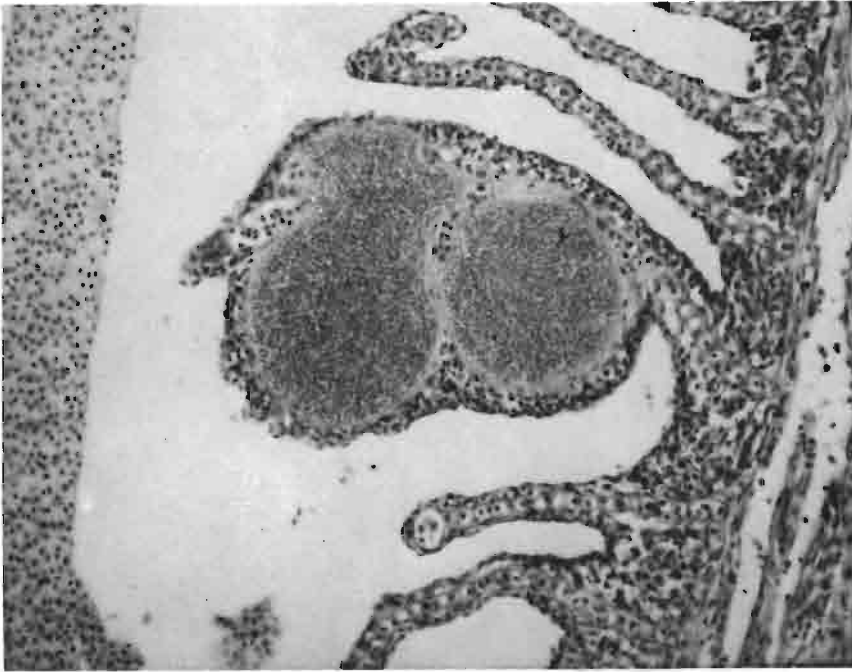

Figure 4.—Microsporidan (*Loma morhua*) cysts in gill of cod (H&E, × 200).

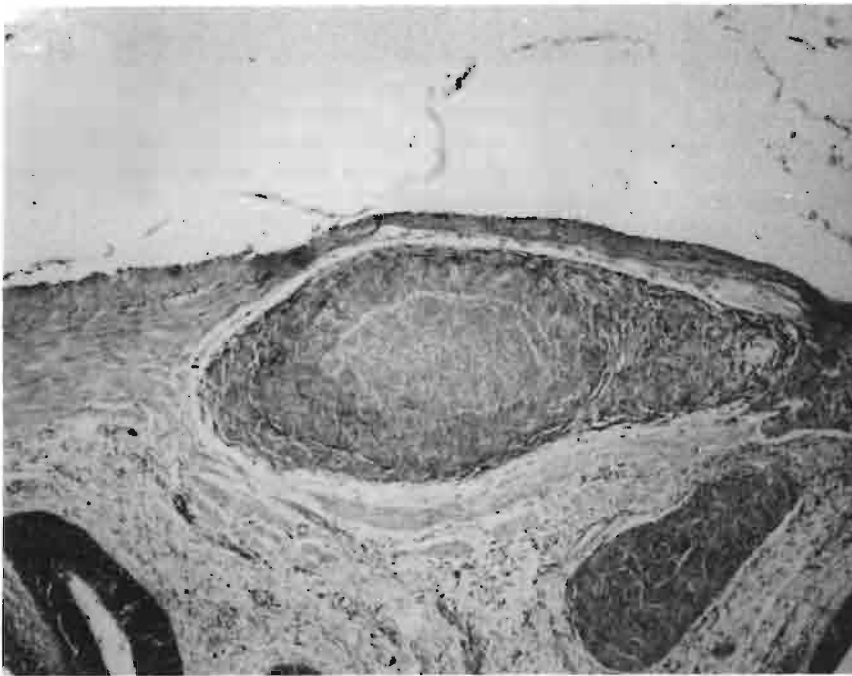


Figure 5.—Microsporidan cyst (*Glugea stephani*) in intestinal wall of winter flounder (H&E, × 100).

Gonad—Five gonadal abnormalities were noted grossly (cod, silver and white hake, windowpane flounder); however, only one could be substantiated microscopically. Encysted larval cestodes and nematodes were present on the gonadal surface of a silver hake. No conspicuous host response was apparent.

Heart—The 19 heart lesions (5%) were found exclusively in cod; all were caused by microsporida and were located in the epicardium and/or myocardium (atrium and ventricle). Discrete granulomata composed of epithelioid cells and fibroblasts enclosed the spore aggregates (Fig. 6). Early lesions exhibited no host response and consisted of only a parasitic mass (either free or membrane bound).

Other lesions were infiltrated by mononuclear leukocytes, causing a focal myocarditis. A diffuse epicarditis with infiltrates of mononuclear leukocytes was present in some tissues. Lesions in atrial tissues caused hyperplasia and hypertrophy of endothelial macrophages.

Liver—As was true with the gastrointestinal tract, lesions of the liver were usually associated with encysted larval cestodes or nematodes. Cysts were found in cod, haddock, pollack (*Pollachius virens*), red hake, silver hake, white hake, goosfish (*Lophius americanus*), winter flounder, and yellowtail flounder, and accounted for 31% of the liver lesions examined. Larval worms (cestodes, nematodes) were

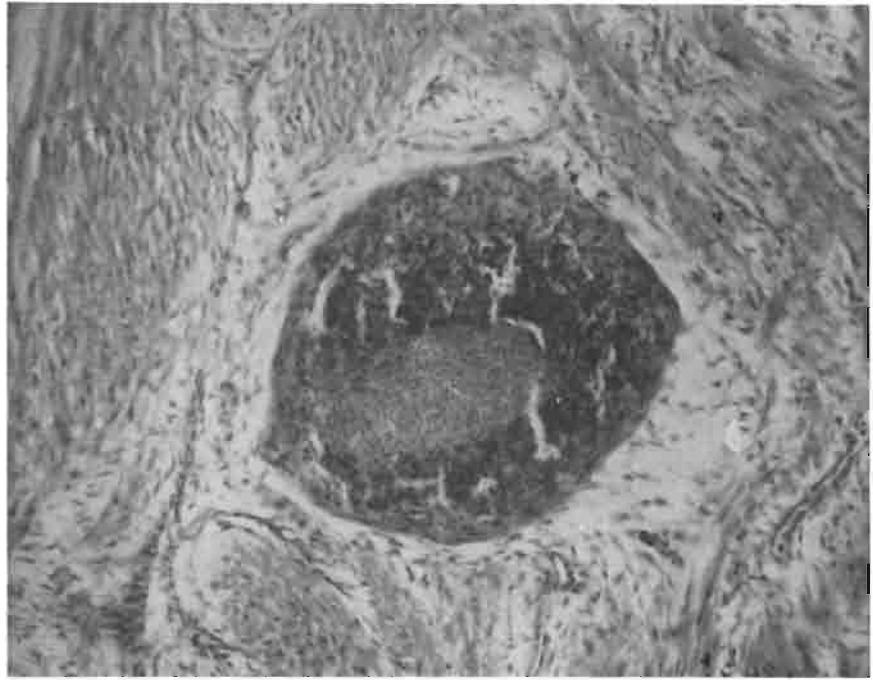


Figure 6.—Granuloma containing microsporidan (*Loma morhua*) in ventricle of cod heart (H&E, × 200).

found both on the surface of the liver and deep within its parenchyma. Some encysted worms caused only space-occupying lesions with little apparent host response; others were isolated by a laminar, fibrous capsule. In some instances, epithelioid cells were also present. Dead and degenerate worms provoked a host response involving mononuclear and polymorphonuclear leukocytes, macrophages, and fibroblasts. “Empty” cysts containing eosinophilic debris, red blood cells, and occasionally bacteria in tissues with visible worms were also presumed to be worm-induced. Hepatic lesions due to worms rarely involved substantial amounts of liver parenchyma. Although focal areas of necrosis and fibrosis were seen in many sections, large necrotic and fibrotic areas were rarely seen. Liver lesions caused by microsporidans were noted in cod, winter flounder, and yellow-tail flounder. Multiple parasitic aggregates (presumably *Loma morhua*), some free and others clearly within a thin, fibrous capsule, were noted in cod. In one section, encysted parasites were also visible in the lumen of a large hepatic vein (Fig. 7). The cysts were bordered by a fibrous capsule which, in the winter flounder, had distinct collagenous layers. The winter flounder lesions were extensive and caused much structural change to the parenchyma. Hepatic cords were disorganized, separated by wide clefts, and composed of hepatocytes of varying size. Some cysts were necrotic and infiltrated by leukocytes and macrophages.

Spleen—Almost all the splenic lesions examined were from cod, and 68% were caused by microsporidans (presumably *Loma morhua*). Microsporidan cysts in the splenic capsule were bordered by an inner, dense, laminar, fibrous capsule and an outer, loose, fibrous layer infiltrated by mononuclear leukocytes. When multiple cysts were present, the splenic capsule was hyperplastic and also infiltrated by leukocytes. The splenic parenchyma appeared laden with melanin, especially immediately adjacent to small blood vessels; however, melanin-macrophage centers were not numerous. Larger blood vessels contained disproportionate numbers of leukocytes for the number of red blood cells present. Parenchymal cysts varied in their appearance. Small cysts were frequently bordered by splenic

cells that had pycnotic and karyorrhectic nuclei. Splenic parenchymal cells adjacent to some small cysts were lysed, leaving a clear area around the parasitic mass. In other cysts, a leukocyte infiltrate was present adjacent to the residual necrotic area proximal to the cyst wall. Mature granulomata with distinct fibrous and epithelioid cell types were also present.

Muscle—The most frequently observed muscle lesion was chronic inflammation (55%). Affected fishes included cod, haddock, pollack, redfish (*Sebastes marinus*), and white hake. No two lesions were exactly the same in appearance; however, all shared some common attributes. Some of the lesions were comprised of distinct granulomata, others were more diffuse and indistinct. Affected muscle was atrophic and necrotic. When granulomata were present, they consisted of epithelioid cells and fibroblasts. A central necrotic area contained amorphous, eosinophilic cellular debris and proteinaceous material. Adjacent muscle was infiltrated by leukocytes and had focal and diffuse areas of hemorrhage. Parasites were never seen; however, the redfish lesions contained chitin fragments, suggesting copepod parasitism. One lesion (haddock) also contained abundant, small, rod-shaped bacteria. Microsporidan-induced lesions were found in American plaice and ocean pout. The plaice lesion consisted of a small cyst filled with microsporidan pansporoblasts. The perimeter of the cyst had a thin, irregular, fibrous layer infiltrated by dense accumulations of mononuclear leukocytes. Leukocytes were also present in the interior of the cyst. Adjacent muscle appeared normal. The ocean pout lesion consisted of innumerable cysts containing microsporidan pansporoblasts and spores. Individual cysts were bordered by a dense, laminar, fibrous capsule and epithelioid cells. Fibrous tissue was present around some cysts and was the connecting matrix which joined all cysts. In some areas the connective tissue lattice contained plasmodial stages of the parasite. No muscle tissue was present in the parasitic mass. At the perimeter, however, necrotic muscle was infiltrated by leukocytes. Resting spores of *Ichthyophonus* were seen in a lesion involving dermis and muscle in a cusk (*Brosme brosme*) (Fig. 8). The epithelium

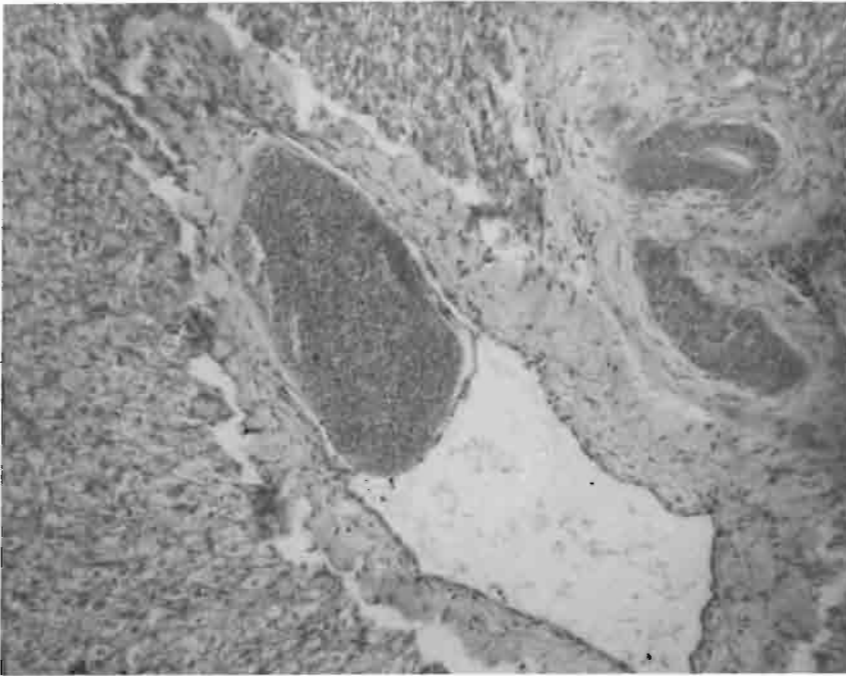


Figure 7.—Microsporidan cyst (*Loma morhua*) in lumen of hepatic vein of cod (H&E, × 200).

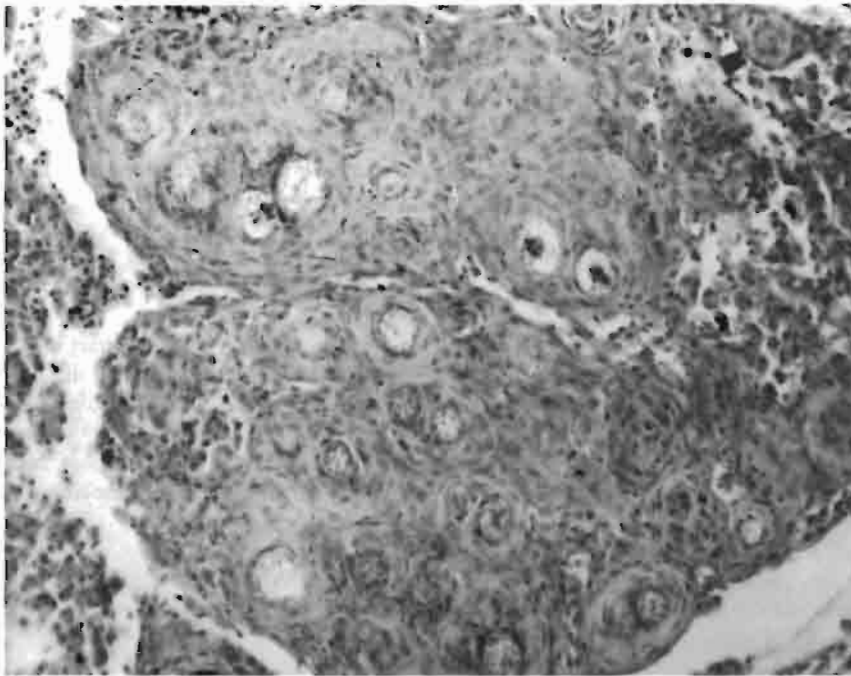


Figure 8.—Granulomatous inflammation around *Ichthyophonus* spores in dermis of cusk (H&E, × 200).

over the affected area was hyperplastic and spongiotic. Melanophores normally present beneath the basal lamina in the dermis were absent. The stratum spongiosum was necrotic and contained abundant mononuclear and polymorphonuclear leukocytes, pigment-laden macrophages, and fibroblasts. Blood vessels were congested and there were areas of hemorrhage. Resting spores were located in an area of granulomatous inflammation at the junction of the hypodermis and muscle. Muscle fibers were atrophic, necrotic, and infiltrated by leukocytes and fibroblasts. Congested blood vessels and hemorrhage were also present. Two neoplasms were found in muscle—one in a haddock and one in a silver hake (Fig. 9). Although both lesions were conservatively identified as fibromas, their aggressive lateral

expansion suggested that they could be fibrosarcomas. Constituent cells had indistinct cell membranes and were organized in whorls, palisades, and random arrays, often interfacing abruptly. Vesicular nuclei had one nucleolus and differed substantially in size. Mitotic activity was not detectable.

Miscellaneous—Grossly visible lesions were noted in nerve (goosefish), mesenteric (silver hake, yellowtail flounder), and swim bladder (haddock) tissues. Microscopic examination of the swim bladder tissues disclosed no obvious lesions. The nerve tissues from the goosefish contained numerous microsporidan cysts; host response was minimal and consisted of fibroplasia in the area adjacent to the

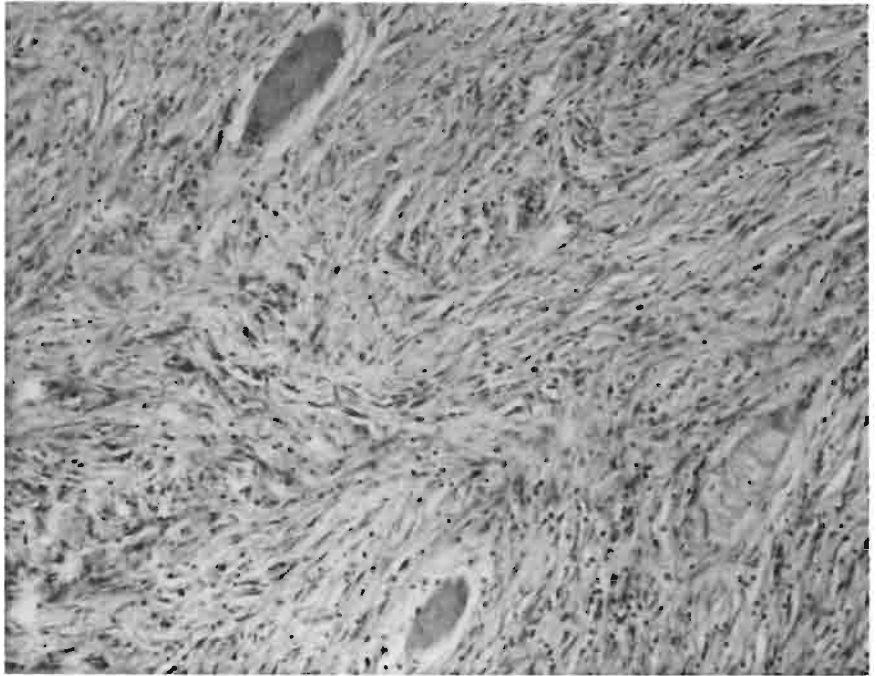


Figure 9.—Fibroma in silver hake dermis. Tumor has infiltrated muscle (H&E, × 200).

cysts. The mesenteric nodules contained larval cestodes and nematodes and evoked essentially no host response. Tables 3 and 4 present the frequency of occurrence of unicellular and metazoan parasites and nonspecific histologic lesions observed in tissues from western North Atlantic fishes.

Lesions of Eastern North Atlantic Fishes

Integument—Integumental lesions were most numerous and accounted for 24% of the abnormalities noted; they occurred in cod (*Micromesistius poutassou*) (1), dab (10), and flounder (*Platichthys flesus*) (6). All the flounder lesions consisted of lymphocystis. The dab lesions were heterogeneous and consisted of epidermal papilloma (2), “X” cell-induced inflammation (2), and one each of chronic inflammation, epidermal hyperplasia, hypermelanization, larval trematodes, lymphocystis, and ulceration. The “X” cell lesions (Fig. 10) differed somewhat from those in U.S. west coast flatfishes. The most conspicuous aspect of these lesions was the extensive infiltrate of mononuclear leukocytes around clusters and cords of “X” cells. The “X” cells themselves appeared to be similar to those seen in other fishes with comparable tumors (cod, goby, ocean pout, and several flatfish species). The dab lesions extended into adjacent muscle fascia resulting in considerable myolysis. Necrotic fibers were abundant and interfibrillar spaces were infiltrated by mononuclear leukocytes and macrophages. The lesions appeared to be well vascularized; many vessels were congested and many areas contained hemorrhage. The epidermal papillomas were typical in appearance and consisted of a hyperplastic, folded epidermis supported by a fibrous stroma (Fig. 11). The epidermis was spongiotic in some areas and infiltrated by eosinophilic granule cells (EGC). The EGC ranged from the basal lamina to the mucous cell layer. Some mononuclear leukocytes were also present. The fish exhibiting “hypermelanization” grossly exhibited a dark, green/black coloration. Microscopically, there were focal aggregates of melanin in the dermis just

below the basal lamina. In some areas, mononuclear leukocytes were dispersed around the melanin; this was particularly evident in scale pockets.

Gill—Gill lesions excised from fishes from the eastern North Atlantic were most numerous in blue whiting (*Gadus poutassou*). Two of the six lesions noted consisted of the oocyte-like cell seen in gadid fishes from the western North Atlantic; the remaining four nodular gill lesions were not visible subsequent to sectioning.

Gastrointestinal tract—One of the two gastrointestinal tract lesions was microsporidan-induced (dab, *Limanda limanda*) and the other a consequence of a coinfection of acid-fast bacteria and coccidia (mackerel, *Scomber scombrus*). In the latter lesion, multiple granulomata were present in mesenteric tissue of the pyloric caeca. Most of the granulomata were centrally necrotic; however, some contained presumptive mycobacteria and coccidian oocysts.

Heart—Six of the eight heart lesions were from mackerel. In all instances, these lesions were characterized grossly as cysts. Two of the six contained inflammatory foci (endocarditis, epicarditis) but no visible cysts. Another contained focal aggregates of small microsporidans located between cardiac muscle fibers; there was no host response. One heart contained multiple granulomata in which there were resting and germinating spores of *Ichthyophonus*. No microscopic lesions could be found in the two remaining mackerel heart tissues.

Kidney—Seven lesions were noted in kidney tissues—four in cod and three in mackerel; all consisted of granulomatous inflammation. No organisms were visible in the cod kidneys. Granulomata in one of the mackerel kidneys contained acid-fast bacteria and coccidian oocysts (presumably *Mycobacterium* and *Eimeria*, respectively); in another kidney they contained resting and germinating spores of *Ichthyophonus*. No organisms were visible in the granulomata of the third kidney lesion.

Table 3.—Frequency of occurrence of unicellular and metazoan parasites observed in tissues of fishes from the western North Atlantic.

Parasite	No. parasites (N=151)									
	Gill	Gonad	Gut	Heart	Integument	Liver	Muscle	Spleen	Misc.	
Microbial, Protozoan										
<i>Lymphocystis</i>					15					
<i>Ichthyophonus</i>							1			
<i>Trichodina</i>	1									
<i>Oodinium</i>	1									
<i>Glugea</i>			10			2				
<i>Lona</i>	16			13		1		21		
<i>Nosema</i>										Nerve 2
<i>Pleistophora</i>							3			
<i>Unicapsula</i>			1			1		1		
Metazoan										
Cestodes		1	25			7				
Nematodes		1	4			6				
Trematodes	2		1		15					
Unidentified										
"X" cell					2					
OLC	41									

Table 4.—Frequency of occurrence of histologic lesions not associated with microscopically visible parasites observed in tissues of fishes from the western North Atlantic.

Type of lesion	No. lesions (N=76)							
	Gill	Gonad	Gut	Heart	Integument	Liver	Muscle	Spleen
Hyperplastic								
Biliary						1		
Epidermal	3				2			
Papilloma					1			
Inflammatory								
Chronic	4		7		2		11	
Necrotic								
Focal						3		
Ulceration	7				33			
Neoplastic								
Fibroma							2	

Liver—Liver lesions were noted in 15 fishes—blue whiting, cod, mackerel, and whiting (*Merluccius merluccius*). All five lesions in whiting were recognized grossly as cysts and contained larval nematodes when examined microscopically. Lesions described as nodules in cod (4) and mackerel (4) consisted of granulomatous inflammatory tissue. No organisms were visible in any of the four cod liver tissues. In one of the four mackerel livers, granulomata contained both acid-fast bacteria and coccidia. Another mackerel liver contained numerous microsporidian cysts. The cysts had a PAS-positive wall and were bordered by concentric layers of fibrous tissue which had been infiltrated by mononuclear leukocytes. Focal hemorrhage also was present in some areas.

Spleen—Fifteen splenic lesions were noted—seven in cod and eight in mackerel; all were typified by chronic inflammation in either capsule or parenchyma. Granulomata in one cod lesion contained acid-fast bacteria. Splenic granulomata in mackerel contained acid-fast bacteria (1) and spores of *Ichthyophonus* (3); granulomata were present in four spleen tissues but without any discernible infectious agent.

Muscle—Only four muscle lesions were noted grossly—two in cod and one each in dab and flounder. The cod lesion extended from the dermis to the muscle and appeared to be a lipoma. Constituent cells were well differentiated and arranged randomly and in whorls. The lesion was well vascularized and poorly defined at its perimeter. Fat cells infiltrated the interfibrillar spaces of adjacent muscle and the fibers were atrophic and necrotic. The dab lesion consisted of a piece of inflammatory tissue with a large central area of necrosis. Branched, septate, fungal hyphae were present in the necrotic area and distributed around its perimeter. The remaining muscle lesion was either a fibroma or fibrosarcoma in flounder. Although some cells were arranged in cords or palisades, the overall cell pattern was random. Nuclei varied considerably in size and contained one nucleolus. Few mitotic figures were noted. The tumor contained many necrotic and hemorrhagic areas and focal aggregates of melanin and ceroid.

Miscellaneous—Eight goosfish (*Lophius piscatorius*) had microsporidan-induced cysts in the central nervous system, and one whiting had an apparent epitheliocystis lesion in gill epithelium (Fig. 12).

DISCUSSION

In many instances, the sampling protocol biased the results in favor of lesions characterized by proliferative host responses. Typically, proliferative lesions are seen in fishes with chronic infectious diseases such as those caused by some bacteria, fungi, and some protozoans and metazoans (Table 3). Although they are compromising in some way, these diseases usually are not imminently fatal; the fish is probably able to survive and reproduce, albeit at a lower level of metabolic efficiency. Fishes with acute infectious diseases are unlikely to have grossly visible lesions and rarely are sampled in trawl surveys.

Although the basis for sampling was the presence of grossly visible lesions in the organs examined, in many instances microscopic examination of sectioned tissues failed to disclose the presence of a

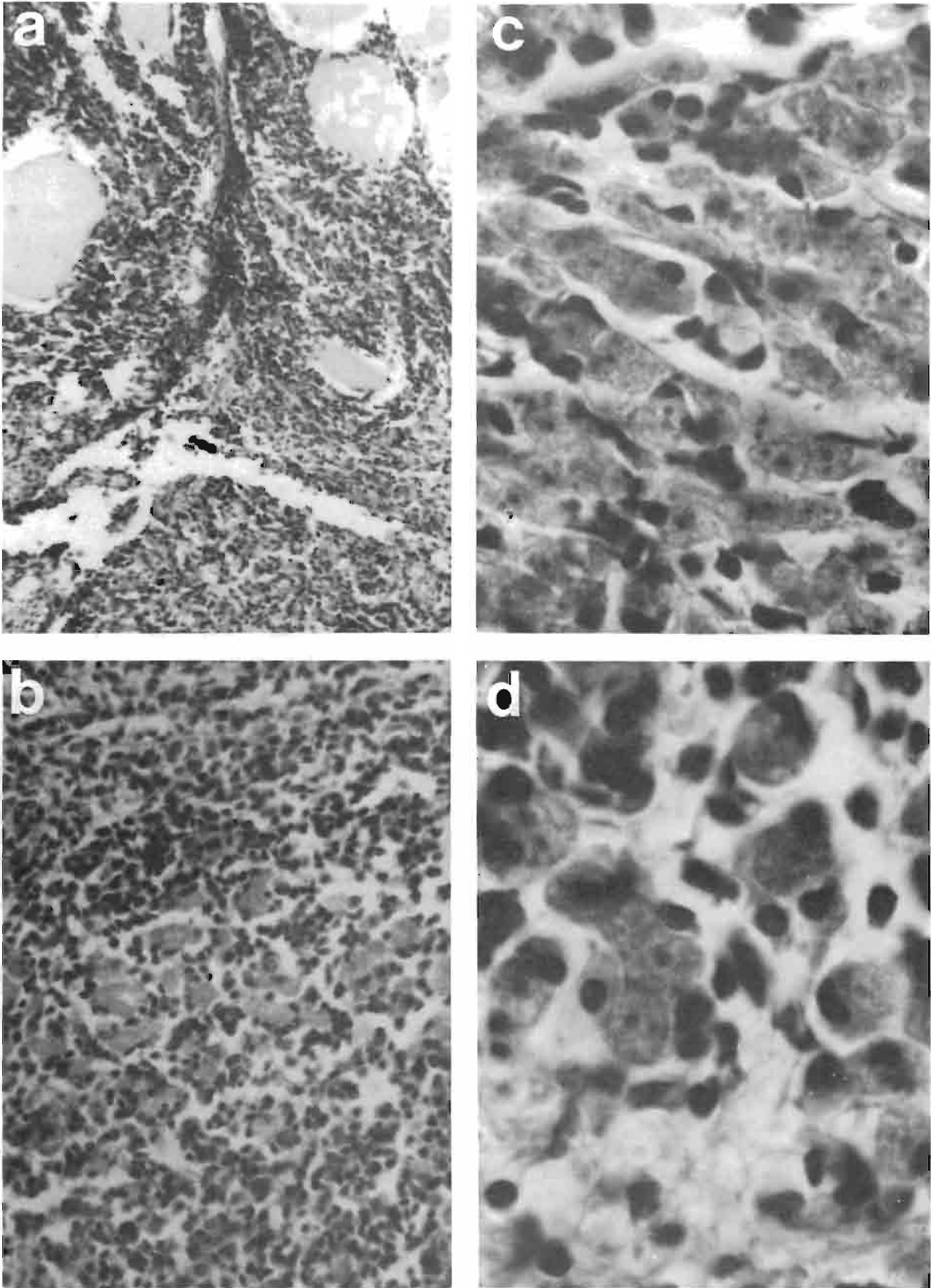


Figure 10.—“X” cell lesion in dermis of dab. a) Lateral edge of lesion infiltrating muscle (H&E, $\times 100$); b) Mononuclear leukocytes and several “X” cells (H&E, $\times 200$); c) Cords of “X” cells, several possibly binucleate (H&E, $\times 400$); d) Typical “X” cells with foamy cytoplasm and nuclei with prominent nucleoli (H&E, $\times 1000$).

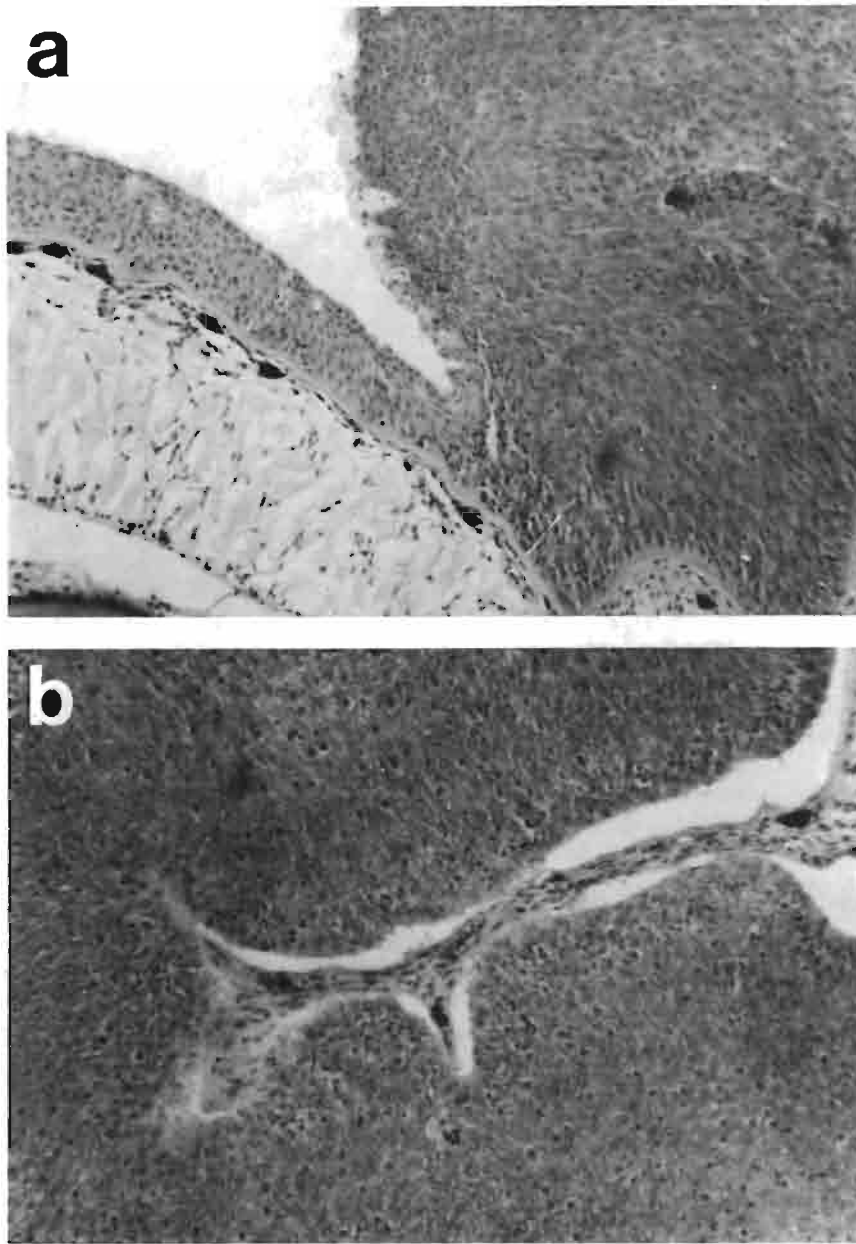


Figure 11.—Epidermal papilloma of dab. a) Lateral edge of lesion showing contrast between height of normal epidermis and hyperplastic epidermis (X 100); b) Hyperplastic epidermis supported by fibrous stroma (H&E, × 100).

lesion. Of the 350 lesions excised from tissues of western North Atlantic fishes and 66 excised from tissues of eastern North Atlantic fishes, 81 (23%) and 16 (24%), respectively, were not visible in histologic sections. This most probably was because many were small (2-5 mm) and solitary, and, therefore, less likely to be present after embedding and sectioning than lesions which are larger and more dispersed in the tissue sectioned. Microscopically nonverifiable lesions were present in integument (11%), gill (26%), gastrointestinal tract (22%), heart (33%), kidney (14%), liver (35%), spleen (23%), and muscle (17%).

Since biologists rarely had the time to conduct comprehensive necropsies, the first and most obvious lesion was usually the only one excised. Cod and mackerel, however, caused exceptions to this practice. Since several organs were obviously abnormal in some fish (invariably nodules in gill, kidney, liver, mesentery, or spleen), more than one lesion was excised. One cod infected with *Unicapsula* (Fig.

13) had granulomata in liver, mesentery, and spleen; several cod had granulomata in kidney, liver, and spleen (cause unknown); and many cod infected with *Loma morhua* had granulomata in gill, heart, and spleen. A mackerel with mycobacteriosis had granulomata in kidney, liver, and mesentery (also coccidia in liver granulomata), and one infected with *Ichthyophonus* had granulomata in heart and spleen. *Ichthyophonus* and mycobacteriosis both are proliferative, systemic diseases. When the disease is chronic, granulomata may be found in many organs.

Although the findings of this survey are not quantitatively significant, they provide an insight to the identity and microscopic aspects of lesions found in a variety of commercially important bottom fishes. In the western North Atlantic, American plaice were found with lymphocystis (one fish had a microsporidan-induced myositis); cod had systemic microsporidiosis and ulcers (one fish had systemic myxosporidiosis); a cusk had *Ichthyophonus*; haddock

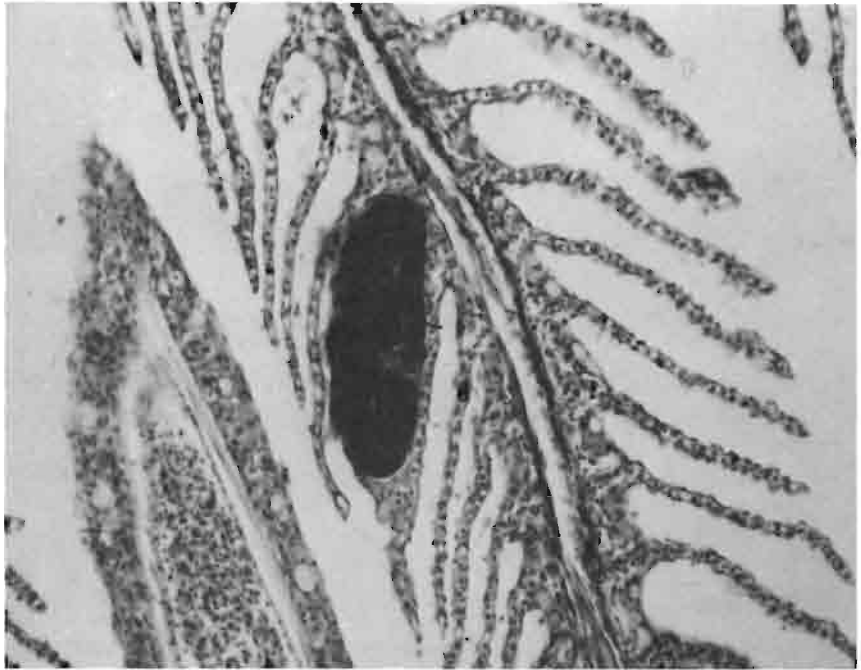

Figure 12.—Epitheliocystis lesion in gill of whiting (H&E, $\times 200$).

had microsporidan-induced gill infections and also were infected with an unidentified oocyte-like cell (OLC) (one fish had a muscle fibrosarcoma); several ocean pout had dermal "X" cell infections; many red hake had OLC gill lesions and several had ulcers; many silver and white hake had OLC gill lesions; and many winter flounder had lymphocystis and microsporidan-induced gastrointestinal cysts. In the eastern North Atlantic, blue whiting had OLC gill lesions; one cod had mycobacteriosis and several had lesions compatible with mycobacteriosis (one fish had a dermal lipoma); dab had a variety of integumental lesions including lymphocystis, epidermal papilloma, "X" cell infections and ulcers; flounder had lymphocystis (one fish had a muscle fibrosarcoma); mackerel had *Ichthyophonus* and mycobacteriosis; and one whiting had gill epitheliocystis.

In the western North Atlantic, specifically the U.S. Continental Shelf between Cape Hatteras and Nova Scotia, surveys have been conducted since 1979 to determine the prevalence and spatial distribution of integumental lesions and skeletal/pigmentation anomalies (Murchelano and Azarovitz 1979; Despres-Patanjo and Murchelano 1981; Despres-Patanjo et al. 1982). The results of these surveys have disclosed low prevalences of integumental lesions such as fin erosion, lymphocystis, and ulcers. Lymphocystis and fin erosion were noted principally in winter flounder; ulcers primarily affected cod and red hake (Murchelano and Ziskowski 1979). Recent intensive trawl surveys in the eastern North Atlantic, particularly the Danish coast, French coast, and German Bight, have revealed high prevalences of integumental lesions in bottom fishes, especially flatfishes (Christensen 1980; Nounou et al. 1981; Dethlefsen and Watermann 1982). Dab from the German Bight were noted with epidermal papilloma (Watermann 1982), lymphocystis, and ulcers; dab from the French coast were ulcerated but did not have lymphocystis and epidermal papilloma. Cod with ulcers have been obtained from Danish, French, and German coastal waters. There are considerable differences in the prevalences of integumental lesions between western and eastern North Atlantic bottom fishes, whatever their cause(s). Although pollution has been implicated in the high prevalences

of these lesions in eastern North Atlantic bottom fishes, conclusive cause and effect relationships must yet be established.

To date, inadequate data have been collected to compare the prevalence and cause of visceral lesions of commercially valuable bottom fishes from the eastern and western North Atlantic. Surveys in the eastern North Atlantic have revealed that many cod, haddock, mackerel, and plaice (*Pleuronectes platessa*) have granulomatous visceral lesions. Granulomata in viscera of cod from the Dutch coast and mackerel from southern England and northern Ireland contained acid-fast bacteria which were presumed to be *Mycobacterium* (van Banning, pers. commun.¹). Kidney tissues from haddock and plaice from Scottish waters were found to be infected with spores of *Ichthyophonus* (McVicar 1980). Mackerel from the western English Channel and northern North Sea were noted with nodular lesions predominantly of kidney and spleen (Hastings et al. 1982). Acid-fast rod-shaped bacteria were seen in kidney melanin-macrophage centers and within centrally necrotic granulomata. Although the organisms were not cultured for specific identification, they were presumed to be mycobacteria.

Although the published literature is replete with case reports on the presence of specific parasites and lesions in western North Atlantic fishes, comprehensive seasonal surveys of fish health are recent initiatives. As noted herein, few fishes have lesions comparable in cause or severity to those found either in the integument or viscera of eastern North Atlantic fishes. Mycobacteriosis has not been detected in either cod or mackerel. Although few mackerel were examined histologically in this survey, nodular lesions of kidney, liver, and spleen have not been noted incidentally in studies of a hematozoan mackerel parasite (MacLean, pers. commun.²). A major deficiency of the present survey was the inability to routinely examine kidney tissues. Procedurally, kidney examination required more skill and time than could be allocated by biologists on stock

¹Paul van Banning, Netherlands Institute for Fishery Investigations, IJuiden, Holland, pers. commun. October 1981.

²Sharon MacLean, Natl. Mar. Fish. Serv., NOAA, Northeast Fish. Cent., Oxford, MD 21654, pers. commun. June 1982.

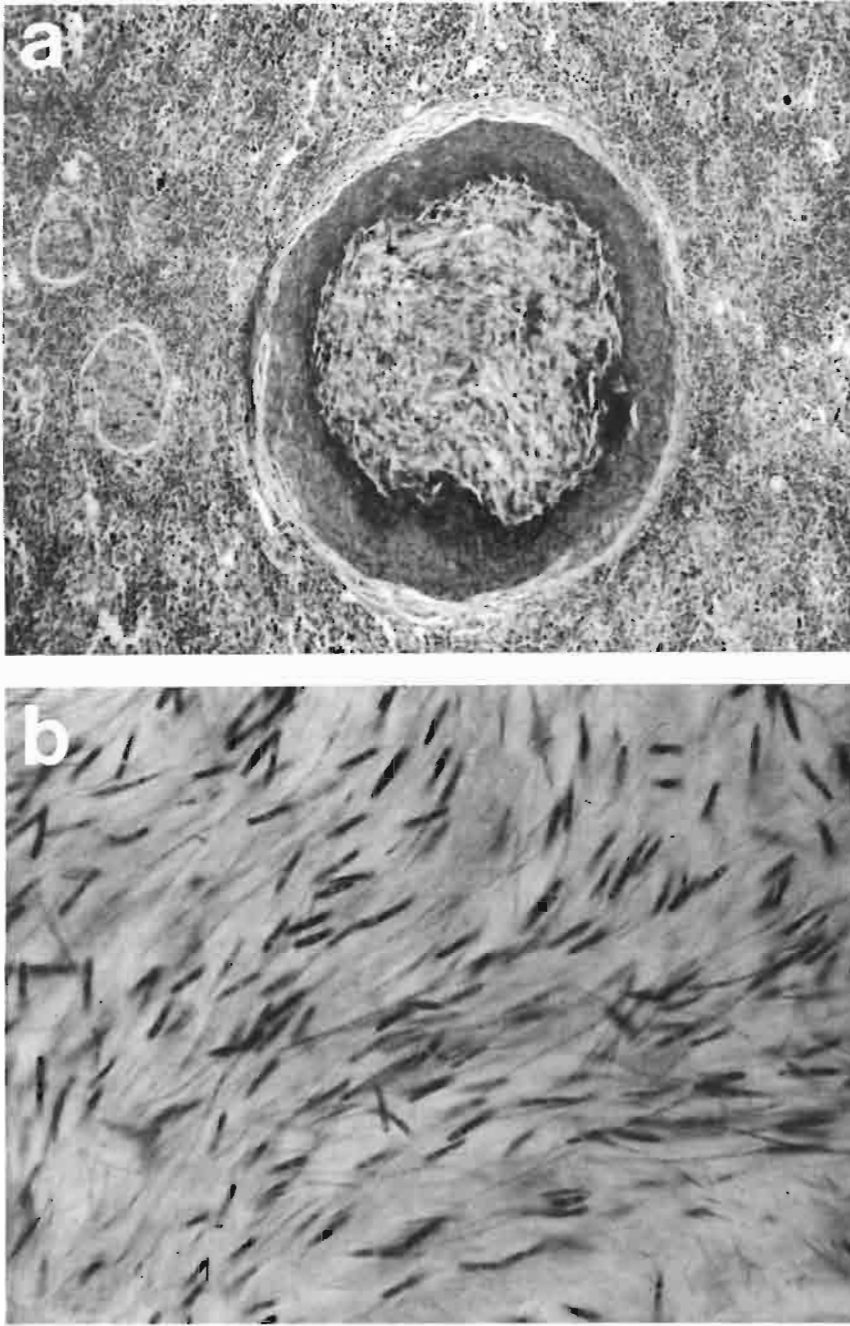


Figure 13.—*Unicapsula* in cod. a) Granuloma in spleen (H&E, $\times 200$). b) *Unicapsula* sp. (ZN, $\times 1000$).

assessment cruises. Although epizootics of *Ichthyophonus* in herring from the western North Atlantic have occurred in the past (Sindermann and Scattergood 1954), no herring were sampled on any of the stock assessment cruises conducted. As part of a mackerel sportfishing creel census conducted in New Jersey coastal waters in 1979, grossly normal kidney tissues were excised at random from 91 fish and fixed for microscopic examination (Murchelano, unpubl.). Although the amount of kidney tissue present on each slide varied appreciably, the number of granulomata present was tallied. Thirty-six of 91 (39%) fishes had from 1 to 3 granulomata per slide, and 2 of 36 (5%) fishes had granulomata containing resting or germinating spores of *Ichthyophonus*. This observation indicates that infections may be present, yet not apparent at gross examination.

Attempts will be made to substantiate these preliminary findings on future cruises.

The only other recent, broadly based studies of marine fish health have been conducted in Alaskan Outer Continental Shelf waters (Bering Sea, North Pacific) by Wellings et al. (1977) and McCain et al. (1979). Twenty-six species of fish were examined, but only four species had grossly visible external lesions. Pacific cod (*Gadus macrocephalus*) and walleye pollack (*Theragra chalcogramma*) had "X" cell pseudobranch tumors; Pacific cod had integumental ulcers; rock sole (*Lepidopsetta bilineata*) had "X" cell epidermal papillomas; and yellowfin sole (*Limanda aspera*) had lymphocystis. Although the authors reported that they necropsied fish as time permitted, no internal lesions were described.

The limitations to the study of diseases of wild marine fishes, especially in ocean environments, are well known. Sampling is difficult, expensive, and never adequate since the populations are large, dispersed, and migratory. Additionally, unless a major epizootic is in progress, fish with acute diseases (and lesions) are unlikely to be found. Despite these limitations, studies of marine fish diseases should be encouraged. The information obtained will eventually enhance the success of marine fish husbandry (mariculture) and may substantiate that some fish diseases are a consequence of environmental degradation and a cause of population decline.

ACKNOWLEDGMENTS

Many individuals made the acquisition of fish tissues possible. In the western North Atlantic, tissues were obtained by biologists of the Resource Assessment Division, Northeast Fisheries Center (Bradford Brown, Chief). In the eastern North Atlantic, the authors directly obtained all tissues. However, the gracious hospitality of FFS *Anton Dohrn* (Germany), NO *Thalassa* (France), and BO *Cornide de Saavedra* (Spain) was made possible by Volkert Dethlefsen, Bundesforschungsanstalt für Fischerei, Cuxhaven, Claude Maurin, Institut Scientifique et Technique des Pêches Maritimes, Nantes, and Raphael Robles, Instituto Espanol de Oceanografia, Vigo, respectively.

LITERATURE CITED

- CHRISTENSEN, N. O.
1980. Diseases and anomalies in fish and invertebrates in Danish littoral regions which might be connected with pollution. Rapp. P.-v. Réun. Comm. int. Explor. Sci. Mer Mediterr. Monaco 1979:103-109.
- DAWE, C. J.
1981. Polyoma tumors in mice and X-cell tumors in fish viewed through telescope and microscope. In C. J. Dawe, J. C. Harshbarger, S. Kondo, T. Sugimura, and S. Takayama (editors), Phyletic approaches to cancer, p. 19-49. Japan Sci. Soc. Press, Tokyo.
- DAWE, C. J., J. BAGSHAW, and C. M. POORE.
1979. Amebic pseudotumors in pseudobranchs of Pacific cod, *Gadus macrocephalus*. Proc. Am. Assoc. Cancer Res. 20:245.
- DESPRES-PATANJO, L., and R. A. MURCHELANO.
1981. Results of an initial survey to evaluate fish health in the western North Atlantic. Int. Counc. Explor. Sea C.M.1981/E:39, 13 p.
- DESPRES-PATANJO, L., J. ZISKOWSKI, and R. A. MURCHELANO.
1982. Distribution of fish diseases monitored on stock assessment cruises in the western North Atlantic. Int. Counc. Explor. Sea C.M.1982/E:30, 12 p.
- DETHLEFSEN, V., and B. WATERMANN.
1982. Diseases of major fish species in western Baltic Sea. Int. Counc. Explor. Sea C.M.1982/E:19, 20 p.
- HASTINGS, T. S., K. MacKENZIE, and A. E. ELLIS.
1982. Presumptive mycobacteriosis in mackerel (*Scomber scombrus* L.). Bull. Eur. Assoc. Fish Path. 2:19-21.
- LANGE, E.
1973. Carcinoid-like tumors in the pseudobranch of *Gadus morhua*. Comp. Biochem. Physiol. 45:477-481.
- McCAIN, B. B., W. D. GRONLUND, M. S. MYERS, and S. R. WELLINGS.
1979. Tumours and microbial diseases of marine fishes in Alaskan water. J. Fish Dis. 2:111-130.
- McVICAR, A. H.
1980. The effects of *Ichthyophonus* infection in haddock *Melanogrammus aeglefinus* and plaice *Pleuronectes platessa* in Scottish waters. Int. Counc. Explor. Sea, Pap. 16.
- MORRISON, C. M., and V. SPRAGUE.
1981. Electron microscopical study of a new genus and new species of microsporidia in the gills of Atlantic cod *Gadus morhua* L. J. Fish Dis. 4:15-32.
- MURCHELANO, R. A.
1982. Some pollution-associated diseases and abnormalities of marine fishes and shellfishes: A perspective for the New York Bight. In G. F. Mayer (editor), Ecological stress and the New York Bight: Science and Management, p. 327-346. Estuar. Res. Fed., Columbia, S.C.
- MURCHELANO, R. A., and T. AZAROVITZ.
1979. Fish disease surveys in the western North Atlantic. Int. Counc. Explor. Sea C.M.1979/E:24, 7 p.
- MURCHELANO, R. A., and J. ZISKOWSKI.
1979. Some observations on an ulcer disease of red hake, *Urophycis chuss*, from the New York Bight. Int. Counc. Explor. Sea C.M.1979/E:23, 5 p.
- NOUNOU, P., R. MARTOJA, and L. ORCEL.
1981. Ulcerations of marine fishes and mammals caught in the French coastal waters. Cent. Natl. Exploit. Oceans, Sci. Tech. Rep. 43, 99 p.
- SINDERMANN, C. J.
1979. Pollution-associated diseases and abnormalities of fish and shellfish: A review. Fish. Bull., U.S. 76:717-749.
- SINDERMANN, C. J., and L. W. SCATTERGOOD.
1954. Diseases of fishes of western North Atlantic. II. *Ichthyosporidium* disease of the sea herring (*Clupea harengus*). Maine Dep. Sea Shore Fish., Res. Bull. 19:1-40.
- SINDERMANN, C. J., F. B. BANG, N. O. CHRISTENSEN, V. DETHLEFSEN, J. C. HARSHBARGER, J. R. MITCHELL, and M. F. MULCAHY.
1980. The role and value of pathobiology in pollution effects monitoring programs. Rapp. P.-v. Réun. Comm. int. Explor. Sci. Mediterr. Monaco 179:135-151.
- WATERMANN, B.
1982. An unidentified cell type associated with an inflammatory condition of the subcutaneous connective tissue in dab, *Limanda limanda* L. J. Fish Dis. 5:257-262.
- WELLINGS, S. R.
1969. Neoplasia and primitive vertebrate phylogeny: Echinoderms, prevertebrates and fish—a review. Natl. Cancer Inst. Monogr. 31:59-128.
- WELLINGS, S. R., C. E. ALPERS, B. B. McCAIN, and M. S. MYERS.
1977. Fish disease in the Bering Sea. Ann. N.Y. Acad. Sci. 298:290-304.