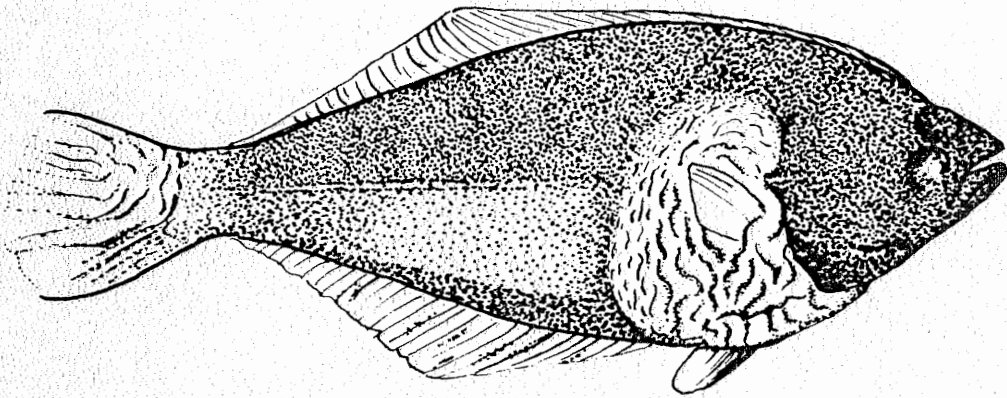

A GUIDE FOR THE RECOGNITION OF SOME
DISEASE CONDITIONS AND ABNORMALITIES
IN MARINE FISH

MARCH 1978

A GUIDE FOR THE RECOGNITION OF SOME DISEASE CONDITIONS
AND ABNORMALITIES IN MARINE FISH

by

Carl J. Sindermann, John J. Ziskowski
and Valentine T. Anderson Jr.

Sandy Hook Laboratory
Northeast Fisheries Center
National Marine Fisheries Service
National Oceanic and Atmospheric Administration
U. S. Department of Commerce
Highlands, New Jersey 07732

Technical Series Report No. 14

March, 1978

CONTENTS

	<u>Page</u>
Introduction	1
Ulcers	4
Fin erosion	7
Tumors	12
Lymphocystis	17
Black spots	21
Parasitic copepods	25
Skeletal abnormalities	29
Reversal in flatfish	36
Abnormal pigmentation in flatfish	41
Key references	48

INTRODUCTION

Parasites and other disease conditions in marine fishes have been recognized and examined sporadically for many decades. The literature on marine fish parasites and diseases is therefore extensive and highly dispersed, although some attempts at summarization have been made.

Realization that world fish production from natural stocks has finite limits has resulted in expansion of interest in factors such as disease that may affect population size. Furthermore, there is great interest now in the possible effects of increasing coastal/estuarine pollution on fish stocks. Some of the disease conditions seen in fish catches may be associated with environmental degradation by various kinds of contaminants (summarized in Sindermann, 1977).

Many people -- biologists, sea-going technicians, inspectors, and processing industry employees -- physically handle great numbers of fish every day, and may observe some of the larger ectoparasites or gross disease conditions which occur, but rarely record these observations. Thus a large body of potentially valuable data slips away.

Some of the abnormalities and disease signs are readily apparent externally, and recording of observations of these conditions could provide much more comprehensive knowledge about distribution and prevalence of fin erosion, ulcers, tumors, skeletal anomalies, and several other gross abnormalities in fish.

This guide has been prepared and distributed so that trawl catches and other types of landings can be scrutinized for the existence and abundance of grossly-visible disease conditions. The availability of identification material may encourage the observation and recording of such conditions.

The following disease conditions and other abnormalities are included in this guide:

- (1) Ulcers
- (2) Fin erosion
- (3) Tumors
- (4) Lymphocystis
- (5) Black spots
- (6) Parasitic copepods
- (7) Skeletal anomalies
- (8) Reversal in flatfish
- (9) Abnormal pigmentation

Some representative photographs and drawings are included. Undoubtedly there will be additional disease conditions that will be recognized and that should be added to subsequent versions of this field guide. These additions should be brought to the attention of the authors as soon as possible. This document does not consider internal parasites or disease conditions, but they could logically be added to later revisions.

Although this guide includes only gross disease signs, some of the conditions described -- such as tumors and lymphocystis -- should be confirmed by microscopic examination. Diseased tissue should be preserved in formalin and sent to appropriate fish disease experts for a confirmed diagnosis. The authors will attempt to respond to inquiries about unusual observations and to provide sources of additional information. For those interested in the scientific literature on the disease conditions discussed in this document, relevant references are grouped by disease category at the end of this report.

I. ULCERS

Ulcerations or external sores on fish may have a number of causes. They may be due to net damage or other mechanical abrasions, to predator attacks, or to infections. Some protozoa (Myxosporida and Microsporida) can infect muscle or skin tissue and multiply to produce gross cysts. These infections mature to produce many characteristic microscopic spores, and in the process the overlying epidermis may be sloughed, producing ulcers with usually smooth borders (Figure 1).

However, many of the infections that produce grossly visible ulcerations are bacterial, and are often due to pathogens of the genera Vibrio, Pseudomonas or Aeromonas. Vibrio anguillarum has been identified as a cause of ulcerative lesions in winter flounder, Pseudopleuronectes americanus, and summer flounder, Paralichthys dentatus, from the western North Atlantic (Levin et al., 1972; Robohm and Brown, 1977). Ulceration often begins with scale loss or the formation of small papules, followed by sloughing of the skin, exposing the underlying muscles, which may also be destroyed. Bacterial ulcers may have rough or raised irregular margins, and will often be hemorrhagic (Figure 2).

Recently, ulcers, presumably of bacterial etiology, have been observed in several flatfish species, including European flounders, (Platichthys flesus), dab (Limanda limanda), plaice (Pleuronectes platessa), and winter flounder (Pseudopleuronectes americanus). Ulcers may also occur in a number of other fishes, pelagic or demersal. Ulcers may or may not be associated with fin erosion.

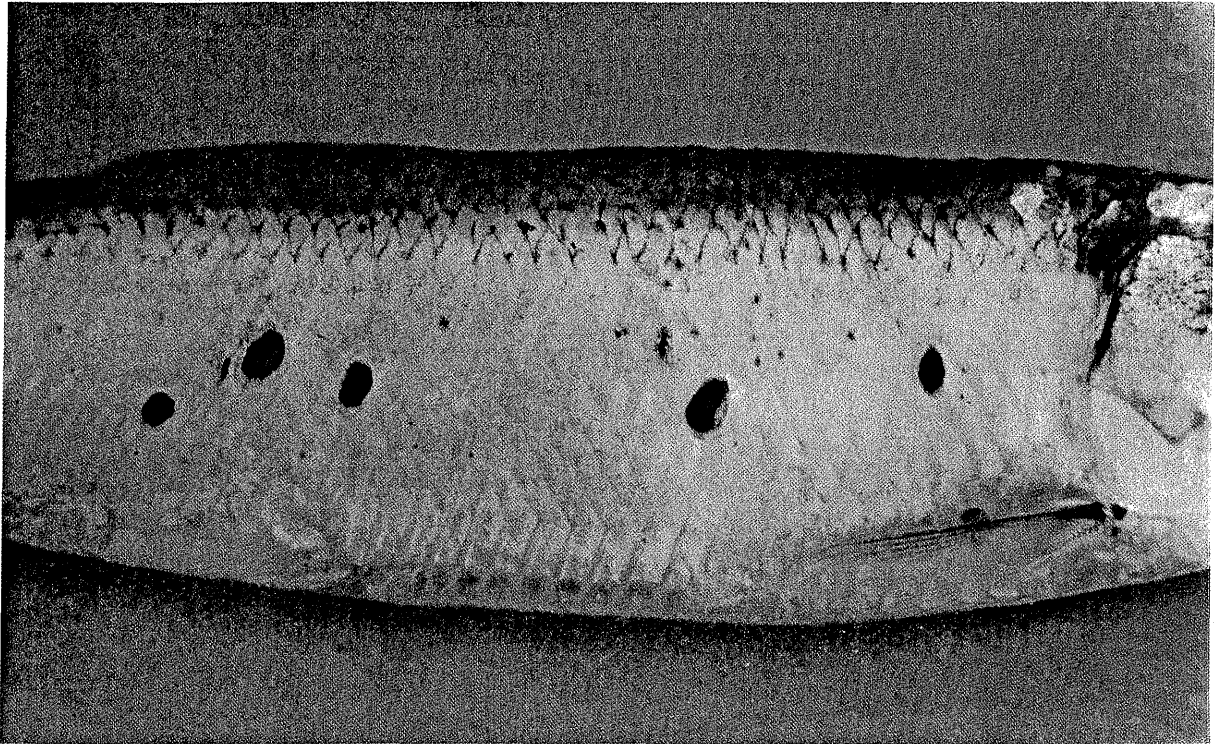


Figure 1. Ulcer with smooth margins in sea herring, Clupea harengus, resulting from infection by the Myxosporidan protozoan, Kudoa clupeiidae.





Figure 2. Hemorrhagic ulcers in bluefish (above) and mullet (below), probably a result of Vibrio infection.

II. FIN EROSION

Probably the best known but least understood disease of fish from polluted waters is a non-specific condition known as "fin rot" or "fin erosion" -- a syndrome which seems rather clearly associated with degraded estuarine or coastal environments. The disease has been reported from the western North Atlantic, the Gulf of Mexico, the eastern and western Pacific, and the Irish Sea. Twenty-two species of fish from the New York Bight were reported to be affected to some degree by fin erosion (Mahoney et al., 1973). In that same area prevalence of the disease at particular stations reached 35% of individuals in certain samples, but was usually much lower (Ziskowski and Murchelano, 1975).

The disease seems to exist in at least two forms: (a) "site specific" erosion (Figure 3), where the disease is localized in the mid-dorsal and anal fins; and (b) "generalized" erosion where broad areas of several fins are destroyed (Figures 4a and 4b). Tissues at the base of eroded areas may become opaque or blackened due to aggregation of pigment cells and formation of scar tissue, or they may on rare occasions be hemorrhagic. Fin rays may be collapsed and resorbed.

Fin erosion in flatfish may be initiated by direct contact of tissues with contaminated sediments. Toxic substances (sulfides, heavy metals, chlorinated hydrocarbons, etc.) could remove or modify the protective mucus coat and expose epithelial tissues to these and possible other chemicals. Fin erosion has been induced experimentally by

exposure of normal fish to contaminated sediments, and by exposure to petroleum hydrocarbons and PCB (Aroclor 1254) (Couch and Nimmo, 1974; Minchew and Yarbrough, 1977). It should be noted that contact with contaminated sediments is not necessary in all cases.

It seems quite likely that the causes of "fin erosion" in fish includes chemical stress; probably acting on mucus and epithelium; stress resulting from marginal dissolved oxygen concentrations, possibly enhanced by a sulfide-rich environment (in the case of demersal fish); and secondary bacterial invasion in at least some instances. Systemic bacterial infections do not seem to be associated consistently with fin erosion, although bacterial isolations from superficial fin tissues may often be made.

In the field, fin erosion is most frequently confused with mechanical or "net" damage (Figure 5). Net damaged fins, especially those damaged by trawl nets, are generally characterized by: (a) active hemorrhaging of fin tissue; (b) many red spots or "petechiae" on the body of the fish, indicating rough handling; (c) exposed fin rays and splitting of fin membranes; and (d) absence of melanized or darkened tissue at erosion sites. Other forms of rough handling of catches may also produce superficial abrasions that may be confused with fin erosion.




Figure 3. Site-specific fin erosion concentrated in the mid portion of fins in winter flounder, Pseudopleuronectes americanus (anterior dorsal fin is folded over in this picture). Note melanism in areas of erosion. (Photograph courtesy of Mr. J. O'Reilly, NMFS, Sandy Hook Laboratory).

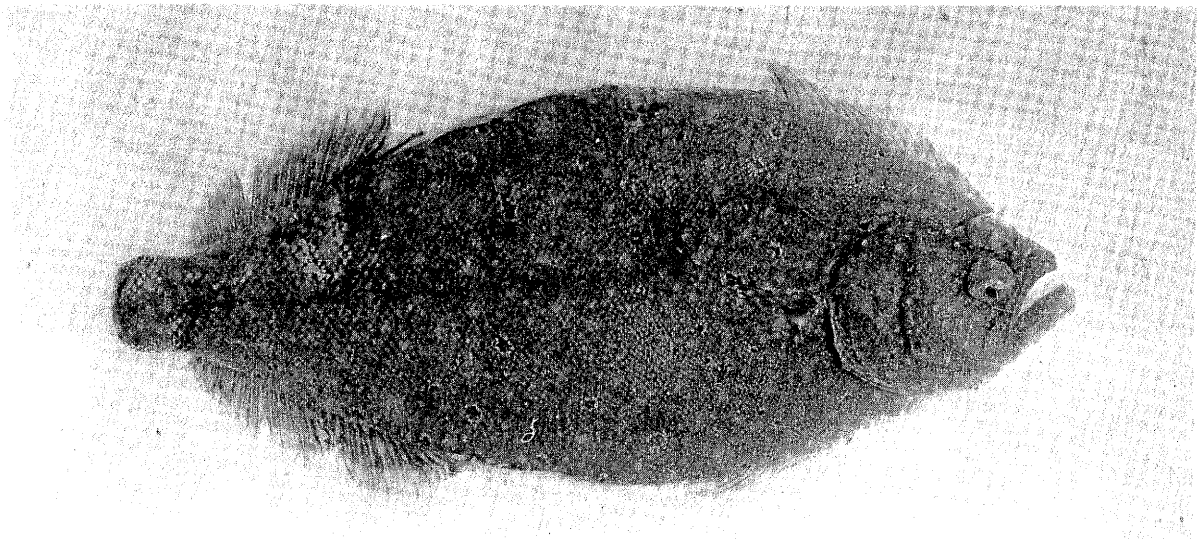



Figure 4. Generalized fin erosion in weakfish, Cynoscion regalis (above) and in four-spot flounder, Paralichthys oblongus (below). Note that in the weakfish the anal, caudal, and pelvic fins are eroded, while the dorsal fins are not usually damaged. In contrast the four-spot flounder shows erosion of wide areas of fin fringes.

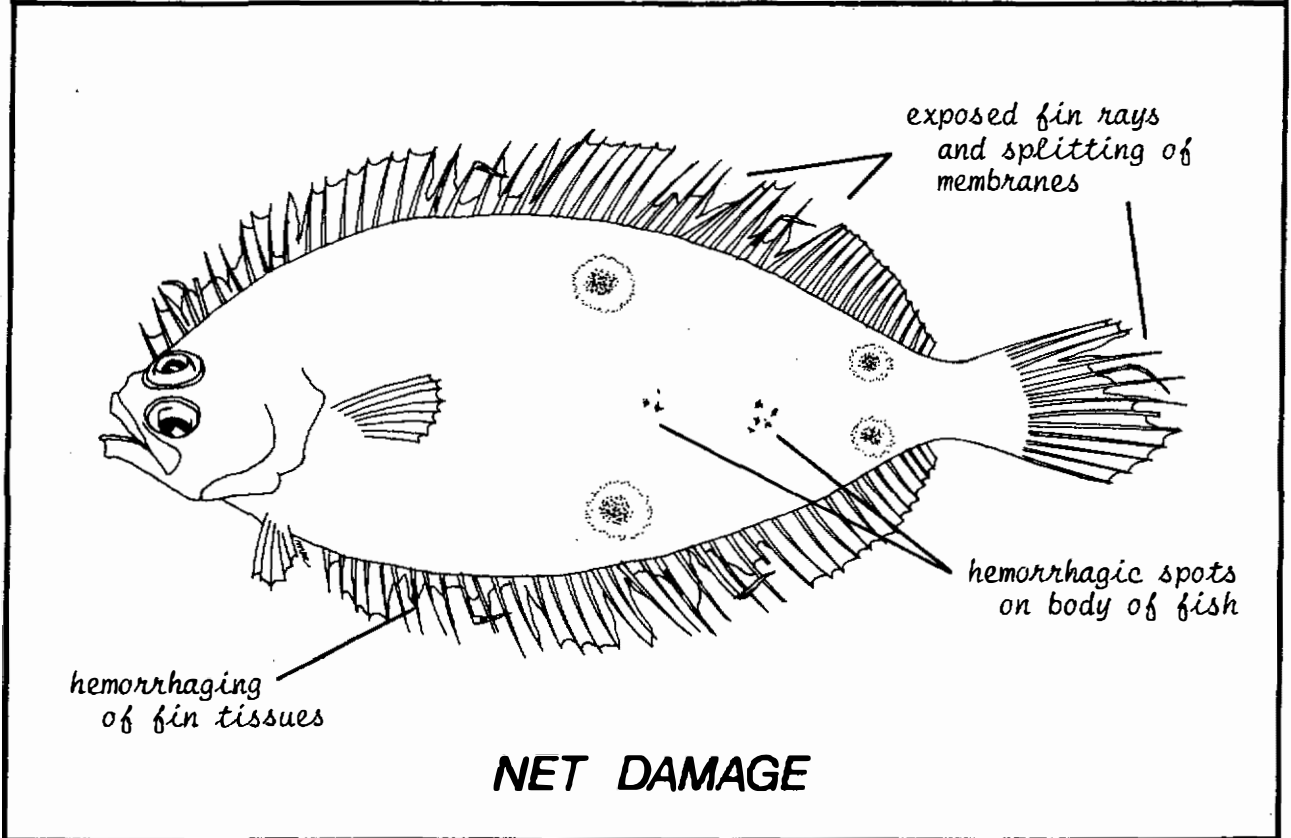
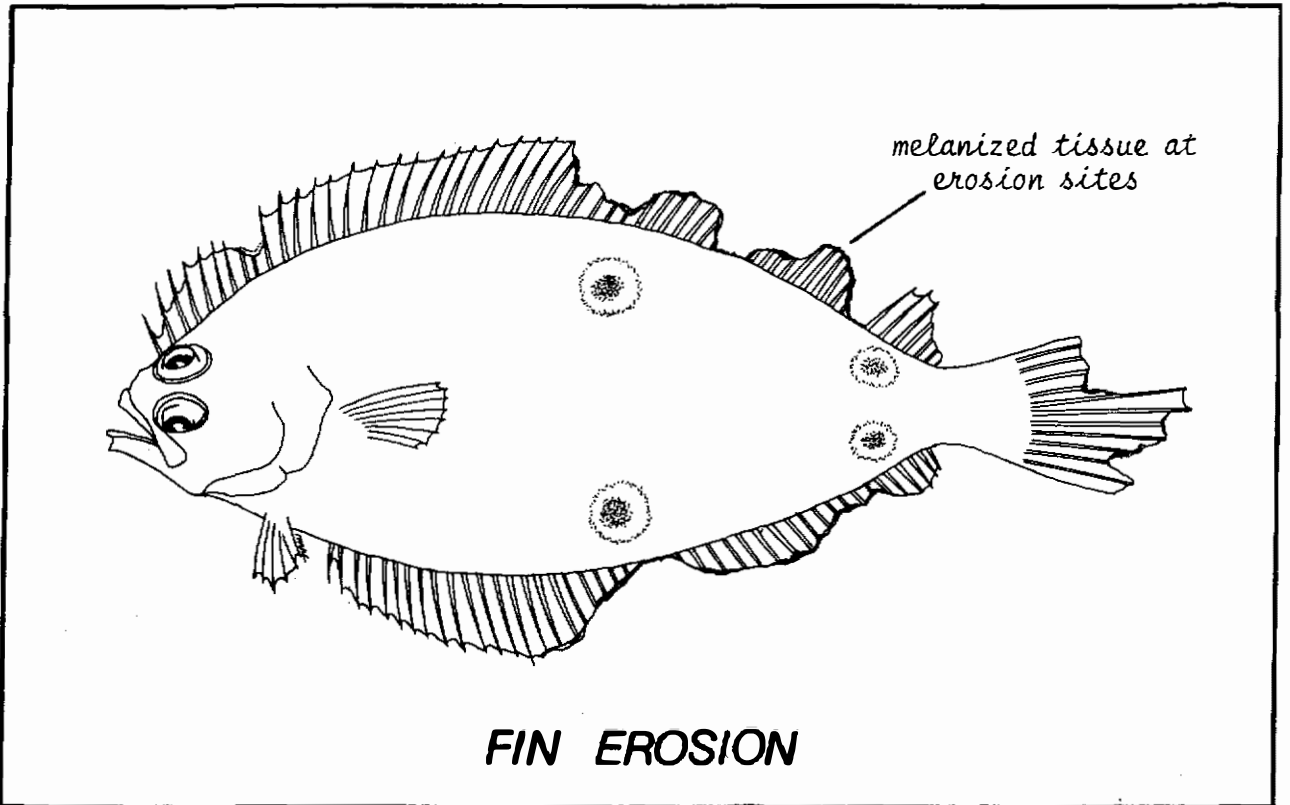


Figure 5. Gross indications of net damage in four-spot flounder, Paralichthys oblongus.

III. TUMORS (NEOPLASMS)

Although tumors have been studied principally in humans, the existence of tumors in fish and shellfish has been recognized for almost a century (the first oyster tumor, for example, was reported in 1887). Circumstantial evidence associating environmental contamination with neoplasms (tumors) in fish and shellfish has accumulated, but a clear causal relationship has not yet been demonstrated.

Tumors of many kinds have been demonstrated in fish -- in fact most types of tumors described in humans have their counterparts in fish (Schlumberger and Lucké, 1948). Examples of externally obvious fish tumors are given in Figure 6.

Tumors have been reported in many fishes. Some Pacific flatfish species are noted for the common occurrence of tumors described as epidermal papillomas. These neoplasms begin as small nodules and progress to the extensive involvement shown in Figure 7. Prevalences are often highest in young fish. Viral arrays have been seen in affected tissues, but the etiology of epidermal papillomas is still uncertain -- particularly since an unknown cell type (so-called X-cell) has been seen consistently. The relationship of this type of tumor with pollution is inconclusive. Thus far it has not been found in flatfish of the western North Atlantic.

"Cauliflower disease" (Blumenkohlkrankheit or papillomatosis) of European eels, Anguilla anguilla, is a remarkable tumorous growth, found principally in the head region (Figure 8). Prevalences have increased in coastal waters and estuaries of northern Europe since World War II, and a number of authors have suggested that increasing pollution levels may be responsible. This condition has not been reported from American eels, Anguilla rostrata.

A number of gadoid fishes have been found to have large tumors within the gill chamber -- so-called "pseudobranchial tumors" since they appear to arise from the pseudobranchial gland. They have been considered to be neoplasms (adenomas) although they contain large abnormal cells (X-cells) like those found in flatfish epidermal papillomas (Wellings et al., 1977). Pseudobranchial tumors have been reported in 7.4% of Pacific cod (Gadus macrocephalus) from the Bering Sea, and have also been seen in pollock (Theragra chalcogramma) from the Pacific (Takahashi, 1929) and from Atlantic cod (Gadus morhua) (Lange, 1973). The tumors may be recognized as large convoluted masses in the dorsal pharynx anterior to the gills (Figure 7).

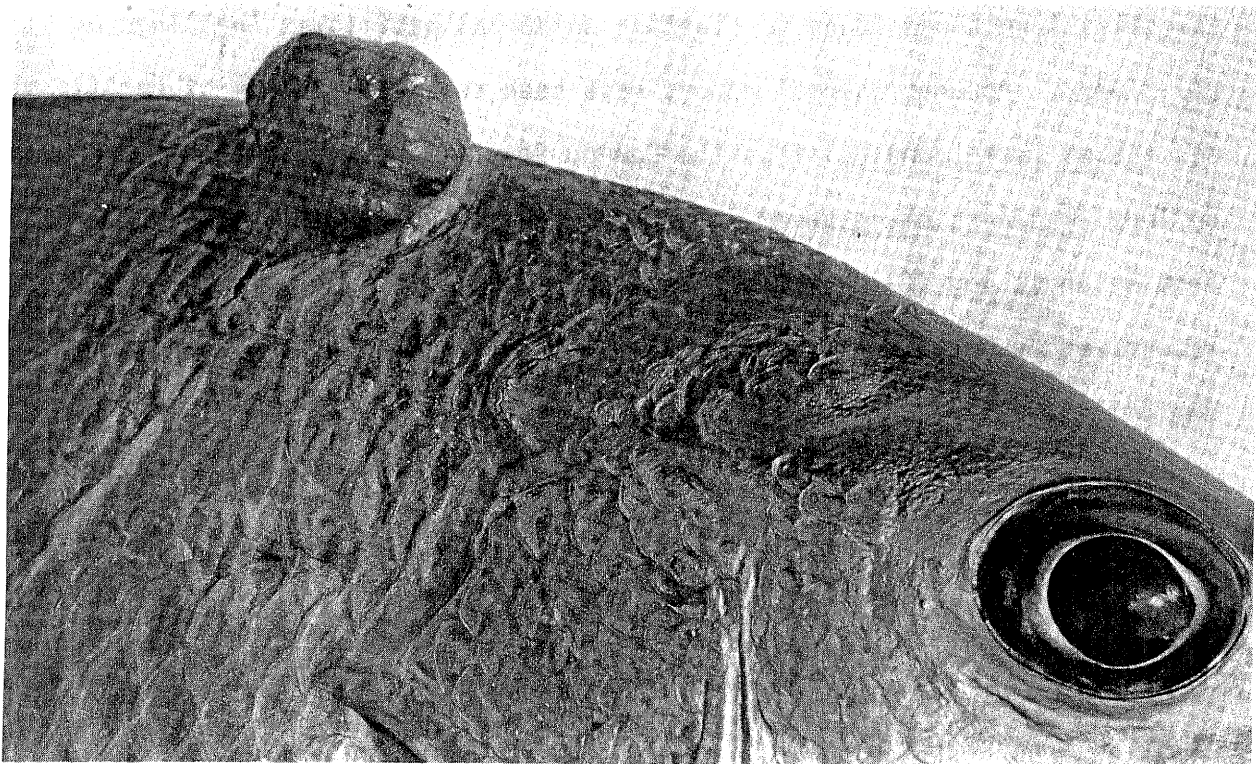
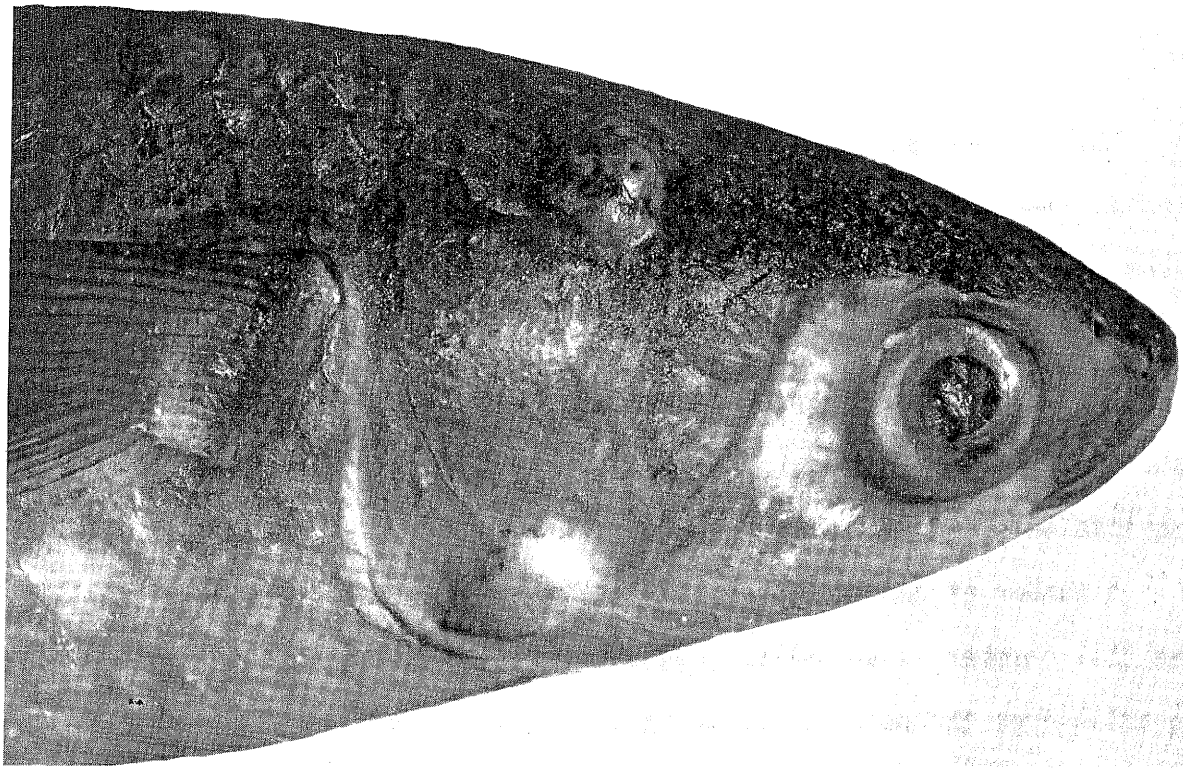


Figure 6. Wart-like fibrous tumors on mullet (above) and mesenchymal tumor on red snapper (below) from Biscayne Bay, Florida.

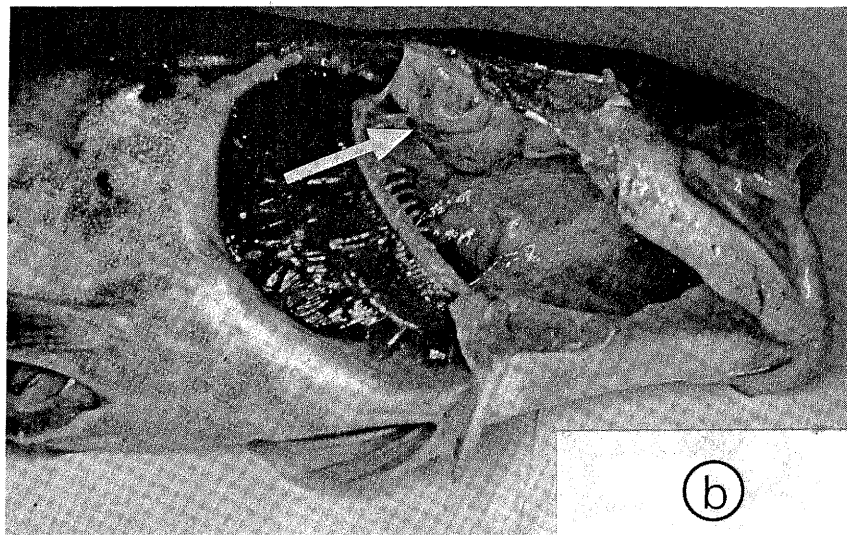



Figure 7. Epidermal papilloma in Dover sole (a) and pseudobranchial tumor in Pacific cod (b). (Photographs courtesy of Ms. M. Sherwood, Southern California Coastal Water Research Project; and Dr. S. Wellings, University of California).

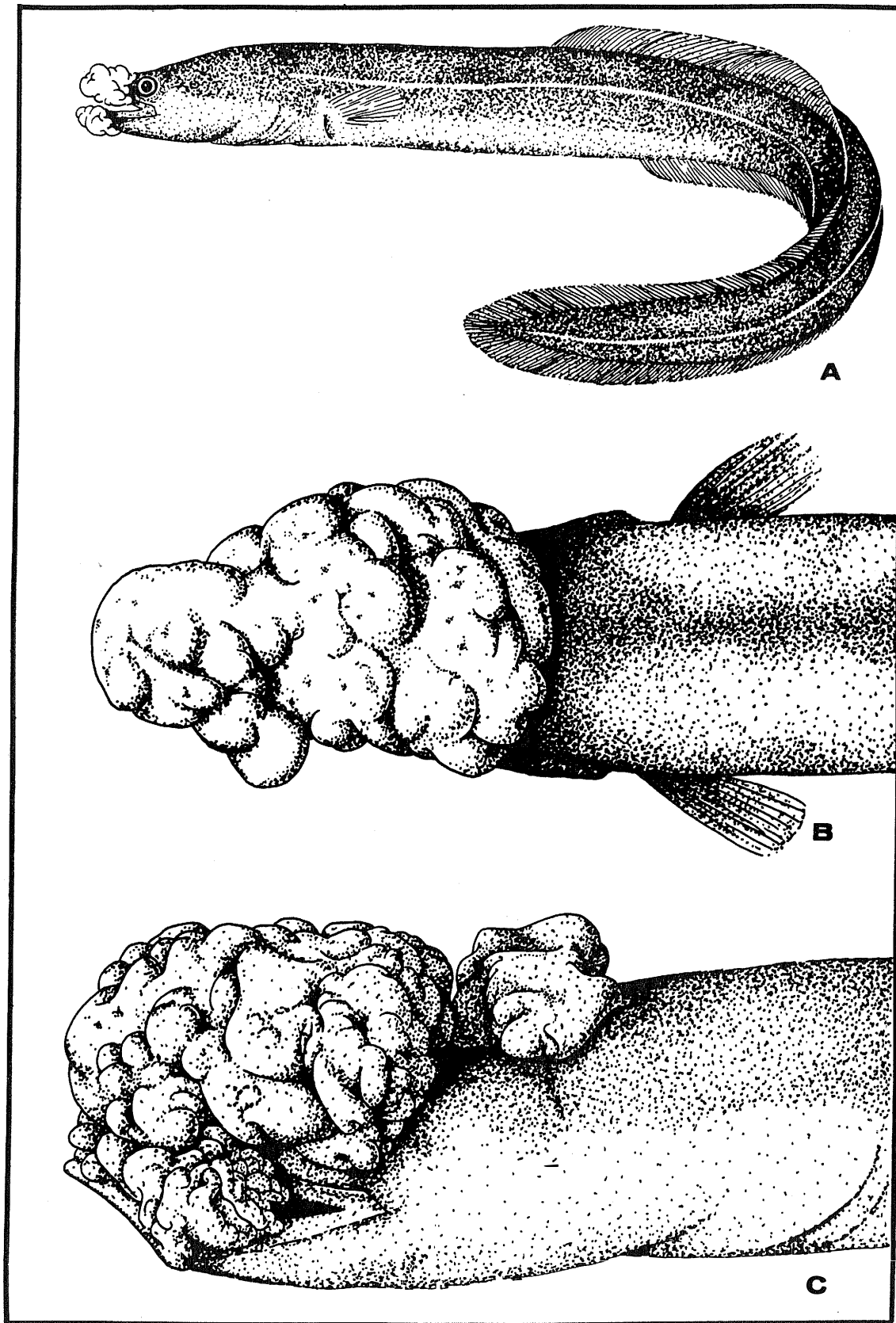


Figure 8. Progressive stages of eel cauliflower disease (Blumenkohlkrankheit) in European eels, *Anguilla anguilla* (from Sindermann, 1970).

IV. LYMPHOCYSTIS

Lymphocystis (sometimes called "fish mange") is caused by a virus infection which results in enormous enlargement of individual skin cells, often forming tumor-like nodules on fins and body surfaces (Figure 9). The disease occurs in many fresh water, estuarine, and marine fishes; it has been observed in epizootic proportions in certain species, with prevalences up to 68% of individuals in particular samples (Murchelano and Bridges, 1976).

A number of flatfish -- plaice (Pleuronectes platessa), European flounder (Platichthys flesus), dab (Limanda limanda), American plaice (Hippoglossoides platessoides), summer flounder (Paralichthys dentatus), and winter flounder (Pseudopleuronectes americanus) -- are susceptible to lymphocystis infections. Epizootic levels of infection have been reported in H. platessoides, P. platessa, P. flesus, and P. americanus (Templeman, 1965; Mann, 1970; van Banning, 1971; Perkins et al., 1972; Shelton and Wilson, 1973).

Additionally, striped bass (Morone saxatilis) which overwinter in heated effluents of coastal power stations will frequently be infected with lymphocystis (Figure 10). The disease can be common in aquarium fishes too (Nigrelli and Ruggieri, 1965).

Lymphocystis has been reported recently in Baltic herring (Clupea harengus var. membras) by Aneer and Ljungberg (1976). Fourteen of 2629 individuals had gross signs of the disease. The authors pointed out that a number of infections were slight, and might easily have been overlooked. It is quite likely that this is also the case with other species.

The presence of lymphocystis cells on the viscera of herring was noted by Aneer and Ljungberg; there are several other reports of systemic lymphocystis infections, particularly that of Dukes and Lawler (1975) in which lymphocystis cells were found in and behind the eyes and kidney, spleen, liver, heart, ovaries, and mesenteries of silver perch (Bardiella chrysura).

Lymphocystis is considered highly infectious but usually non-fatal; infection may occur at sites of injury or minor abrasions; gross signs of infection vary seasonally; infectivity seems to have a direct temperature relationship; and gross disease signs may disappear from individual infected fish in a few months' time.

The disease may be readily recognized by a usually gray-colored tapioca-like enlargement of few or many skin cells; often in severe infections the enlarged cells become confluent, producing pea-sized nodules which may sometimes be accompanied by some hemorrhaging. Confirmation with histological examination is recommended, since the disease might be confused with early epidermal papillomas.

The "blind" side of flatfish should receive particular attention, especially the undersides of the pectoral, dorsal, and anal fins.




Figure 9. Lymphocystis in plaice, *Pleuronectes platessa*. (Photograph courtesy of Dr. P. van Banning, Rijksinstituut voor Visserijonderzoek).

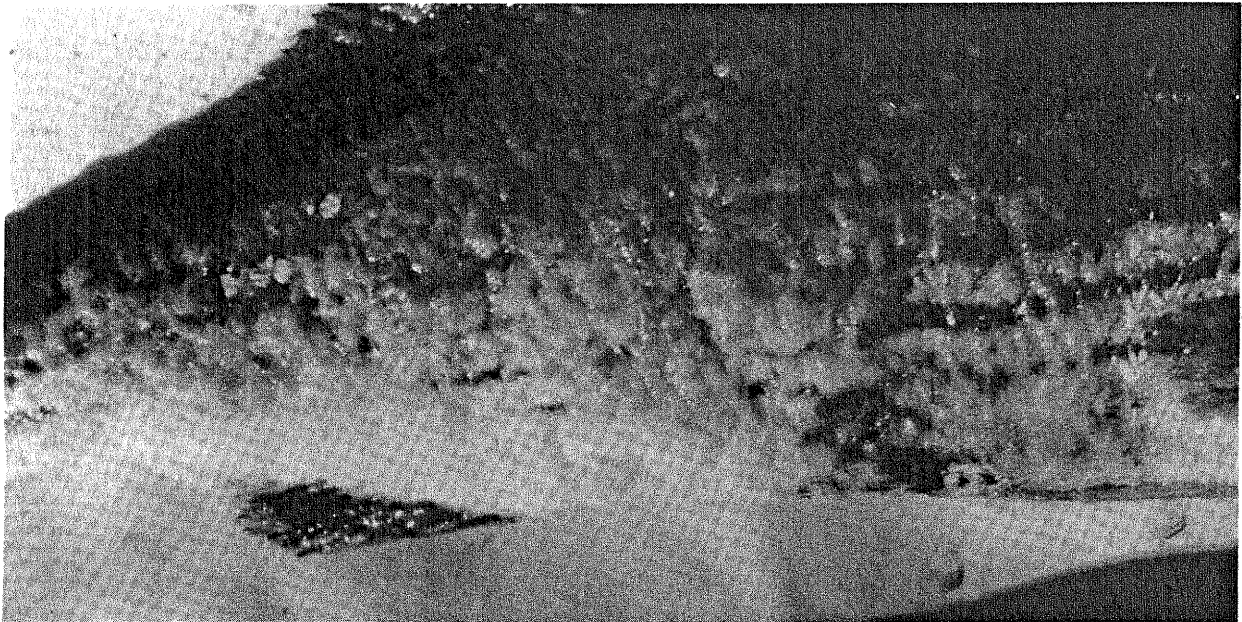


Figure 10. Lymphocystis disease in striped bass from heated effluent of a power plant.

V. BLACK SPOTS

Fish of many species -- especially those which inhabit estuarine or nearshore waters for at least part of their lives -- often exhibit pinhead-size black spots which are the consequence of larval trematode invasion. The life cycles of the parasites usually involve a mollusk, then the fish as an intermediate host, and then a predator of the fish (a larger fish or fish-eating bird or mammal) as the definitive host.

The larval stage (cercaria) which penetrates and encysts in the integument of the fish elicits the gradual accumulation of host pigment cells (melanophores) around the cyst, resulting in a black spot. Size of the spots and intensity of pigmentation is thus dependent on length of time after invasion. Numbers of such spots may be few or many (Figure 11), depending on the availability of infective cercariae in the immediate habitat of the fish.

One of the best-studied of the trematodes which cause "black spots" in fish is Cryptocotyle lingua, which is very common in northern Europe and North America. Its life cycle involves three hosts in sequence; a snail (Littorina), coastal fish (especially sea herring, but also including cod), and the sea gull (Figure 11). Immature sea herring and certain other species which inhabit coastal waters near infected Littorina populations may have literally hundreds of black spots on fins and body surfaces. Experimentally, heavy larval trematode invasion has been shown to kill or blind young fish; conspicuous black spots developed in survivors within a few weeks after experimental exposure.

It should be noted that not all larval trematodes which encyst in the integument of fish will cause black spots. For example, winter flounder (Pseudopleuronectes americanus) from the western North Atlantic are often parasitized by larvae of Stephanostomum baccatum, which matures in the sea raven (Figure 12). The opaque white unpigmented metacercarial cysts can be seen easily on the blind side of infected flounders, frequently in large numbers.

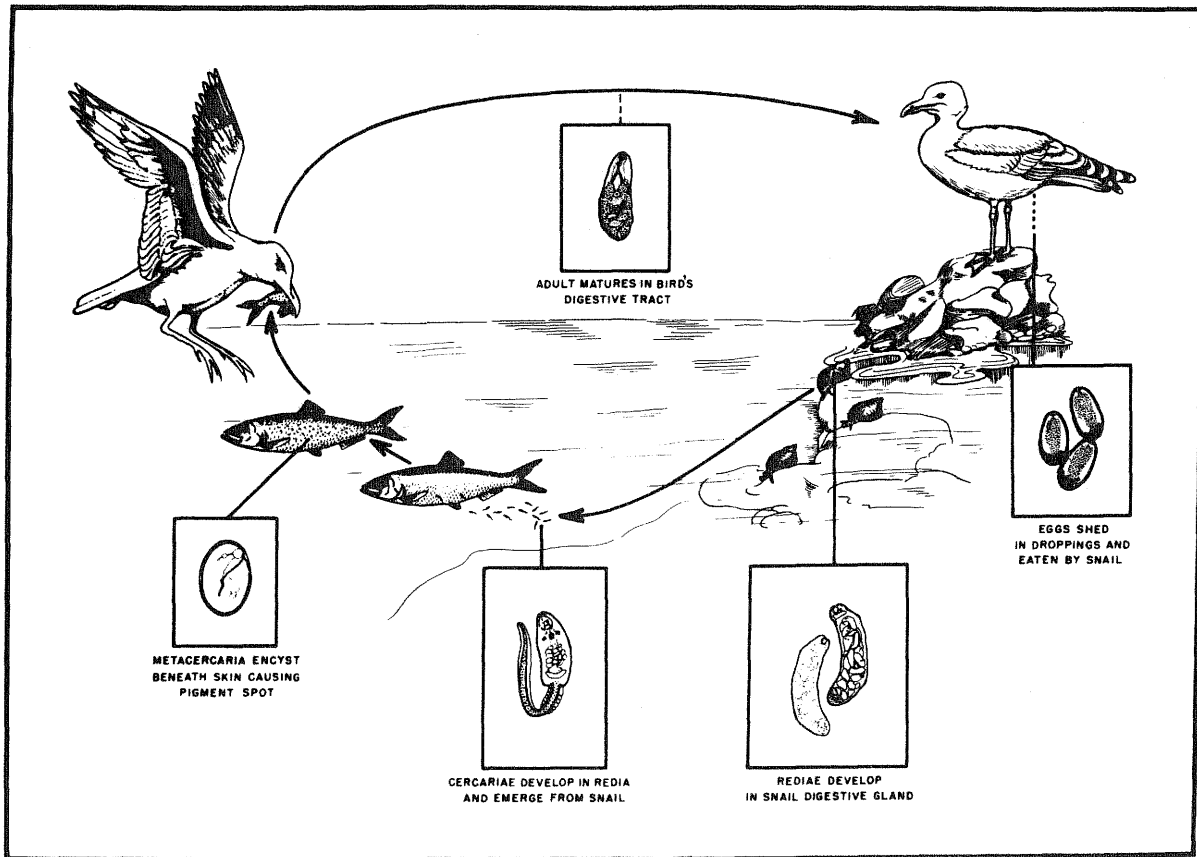
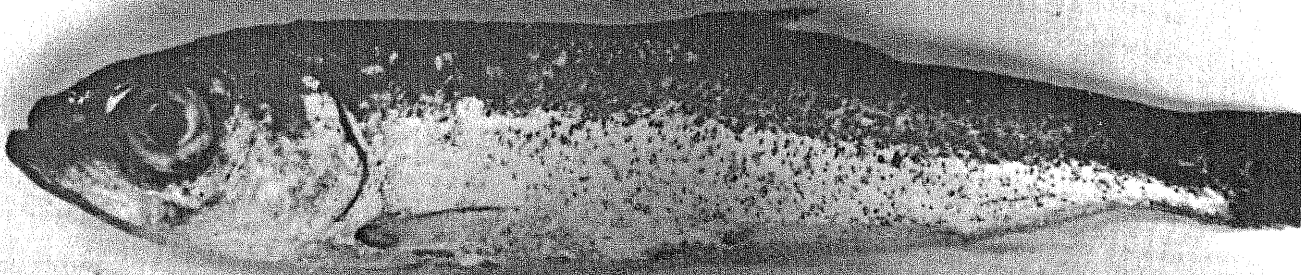


Figure 11. Immature sea herring (*Clupea harengus*) with black spots caused by larval trematode invasion (above), and the life cycle of the causative organism, the trematode *Cryptocotyle lingua* (below). From Sindermann and Farrin, 1962.

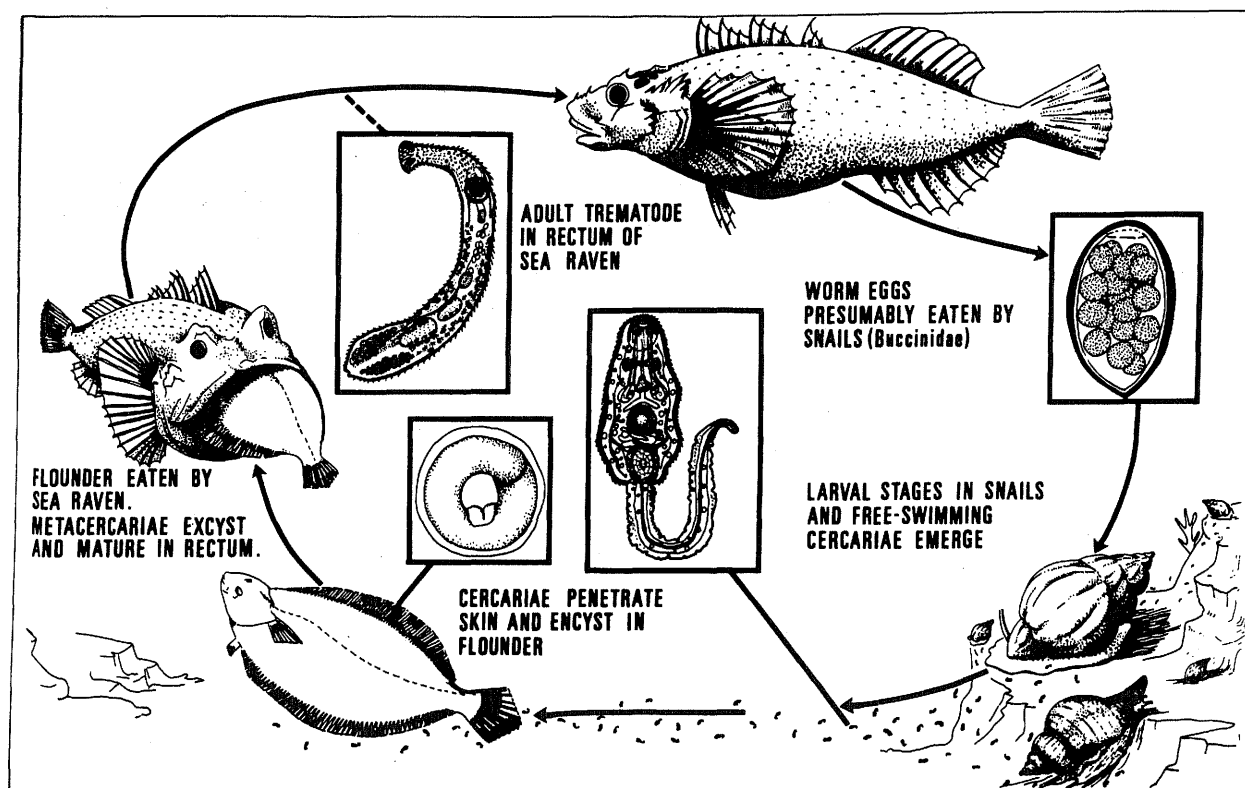


Figure 12. Life cycle of *Stephanostomum baccatum*. (Modified from Wolfgang, 1955).

VI. PARASITIC COPEPODS

Many marine fishes are parasitized by large and often highly modified copepods. Shapes are often bizarre in the extreme, and the copepods may cause extensive tissue damage when they anchor or burrow into the fish. Some attach to gills, and others to the body surfaces. Some even attach to the eyes.

Several families (Lernaeoceridae, Sphyridae, and Penellidae) are particularly injurious to the host. Usually the adult females in these groups become highly modified and penetrate the flesh, often causing extensive ulceration (Figure 13), which may persist after the copepod dies. Usually only a few copepods are found on any single host, and those attached to body surfaces may be encrusted with algae.

Figure 14 illustrates just a few of the more conspicuous and harmful members of this group of parasites. There are many others (especially on the gills) that are less conspicuous and less injurious to the host, unless they occur in large numbers. There are still others, often referred to as "fish lice" which can be found loosely attached to the body surfaces (Figure 13). Many of these smaller copepods are less-modified than the ones pictured, and many will have a pair of cylindrical egg cases, which are often opaque white.


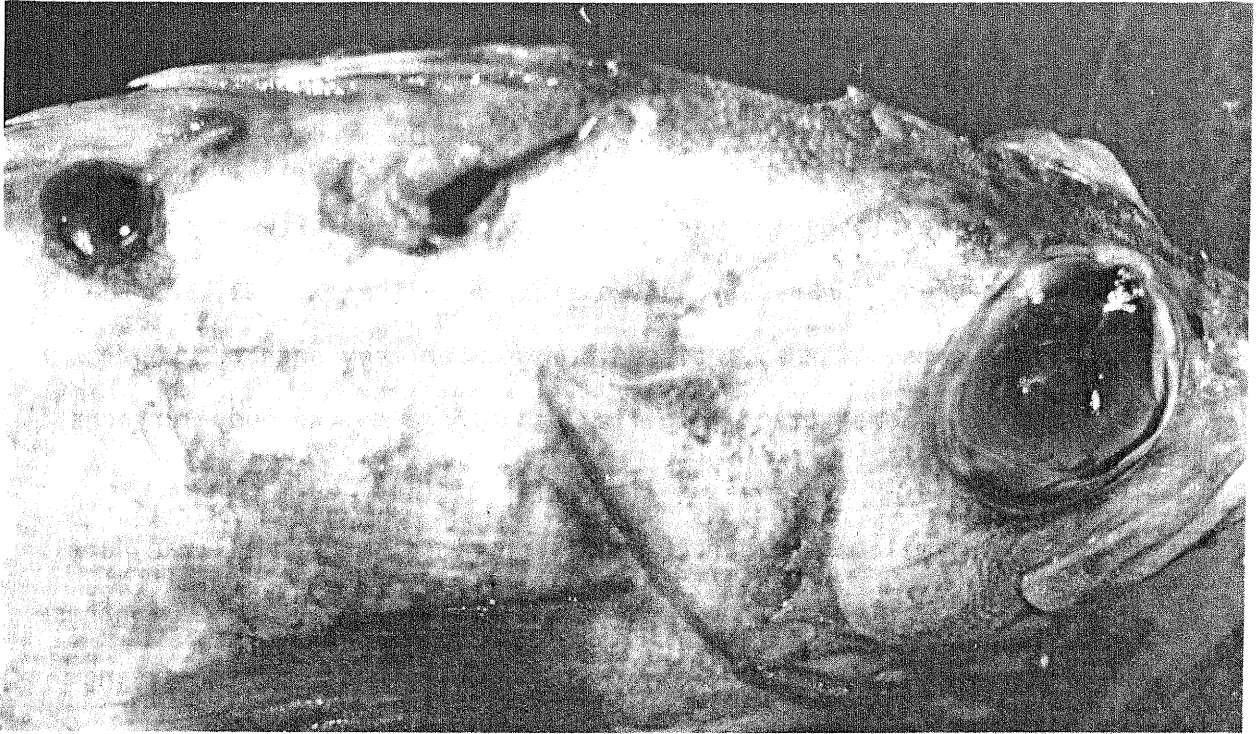


Figure 13. The parasitic copepods *Sphyrion lumpi* on redfish, *Sebastes marinus* (above) and *Lepeophthirus salmonis* on body surfaces of Atlantic salmon (below). (Photograph courtesy of Dr. E. Egidius, Institute of Marine Research, Bergen).

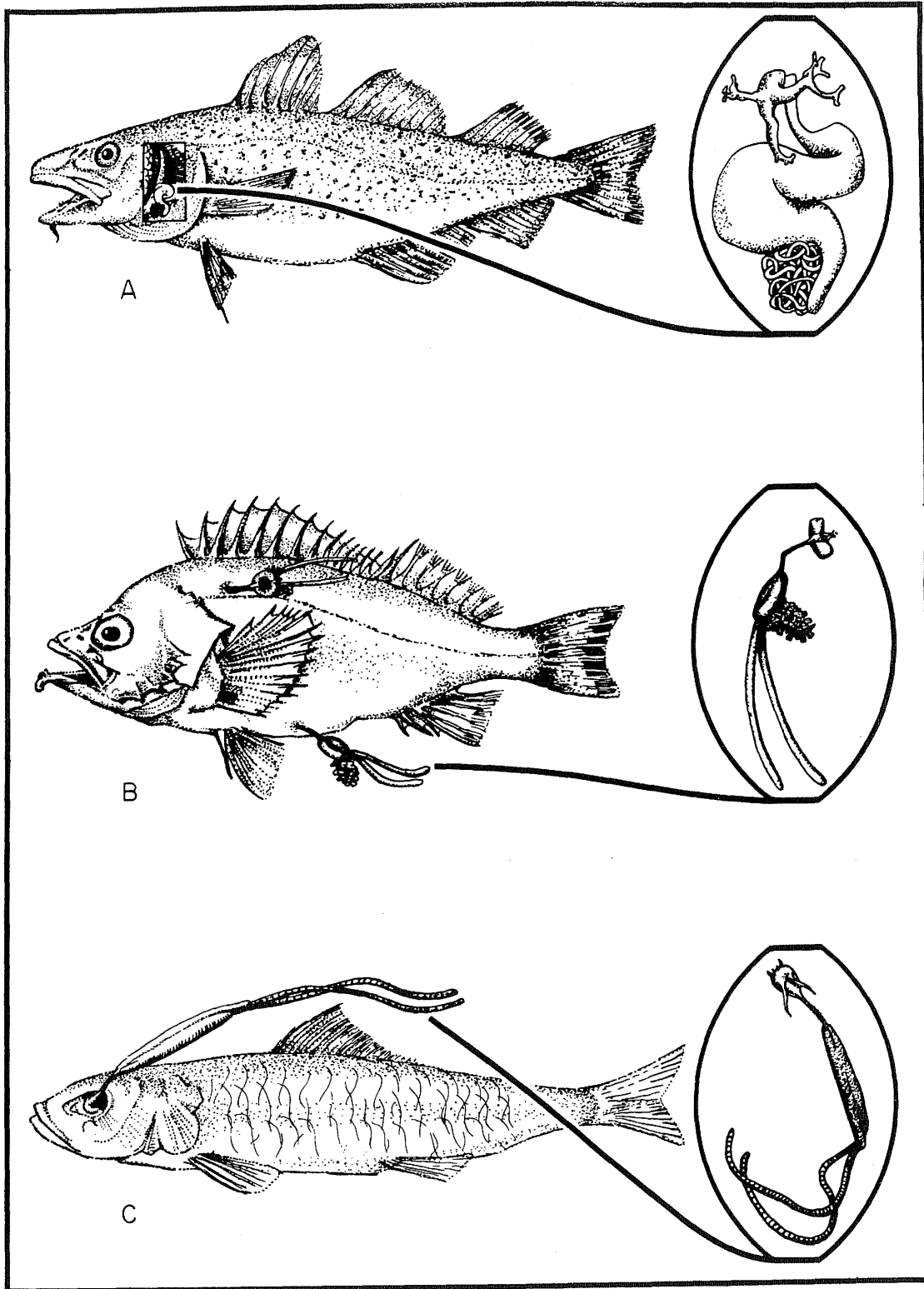


Figure 14. Some parasitic copepods: (A) *Lernaecera branchialis* from the gill chamber of cod, (B) *Sphyrion lumpi* from redfish, and (C) *Lernaeenicus sprattae* from the sardine (from Sindermann, 1970).

Note: We feel that the final sections of this guide need a brief introduction, because, unlike the disease conditions discussed in previous sections, the abnormalities described in these final sections are degrees of morphological divergence from an established form. Therefore, when dealing with the conditions which follow, it becomes necessary to give careful consideration to inherent tendencies toward modification of parts. Also, as a result of differential species or body part vulnerability to variation, the significance of these conditions may change among populations or indeed within sibling groups.

These final categories can be described loosely as "developmental abnormalities" -- morphological features which may depart naturally from a statistical norm. Although there are many kinds and degrees of such abnormalities, they will be grouped and discussed generally as (VII.) skeletal anomalies, (VIII.) reversed laterality in flatfish, and (IX.) abnormal pigmentation. Each of these will be considered in following sections.

VII. SKELETAL ABNORMALITIES

Gross skeletal abnormalities of fish such as pugheadedness, dwarfism, and spinal curvatures (Figure 15), have been observed and recorded for centuries -- long before significant pollution of the marine environment existed (Hickey, 1972). Spinal flexures, compressions and fusions have been observed in many teleosts, as have head and fin abnormalities. Early ichthyologists sometimes mistakenly used these conditions, or accompanying lesser deformities, to distinguish new species.

Grossly recognizable skeletal anomalies are usually rare in marine fish populations (Ford, 1937) -- rare enough so that single malformed individuals have been reported in the scientific literature. Recently, though, there have been several reports of high prevalences of certain kinds of gross abnormalities. For example, pugheadedness was found in more than 10% of young striped bass, Morone saxatilis, and weakfish, Cynoscion regalis, collected at two trawl stations in the lower Hudson River estuary in 1973 (Ziskowski and Anderson, unpublished data).

Increased prevalences of skeletal deformities and anomalies -- considered to be pollution-associated -- have also been recognized in a few Pacific species from southern California and Japan. Deformed gill rakers were the most prevalent anomalies observed in southern California barred sand bass (Paralabrax nebulifer); other abnormalities (pugheadedness, cranial asymmetries, deformed vertebrae, and fin anomalies) occurred, and were associated directly in frequency and severity with gill

raker deformity. Several reports from Japan refer to high and increasing prevalences of skeletal anomalies in several species of fish. Malformed sweetfish, Plecoglossus altivelis, were observed in rivers and culture farms, and skeletal anomalies were seen in a number of coastal species (Matusato, 1973; Komada, 1974; Ueki and Sugiyama, 1976).

In the field, skeletal abnormalities can sometimes be as obvious as those in Figure 16, but more often they are subtle and not externally apparent. Therefore, it is usually necessary to collect entire lots rather than attempting to cull suspect individuals. An exception occurs among winter flounder taken from waters adjacent to New York harbor. They are observed to exhibit what appears to be merely a peculiar condition of bent or broken fin rays (Figure 17). In severe cases a line of flexure occurs along whole portions of fins. However, after radiological examination it is found that these fish also display an unusually high incidence of skeletal deformities such as vertebral fusions, accessory processes, or hyperossification. So seemingly minor external evidence of abnormality can, in some cases, reflect a more extreme internal malformation.

Experiments, particularly those concerned with temperature effects on axial skeletal parts, and field observations, focusing on meristic characters and their relation to habitat, have shown that skeletal structure is governed by environmental as well as genetic influences (Hubbs, 1943, Hubbs and Hubbs, 1945; Täning, 1952; Bailey and Gosline, 1955; Barlow, 1961; Fowler, 1970; Hickey, 1972; and others). Any

abnormal fluctuation in these factors, whether genetic or environmental, can cause morphological variations in the phenotype. The significance of these developmental abnormalities may vary depending on severity or prevalence levels. Experiments with the sea trout, Salmo trutta trutta, have shown that different groups or series of bones and their respective processes develop, for the most part, independently. A given series is more vulnerable to environmentally induced change during a specific "sensitive" period (or periods). (Tåning, 1952; Barlow, 1961; Fowler, 1970). Further, the sensitive periods of different skeletal groups do not coincide, and certain skeletal structures are genetically more flexible than others (Hubbs and Hubbs, 1945; Tåning, 1952; Fowler, 1970; and others). Consequently, the interrelation of environmental circumstances during development and structural susceptibility (as demonstrated by prevalence and severity) is difficult to interpret. Well planned sampling and detailed study are necessary before any real ecological correlations can be made.




Figure 15. Gross skeletal anomalies: (A) pugheadedness in striped bass, (B) Scoliosis in sea herring, (C) dwarfism in haddock, and (D) abnormal fins in skate. (From Sindermann, 1970).

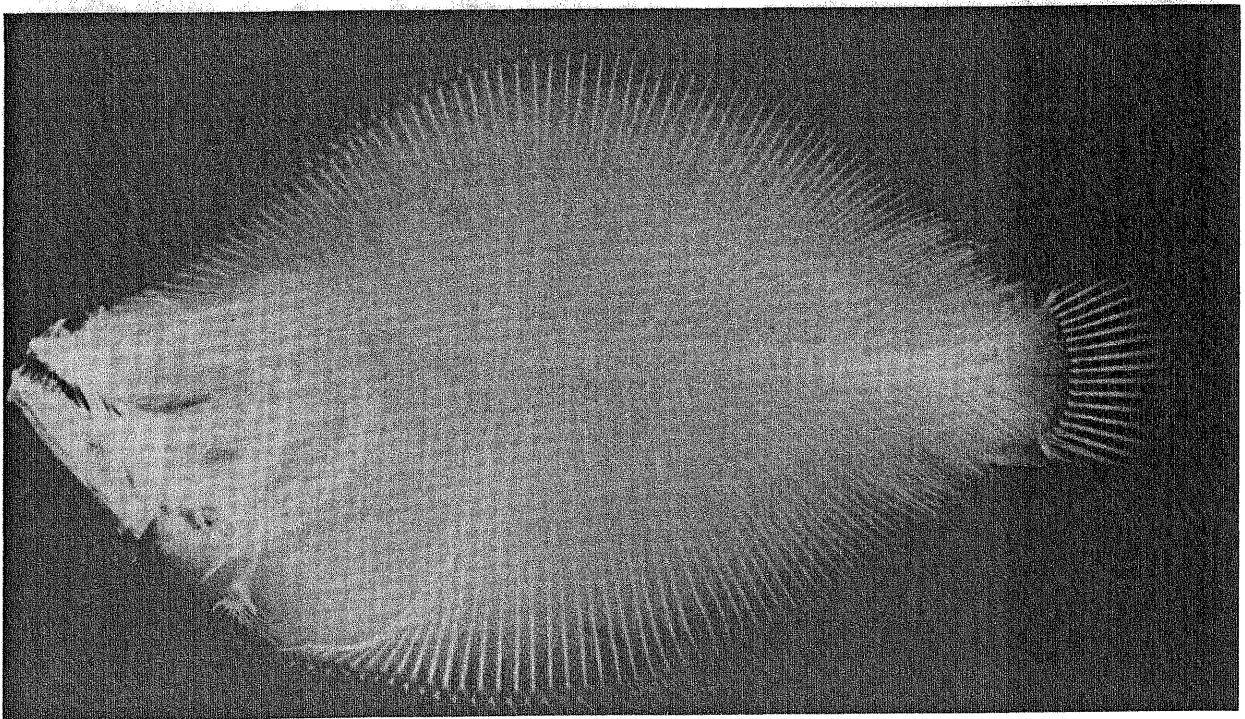
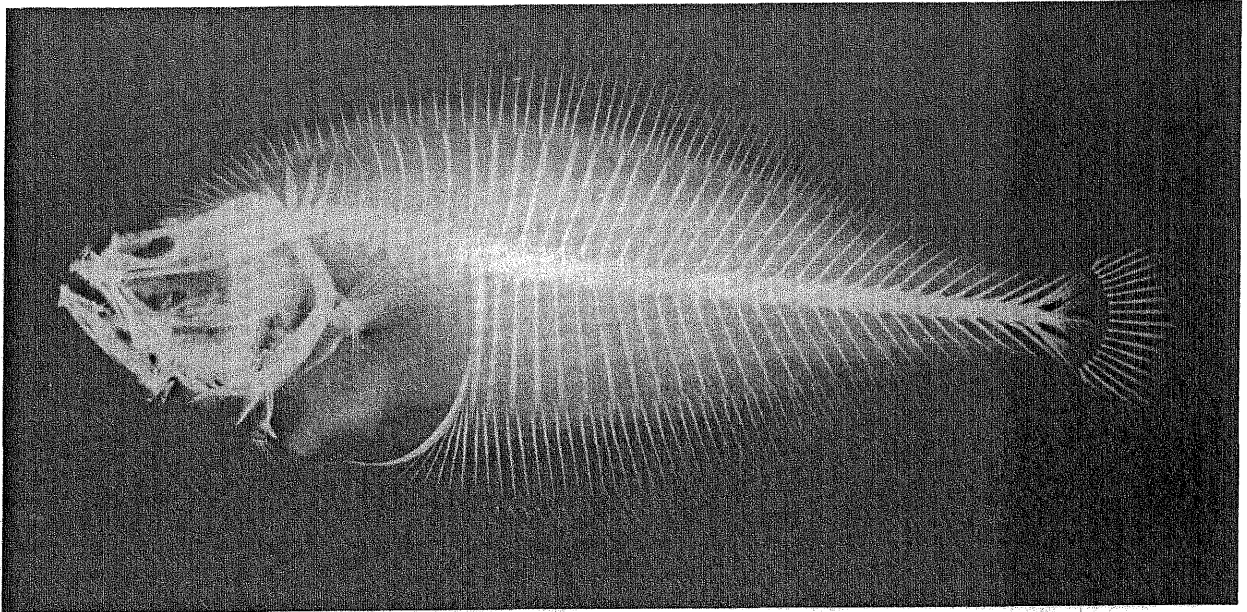


Figure 16. X-ray of normal (above) and "dwarf" (below) summer flounder, *Paralichthys dentatus*, showing fused vertebrae.

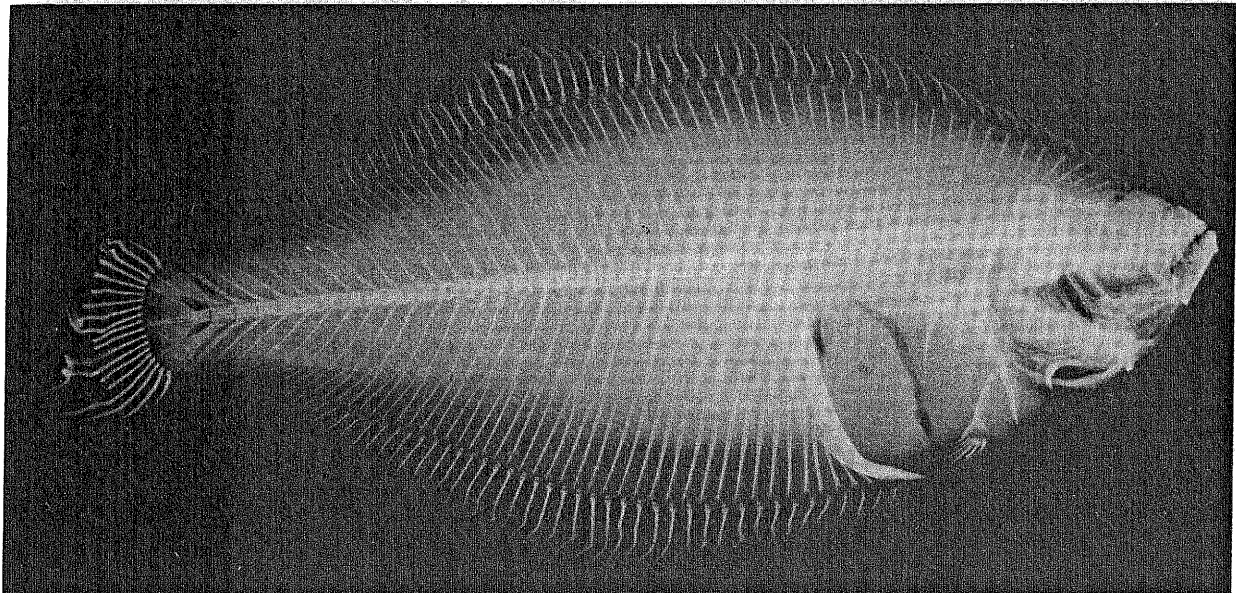
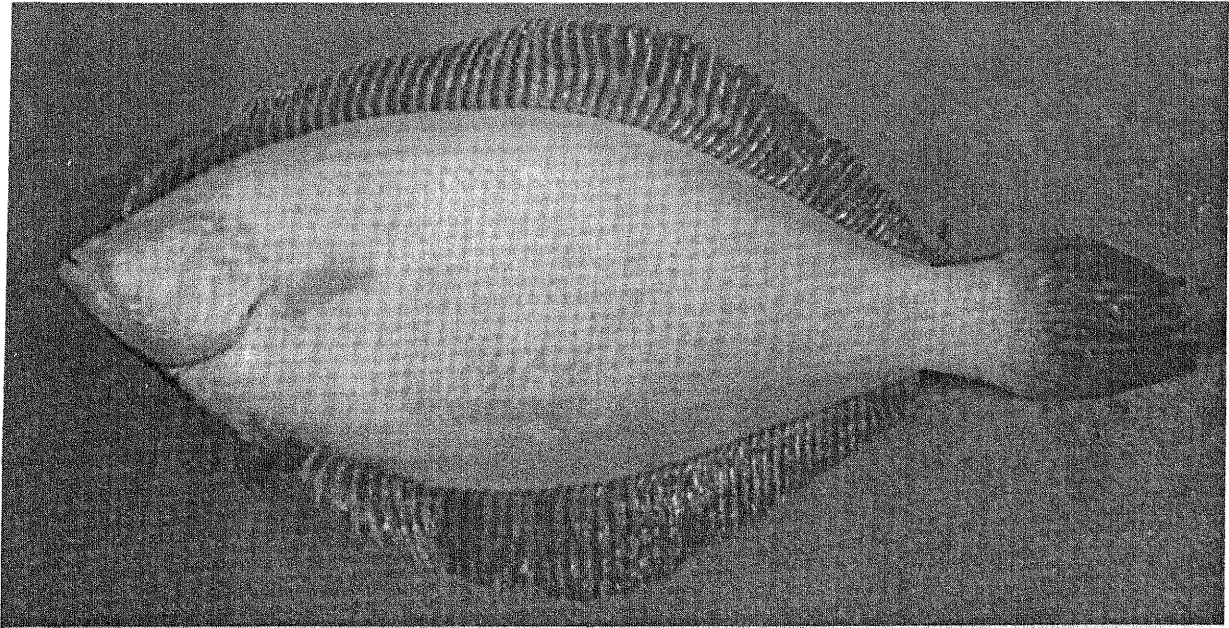


Figure 17. Bent fin rays in winter flounder from the New York Bight. External appearance (above) and radiograph (below).


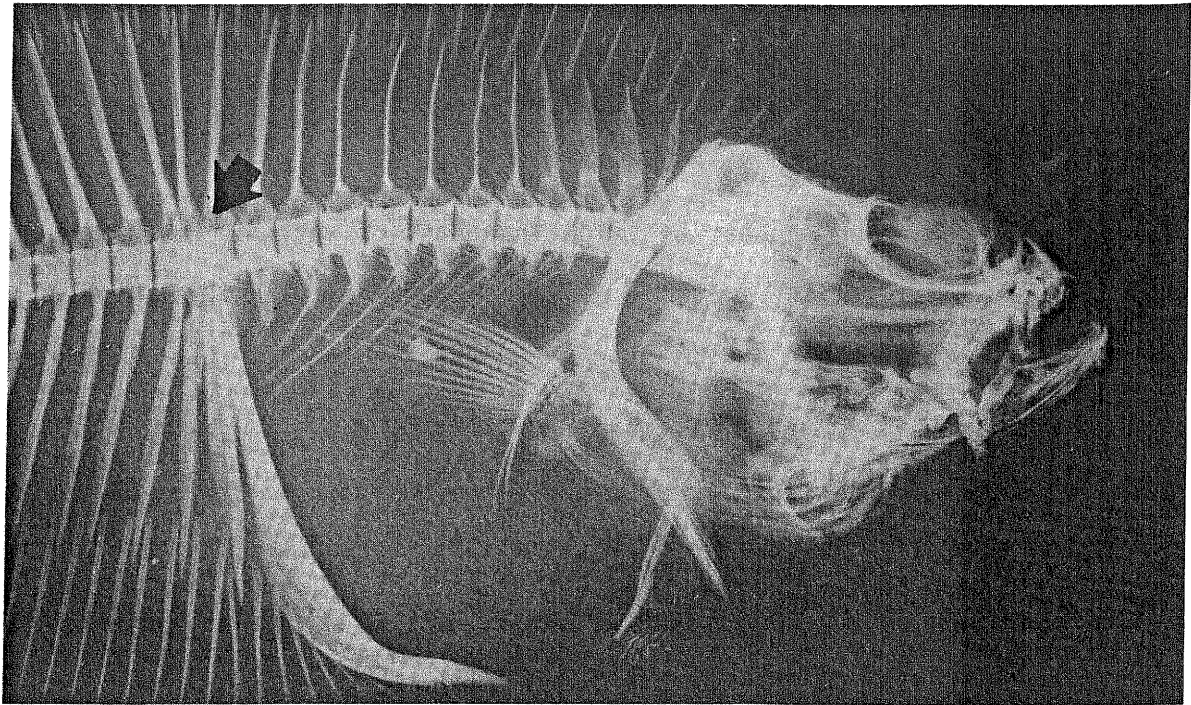


Figure 18. Fusion of last abdominal and a complex first caudal centrum in a winter flounder with bent fin rays (above); Variation within the control sample of winter flounder (accessory haemal and neural arches on caudal vertebrae) (below).

VIII. REVERSAL IN FLATFISH

Reversed laterality -- in which individuals of species which are normally "left-handed" appear as "right-handed", or vice versa -- has been reported in all four families of flatfishes (Norman, 1934; Gudger, 1935; Dawson, 1964, 1966, 1971; Dawson and Heal, 1976) and may occur among all species. Reversal is, however, more common in the families Bothidae and Pleuronectidae than in the families Soleidae and Cynoglossidae (Figure 19).

Reversal is considered to be primarily a genetic aberration -- a return toward bilateral symmetry, which may have its origin in development of the central nervous system (Hubbs, in Gudger, 1935). However, the condition has been associated with environmental stress. High incidence of reversal (over 50%) has been reported in populations bordering on geographic range limits (Norman, 1934; Hubbs and Hubbs, 1945). Sinistral Pleuronectidae found in rearing experiments were attributed to the culture environment (Houde, 1971). These studies suggest that adverse environmental conditions may cause genetic damage or may affect morphological development during some early stages of development. However, no real estimates were given in the rearing study as to how many eggs were actually used, so the ratio -- thus the significance -- of abnormal to normal fish may be lower than indicated.

In the field, reversal is commonly found by commercial filleters, field technicians and sport fishermen. When handling the fish, these people make a series of precise actions, usually determined by which side the eyes are on for a group of individuals of the same species. When a

reversed individual is encountered, the normal procedure is altered and usually stopped. The desired body part which is to be counted, measured, or used as a reference guide for a proper cut, is suddenly on the opposite side. Figure 21 (below) is a good example. Although not reversed, the ambicolorate blind side was mistaken for the eyed right-side. After the first cut behind the head rather than above and behind it, filleting was stopped with the realization that the fish was, in this case, upside-down. In another instance, while doing routine gill raker counts on summer flounders, normal handling procedure was halted when an individual fish was found in which, after the technician reached for its opercular flap with a pair of forceps, it was immediately apparent that the fish was upside-down and in fact reversed.

Reversal may be accompanied by a number of other abnormalities:

- (1) ambicoloration (Norman, 1934; Hubbs and Hubbs, 1945; Houde, 1971; Dawson, 1962; Gudger, 1935, 1936);
- (2) incomplete eye migration and abnormal dorsal fin development characterized by an anterior fleshy appendage or "hook" (Gudger, 1935; Deubler and Fahy, 1958); and Figure 21a;
- (3) high frequencies of skeletal abnormalities (Houde, 1971; and Anderson, unpublished data);
- (4) dwarfism (Anderson, unpublished data);
- (5) reversed orientation of scales (Norman, 1934; Hubbs and Hubbs, 1945);
- (6) albinism (Norman, 1934);

- (7) addition or loss of paired fins (Norman, 1934; Hubbs and Hubbs, 1945);
- (8) overdeveloped musculature on the blind side (Anderson, unpublished data). The ambicolored specimen in Figure 21b exhibits this condition.

All of these conditions should be looked for when handling flatfish and may be helpful in recognizing reversed individuals.

The relative position of the optic nerves (Figure 20) can be used to determine if a specimen is indeed a reversed bothid or pleuronectid (Regan, 1910; Kyle, 1923). For example, in the family Bothidae, the optic nerve of the right eye is dorsal to that of the left regardless of which eye migrates. For normal bothids (left-eyed), this provides for a simple or direct upward movement of the dorsal nerve during metamorphosis, as the right eye revolves over to the left side of the head. In reversed forms, the dorsal nerve remains stationary, for it is the left eye which migrates. Thus the ventral nerve of the now migrating (left) eye must bend around the dorsal nerve of the now stationary (right) eye when moving to the other side of the head. For the family Pleuronectidae (right-eyed), the situation is reversed because the nerve of the left eye is always dorsal to that of the right (Figure 20) (Anderson, in press).

More investigation is needed to understand reversal as a morphological phenomenon which can be correlated with external influences. Sampling methods, study procedures, and experimental methods must take into account differential species or racial prevalences.

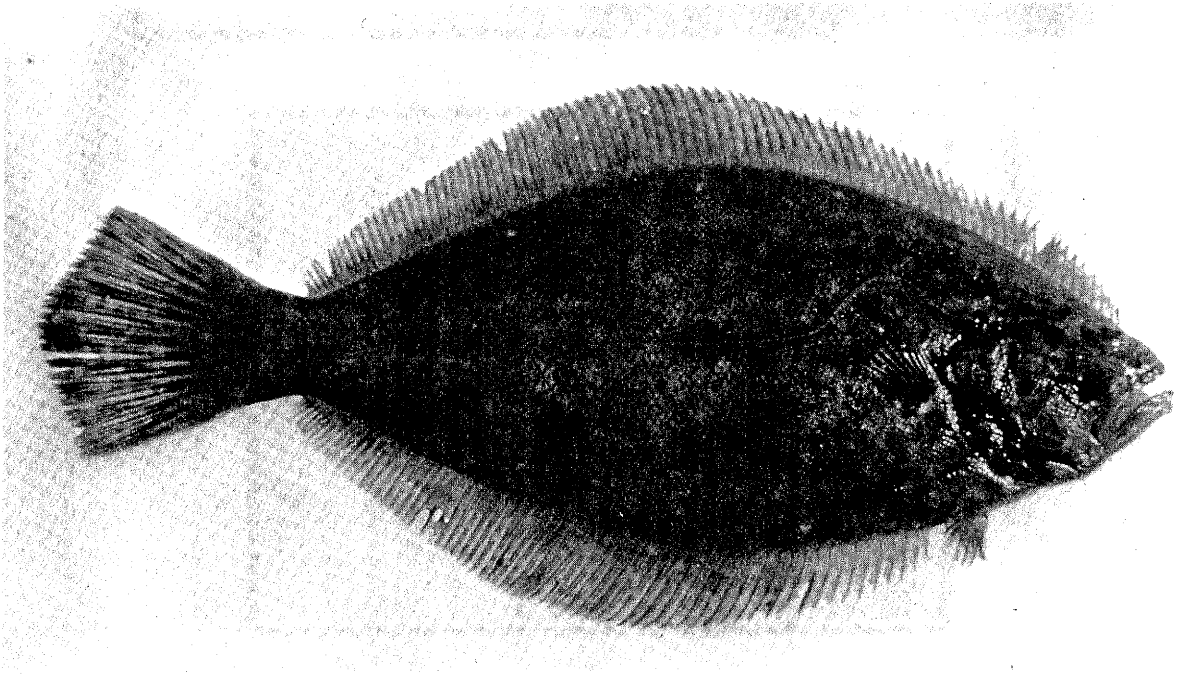
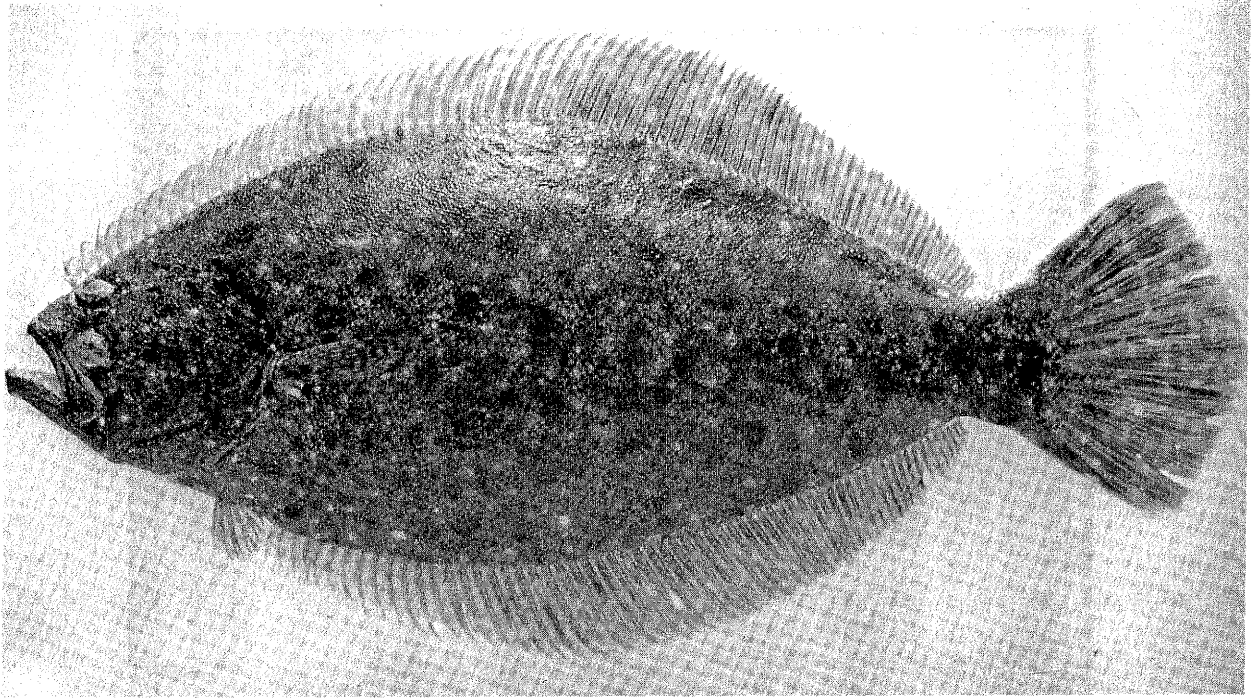

Figure 19. Reversed summer flounder (normal above, reversed below).
(Photographs courtesy of Mr. S. Wilk and Mr. M. Silverman,
NMFS, Sandy Hook Laboratory).

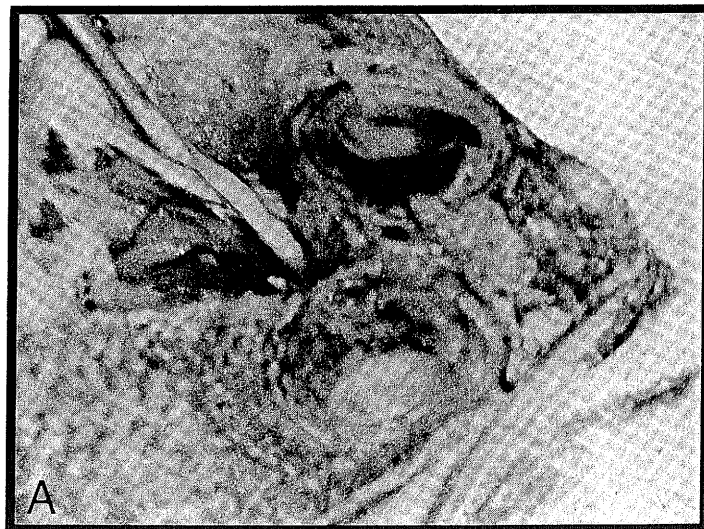
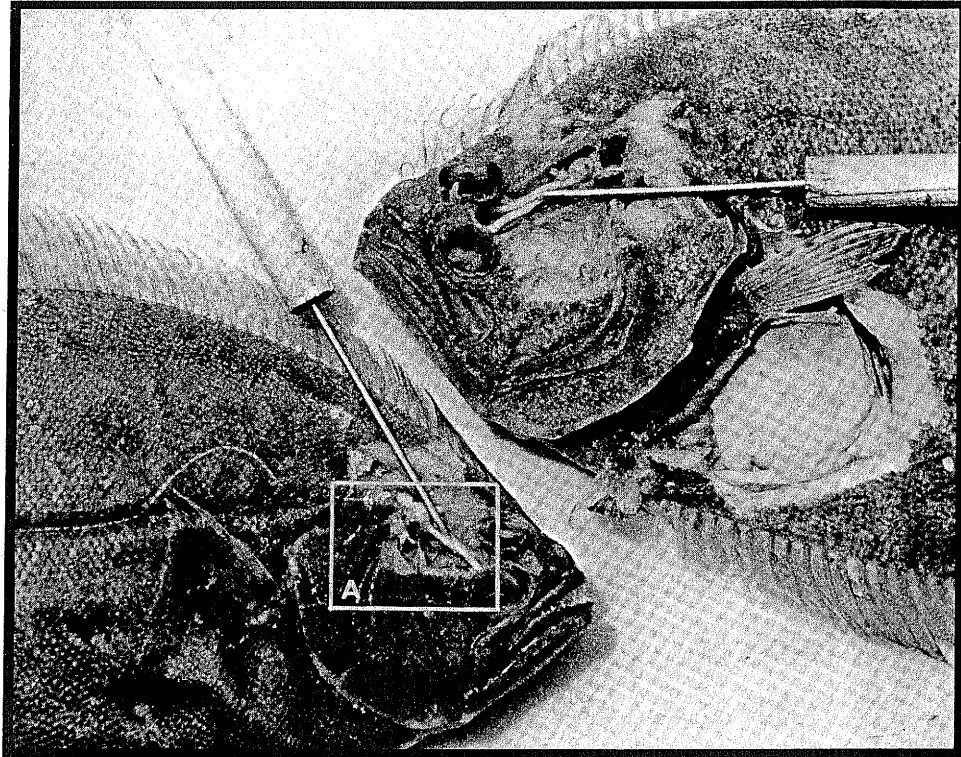


Figure 20. Dissection of summer flounder, showing normal position of the optic nerves (upper photograph, right side) and crossed optic nerves of reversed fish (upper photograph, left side) with enlarged view of crossed nerves (lower photograph). Photographs courtesy of Mr. M. Silverman, NMFS, Sandy Hook Laboratory).

IX. ABNORMAL PIGMENTATION IN FLATFISH

Occasionally, flatfish are seen with patches of dark pigmentation on the normally light-colored blind side (ambicoloration -- a term coined by Cunningham and McMunn, 1893) -- or with unpigmented patches on the normally dark-colored eyed side (partial albinism).

Ambicoloration of flatfish is probably the most common anomaly among members of the Order. Pigmentation on the normally white underside of the fish, of several types and degrees of severity, has been recorded for many species. These anomalies have been reported in the scientific literature for two centuries, and it seems that the causation is not simple -- involving innate as well as environmental factors (deVeen, 1969; Stickney and White, 1975). Norman (1934) found this condition to have much the same origin(s) as reversal and earlier authors suggested that ambicoloration merely represents variation in the direction of the original bilateral symmetry of ancestral forms. Later experimental studies have shown that susceptibility to environmental changes causes many of the ambicolor effects, demonstrating that the phenomenon is not primarily a genetic aberration (deVeen, 1969; Stickney and White, 1975). In the rearing experiments of Stickney and White, ambicoloration was produced, stopped, and retarded by use of different substrates during early development. Artificially reared flatfish commonly exhibited abnormal pigmentation; correlations between pigment anomalies and small size at metamorphosis existed; and a relationship between pigment anomalies and abnormal jaw, opercular, and eye development was observed.

It should be mentioned here that the head is the portion most infrequently susceptible to the condition. It is also the most asymmetrical part of the body. In the majority of cases where ambicoloration is extensive and almost total, the underside of the head remains white. Also, pigmentation most often occurs on the portion of the body which comes in contact with the substrate less frequently. It has further been observed (Norman, 1934; Gudger, 1945, 1936; Deubler and Fahy, 1958) that individuals in which the coloration of the blind side extends past the operculum onto the head, usually have incomplete eye rotation (Figure 21a), although the specimen in Figure 21b is an exception to that rule.

Different degrees of ambicoloration or albinism exist. Cunningham and McMunn (1893), and deVeen (1969) have shown that the condition in its varying stages may progress in individual fish. Also, the prevalence may increase among some groups of fish as the individuals get older, indicating that the condition may progress throughout life. This again may be a result of the genetic susceptibility of a given population, some species or races being more susceptible to environmental change than others. Population differences in occurrence and frequencies of ambicoloration have been found, and abnormal behavior of ambicolorate fish has been noted.

Other reports attempt to link abnormal pigment development in flatfish with wounds, parasitization by certain larval trematodes, abnormal light conditions, and pollution of nursery grounds and coastal waters.

Pigmentation anomalies can be very abundant in certain flatfish populations. For example, a recent study in the north-east Irish Sea disclosed a prevalence of 28% ambicoloration in flounders (Platichthys flesus), with much lower prevalences (8% and 0.9% respectively) in plaice (Pleuronectes platessa) and dab (Limanda limanda) (Shelton and Wilson, 1973). In another study, abnormal pigmentation was found to be "a fairly common feature" of plaice populations of the North Sea (deVeen, 1969).

In field work, the degree of ambicoloration can sometimes be obvious, as in the case of extensive ambicoloration when almost the entire blind side of the fish is pigmented (Figure 21b). However, only rarely is the pigmentation complete; usually ambicolored fish exhibit spotting, staining, or patchiness of pigmentation on the blind side (Figure 22). However, in some species the extent to which the spots of the eyed side are reproduced on the blind side can also indicate severity. For instance, summer flounder have very colorful systematically arranged spots on their eyed side (Figure 19). Their representation on the blind side in terms of relative positioning and intensity and shape in relation to the upper color pattern (Figure 22b) can be used to grade or classify the condition. They will seldom be mirror images of the ones above. Usually the further

back on the body these spots are located, the less severe the degree of ambicoloration. This may be checked by inserting a pin in the spots of the eyed side, forcing it straight through the animal's body, and determining its relative position in relation to the spot on the underside. Also the intensity and shape of the spots, in relation to the upper color pattern, may help to classify specimens. At times only a small section of the animal's underside has darkened chromatophores; this may sometimes be obscured by normal fin pigmentation of the upper side.

Ambicoloration and partial albinism have been used successfully in attempts to distinguish races or subpopulations of flatfish (deVeen, 1969). The use of pigmentation anomalies in assessing pollution effects has been suggested, but not established. As in the case with all the developmental abnormalities discussed in sections VII, VIII and IX, environmental influences on established, but plastic, genetic traits are not yet clearly understood. Only by combining careful field sampling with adequate experimental studies can we expect to relate cause and effect for ambicoloration or any other of the abnormalities described in these sections to adverse environmental conditions.

NOTE: Other kinds of abnormal pigmentation are known in fish, for instance xanthochroism or "golden" fish, associated with reduction or absence of skin melanophores and increased numbers or maximal expansion of yellow chromatophores; melanization (blackening) of the flesh, often visible as a lacy black network throughout the body musculature; and true albinism -- absence of all pigment (Figure 23) -- characterized by pink eyes (blood vessels showing through unpigmented tissues).





Figure 21. Reversed summer flounder exhibiting incomplete eye migration and dorsal "hook" (above). (Courtesy of the American Museum of Natural History), Extensive ambicoloration in summer flounder with no dorsal fin abnormalities (below). (Photograph courtesy of Mr. T. Azarovitz, NMFS, Woods Hole Laboratory).

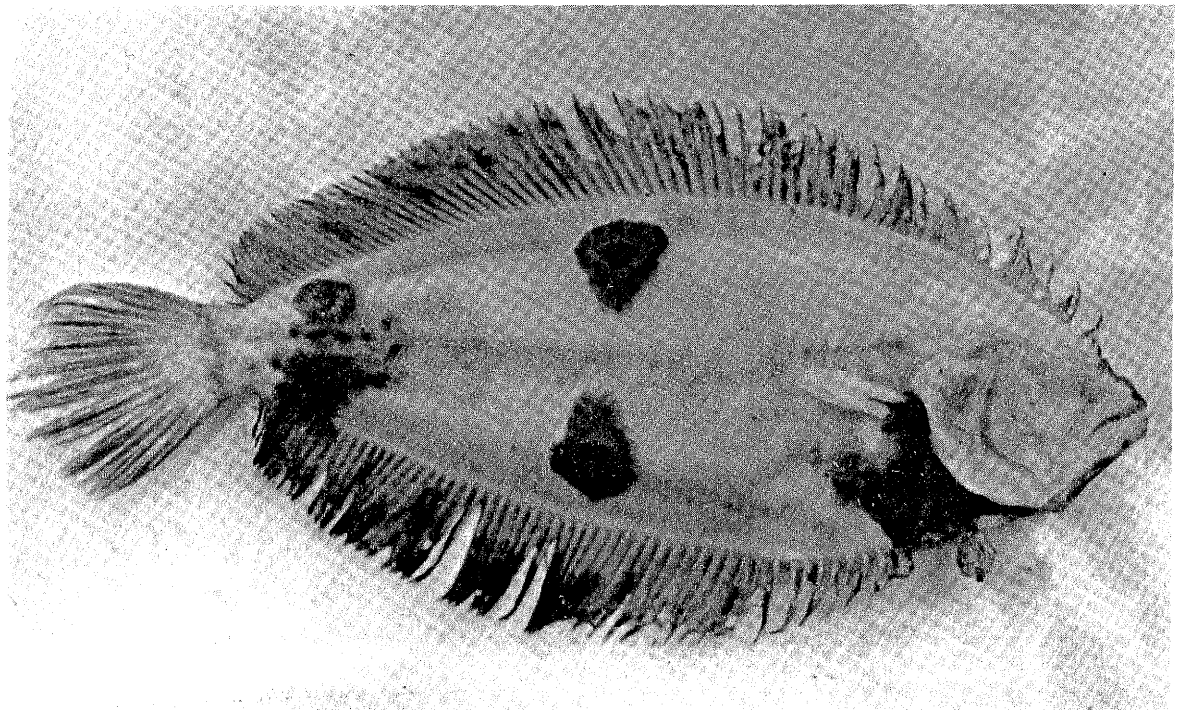
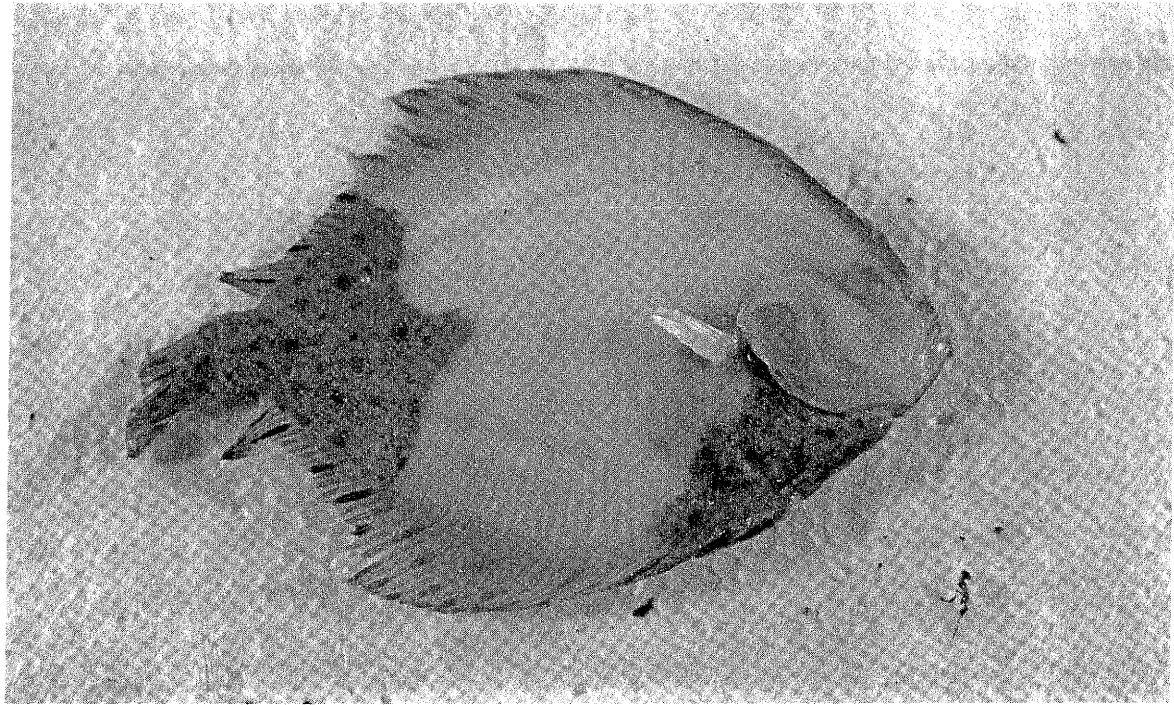


Figure 22. Patchiness in windowpane flounder, Scophthalmus aquosus (above); and reproduction of spots on normally unpigmented side of four-spot flounder, Paralichthys oblongus (below). (Photographs courtesy of Mr. M. Silverman and Mr. T. Azarovitz, NMFS).


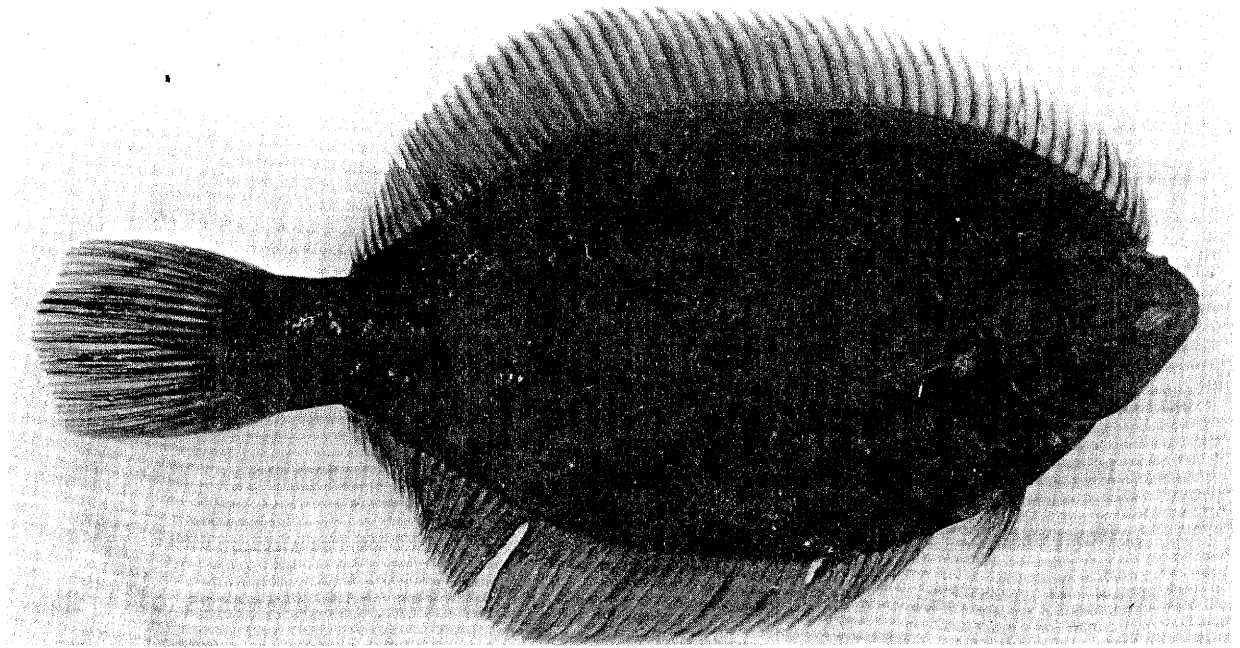


Figure 23. Normal pigmentation (above) and extensive albinism (below) in winter flounder. (Note: The fish with extensive albinism also had pink eyes). (Courtesy of M. Silverman, NMFS).

KEY REFERENCES

GENERAL

- Mawdesley-Thomas, L. E. (ed.). 1972. Diseases of fish. Acad. Press, London, 380 pp.
- Möller, H. 1977a. Indexed bibliography on parasites and diseases of marine fish from North Sea and Baltic Sea (2nd edition). Ber. Inst. Meereskde. Kiel 31: 47 pp.
- Möller, H. 1977b. Distribution of some parasites and diseases of fishes from the North Sea in February, 1977. Internat. Counc. Explor. Sea, Fish. Imp. Comm. Doc. CM1977/E: 20, 16 pp.
- Ribelin, W. E. and G. Migaki (eds.). 1975. The pathology of fishes. U. Wisconsin Press, Madison.
- Schäperclaus, W. 1969. Virusinfectionen bei Fischen. In: Röhrer, H. Handbuch der Virusinfektionen bei Tieren. Volume 5, Part 2. Gustav Fischer Verlag, Jena.
- Sindermann, C. J. 1970. Principal diseases of marine fish and shellfish. Acad. Press, N. Y., 369 pp.
- Sindermann, C. J. 1977. Recent data on possible associations of coastal/estuarine pollution with fish and shellfish diseases. ICES, Fish. Imp. Comm. Doc. CM1977/E:14, 33 pp.
- Snieszko, S. F. (ed.). 1970. A symposium on diseases of fishes and shellfishes. Amer. Fish. Soc. Spec. Pub. No. 5, 526 pp.

I. ULCERS

Levin, M. A., R. E. Wolke and V. J. Cabelli. 1972. Vibrio anguillarum as a cause of disease in winter flounder (Pseudopleuronectes americanus). Can. J. Microbiol. 18: 1585-1592.

Perkins, E. J., J. R. S. Gilchrist and O. J. Abbott. 1972. Incidence of epidermal lesions in fish of the northeast Irish Sea, 1971. Nature 328: 101-103.

Shelton, R. G. J. and E. W. Wilson. 1973. On the occurrence of lymphocystis, with notes on other pathological conditions in the flatfish stocks of the North East Irish Sea. Aquaculture 2: 395-410.

II. FIN EROSION

Couch, J. and Nimmo, D. 1974. Detection of interactions between natural pathogens and pollutants in aquatic animals. In: Proc. Symposium on Diseases of Aquatic Animals, LSU-Sea Grant 75-5, pp. 261-268.

Haastein, T. and G. Holt. 1972. The occurrence of Vibrio disease in wild Norwegian fish. J. Fish. Biol. 4: 33-37.

Mahoney, J. B., F. H. Midlge and D. G. Deuel. 1973. A fin rot disease of marine and euryhaline fishes in the New York Bight. Trans. Am. Fish. Soc. 102: 596-605.

Mearns, A. J. and M. Sherwood. 1974. Environmental aspects of fin erosion and tumors in Southern California Dover sole. Trans. Am. Fish. Soc. 103: 799-810.

- Minchew, C. D. and J. D. Yarbrough. 1977. The occurrence of fin rot in mullet (Mugil cephalus) associated with crude oil contamination of an estuarine pond ecosystem. J. Fish. Biol. 10: 319-329.
- Murchelano, R. A. and J. J. Ziskowski. 1976. Fin rot disease studies in the New York Bight. pp. 329-336. In: Proceedings of the Symposium on the Middle Atlantic Continental Shelf and the New York Bight. Amer. Soc. Limnol. Oceanog., Spec. Sympos. Vol. 2, Allan Press, Lawrence, Kansas.
- Perkins, E. J., J. R. S. Gilchrist and O. J. Abbott. 1972. Incidence of epidermal lesions in fish of the north-east Irish Sea, 1971. Nature, 328: 101-103.
- Wellings, S. R., C. E. Alpers and B. B. McCain. 1976. Fin erosion disease of starry flounder (Platichthys stellatus) and English sole (Parophrys vetulus) in the estuary of the Duwamish River, Seattle, Washington. J. Fish. Res. Bd. Can. 33: 2577-2586.
- Ziskowski, J. J. and R. Murchelano. 1975. Fin erosion in winter flounder (Pseudopleuronectes americanus) from the New York Bight. Mar. Poll. Bull. 6: 26-28.

III. TUMORS

- Deys, B. F. 1969. Papillomas in Atlantic eels, Anguilla vulgaris. Nat. Cancer Inst. Monogr. 31: 187-193.
- Koops, H., H. Mann, I. Pfitzner, O. J. Schmid and G. Schubert. 1969. Blumenkohlkrankheit bei Aalen. Arch. Fischerei-wiss. 20(1): 1-52.

- Lange, E. 1973. Carcinoid-like tumours in the pseudobranch of Gadus morhua (L.). *Comp. Biochem. Physiol.* 45: 477-481.
- Mawdesley-Thomas, L. E. 1971. Neoplasia in fish: a review. pp. 88-170. In: Cheng, T. C. (ed.). *Current topics in comparative pathobiology*, Vol. 1. Acad. Press, N. Y.
- Schlumberger, H. G. and B. Lucké. 1948. Tumors of fishes, amphibians and reptiles. *Cancer Res.* 8: 657-712.
- Stich, H. F., A. B. Acton and C. R. Forrester. 1976. Fish tumors and sublethal effects of pollutants. *J. Fish. Res. Bd. Can.* 33: 1993-2001.
- Takahashi, K. 1929. Studie über die Fischgeschwulste. *Z. Krebsforsch.* 29: 1-73.
- Wellings, S. R. 1969. Environmental aspects of neoplasia in fishes. pp. 3-22. In: Neuhaus, O. W. and J. E. Halver (eds.). *Fish in research*. Academic Press, N. Y.
- Wellings, S. R. and R. G. huinard. 1964. Epidermal papillomas with virus-like particles in the flathead sole, Hippoglossoides ellasodon. *Science* 13: 939-934.
- Wellings, S. R., C. E. Alpers, B. B. McCain and M. S. Myers. 1977. Fish disease in the Bering Sea. *Ann. N. Y. Acad. Sci.* 298: 290-304.

IV. LYMPHOCYSTIS

- Aneer, G. and O. Ljungberg. 1976. Lymphocystis disease in Baltic herring (Clupea harengus var. membras L.). J. Fish. Biol. 8: 345-350.
- Dukes, J. W. and A. R. Lawler. 1975. The ocular lesions of naturally occurring lymphocystis in fish. Can. J. Comp. Med. 39: 406-409.
- Mann, H. 1970. "Über den Befall der Plattfische der Nordsee mit Lymphocystis. Ber. Dt. Wiss. komm. Meeresforsch. 21: 219-223.
- McArn, G. E. and S. R. Wellings. 1971. A comparison of skin tumors in three species of flounders. J. Fish. Res. Bd. Can. 28: 1241-1251.
- Murchelano, R. A. and D. W. Bridges. 1976. Lymphocystis disease in the winter flounder, Pseudopleuronectes americanus. J. Wildl. Dis. 12: 101-103.
- Nigrelli, R. F. and G. D. Ruggieri. 1965. Spontaneous and experimentally induced lymphocystis disease in fishes of the New York Aquarium, with a report of new cases and an annotated bibliography. Zoologica, N. Y. 50: 83-95.
- Nordenberg, C. 1962. Das Vorkommen der Lymphocystiskrankheit bei Scholle und Flunder in Öresund. "Kgl. Fisiogr. Sällsk. Lund Forh. 32: 17-26.
- Perkins, E. J., J. R. S. Gilchrist and O. J. Abbott. 1972. Incidence of epidermal lesions in fish of the northeast Irish Sea. Nature 238: 101-103.

- Russell, P. H. 1974. Lymphocystis in wild plaice Pleuronectes platessa (L.) and flounder Platichthys flesus (L.), in British coastal waters. A histopathological and serological study. J. Fish. Biol. 6: 771-778.
- Shelton, R. G. J. and E. W. Wilson. 1973. On the occurrence of lymphocystis, with notes on other pathological conditions in the flatfish stocks of the North East Irish Sea. Aquaculture 2: 395-410.
- Templeman, W. F. 1965. Lymphocystis disease in American plaice of the eastern Grand Bank. J. Fish. Res. Bd. Can. 22: 1345-1356.
- van Banning, P. 1971. Wratziekte bij platvis. Visserij. 6: 336-343.
- Weissenberg, R. 1965. Fifty years of research on the lymphocystis disease of fishes (1914-1964). Ann. N. Y. Acad. Sci. 126: 375-385.

V. BLACK SPOTS

- Christensen, N. and H. Roth. 1949. Investigations on internal parasites of dogs. K. Vethøjsk. Aarskr. (Kjøbenhavn) 1949: 1-73.
- Sindermann, C. J. and A. E. Farrin. 1962. Ecological studies of Cryptocotyle lingua (Trematoda: Heterophyidae) whose larvae cause "pigment spots" of marine fish. Ecology 43: 69-75.

- Sindermann, C. J. and A. Rosenfield. 1954. Diseases of fishes of the western North Atlantic. III. Mortalities of sea herring (Clupea harengus) caused by larval trematode invasion. Maine Dept. Sea Shore Fish., Res. Bull. No. 21: 1-16.
- Stunkard, H. W. 1930. The life history of Cryptocotyle lingua (Creplin) with notes on the physiology of the metacercariae. J. Morph. 50: 143-191.
- Wolfgang, R. W. 1954a. Studies on the trematode Stephanostomum baccatum (Nicoll, 1907). I. The distribution of the metacercaria in eastern Canadian flounders. J. Fish. Res. Bd. Can. 11: 954-962.
- Wolfgang, R. W. 1954b. Studies on the trematode Stephanostomum baccatum (Nicoll, 1907). II. Biology, with special reference to the stages affecting the winter flounder. J. Fish. Res. Bd. Can. 11: 963-987.
- Wolfgang, R. W. 1955. Studies on the trematode Stephanostomum baccatum (Nicoll, 1907). III. Its life cycle. Can. J. Zool. 3: 113-128.

VI. PARASITIC COPEPODS

- Grabda, J. 1972. Observations on penetration of Lernaeolophus sultanus (Milne-Edwards, 1840) (Lernaeoceridae) in organs of Pneumatophorus colias (Gmelin, 1788). Acta Ichthyol. Piscat. 2: 115-125.

- Kabata, Z. 1957. Lernaeocera obtusa n. sp., a hitherto undescribed parasite of the haddock (Gadus aeglefinus L.). J. Mar. Biol. Ass. U. K. 36: 569-592.
- Kabata, Z. 1970. Crustacea as enemies of fishes. In: Snieszko, S. F. and H. R. Axelrod (eds.). Diseases of fishes. Book I. T.F.H. Pubs., Jersey City, N. J. 171 pp.
- Kabata, Z. and C. R. Forrester. 1974. Atheresthes stomias (Jordan and Gilbert, 1880) (Pisces: Pleuronectiformes) and its eye parasite Phrixocephalus cincinnatus Wilson 1908 (Copepoda: Lernaeoceridae) in Canadian Pacific waters. J. Fish. Res. Bd. Can. 31: 1589-1595.
- Mann, H. 1952. Lernaeocera branchialis (copepoda parasitica) und seine Schadwirkung bei einigen Gadiden. Arch. Fisch-wiss. 4: 133-144.
- Sundnes, G. 1970. Lernaeocera branchialis (L.) on cod Gadus morhua (L.) in Norwegian waters. Inst. Mar. Res. Bergen, 48 pp.
- Wilson, C. B. 1917. North American parasitic copepods belonging to the Lernaeidae, with a revision of the entire family. Proc. U. S. Nat. Mus. 53: 1-150.
- Wilson, C. B. 1932. The copepods of the Woods Hole region -- Massachusetts. Bull. U. S. Nat. Mus. 158, 635 pp.

VII. SKELETAL ABNORMALITIES

- Bailey, R. M. and W. A. Gosline. 1955. Variation and systematic significance of vertebral counts in the American fishes of the family Percidae. Misc. Publ. Mus. Zool., Univ. Mich. 93: 1-44.
- Barlow, G. W. 1961. Causes and significance of morphological variation in fishes. Syst. Zool. 10: 105-117.

- Dawson, C. E. 1964. A bibliography of anomalies of fishes. Gulf Res. Rept. 1: 308-399.
- Dawson, C. E. 1966. A bibliography of anomalies of fishes. Supplement 1. Gulf Res. Rept. 2: 169-176.
- Dawson, C. E. 1971. A bibliography of anomalies of fishes. Supplement 2. Gulf Res. Rept. 3: 215-239.
- Dawson, C. E. and E. Heal. 1976. A bibliography of anomalies of fishes. Supplement 3. Gulf Res. Rept. 5: 35-41.
- Ford, E. 1937. Vertebral variation in teleostean fishes. J. Mar. Biol. Assoc. U. K. 22: 1-58.
- Fowler, J. A. 1970. Control of vertebral number in teleosts -- an embryological problem. Quart. Rev. Biol. 45: 148-167.
- Hickey, C. R. Jr. 1972. Common abnormalities in fishes, their causes and effects. N. Y. Ocean Sci. Lab. Tech. Rept. No. 0013, 20 pp.
- Hubbs, C. L. 1943. Criteria for subspecies, species and genera, as determined by researches on fishes. Ann. N. Y. Acad. Sci. 44: 109-121.
- Hubbs, C. L. and L. C. Hubbs. 1945. Bilateral asymmetry and bilateral variation in fishes. Pap. Mich. Acad. Sci., Arts Lett. 30: 229-310.
- Kändler, R. 1932. Unsicherheiten bei Bestimmung der Wirbelzahl infolge Verwachsungserscheinungen. J. Cons. Int. Expl. Mer 7: 373-385.
- Komada, N. 1974. Studies on abnormality of bones in anomalous "Ayu", Plecoglossus altivelis. Fish. Pathol. 8: 127-135 (in Japanese, English abstract).

- Matsusato, T. 1973. On the skeletal abnormalities in marine fishes.
 I. The abnormal marine fishes collected along the coast of
 Hiroshima. Pref. Bull. Nansei Reg. Fish. Res. Lab. No. 6,
 pp. 17-43.
- Taning, A. V. 1952. Experimental study of meristic characters in
 fishes. Biol. Rev. 27: 169-193.
- Ueki, N. and T. Sugiyama. 1976. On abnormality of bones in artificially
 produced ayu, Plecoglossus altivelis (preliminary note). Bull. Fish.
 Exp. Sta. Okayama Pref. 50: 360-362 (in Japanese).
- Valentine, D. W. 1975. Skeletal anomalies in marine teleosts. pp. 695-
 718. In: Ribelin, W. E. and G. Migaki (eds.). The pathology of
 fishes. U. Wisc. Press, 1004 pp.
- van de Kamp, G. 1977. Vertebral deformities of herring around the
 British Isles and their usefulness for a pollution monitoring
 programme. ICES, Fish. Imp. Comm. Doc. CM1977/E: 5, 4 pp.
- Wunder, W. 1971. Missbildungen beim Kabeljau (Gadus morhua) verursacht
 durch Wirbelsäulenverkürzung. Helgol. wiss. Meeresunters. 22:
 201-212.
- Ziskowski, J. J., V. Anderson and R. Murchelano. (unpublished manuscript).
 A bent fin disease of winter flounder (Pseudopleuronectes americanus)
 from Sandy Hook-Raritan Bays, New Jersey, and Lower Bay, New York.

VIII. REVERSAL IN FLATFISH

- Anderson, V. T. Jr. (In press). Reversal in summer flounder, Paralichthys dentatus (L.) from the Middle Atlantic Bight. J. N. J. Acad. Sci.
- Dawson, C. E. 1962. Notes on anomalous American Heterosomata with descriptions of five new records. Copeia 1: 138-146.
- Dawson, C. E. 1964. A bibliography of anomalies of fishes. Gulf Res. Rept. 1: 308-399.
- Dawson, C. E. 1966. A bibliography of anomalies of fishes. Supplement 1. Gulf Res. Rept. 2: 169-176.
- Dawson, C. E. 1971. A bibliography of anomalies of fishes. Supplement 2. Gulf Res. Rept. 3: 215-239.
- Dawson, C. E. and E. Heal. 1976. A bibliography of anomalies of fishes. Supplement 3. Gulf Res. Rept. 5: 35-41.
- Deubler, E. E., Jr. and W. E. Fahy. 1958. A reversed ambicolorate summer flounder, Paralichthys dentatus. Copeia 1958(1): 55.
- Gudger, E. W. 1935. Abnormalities in flatfishes (Heterosomata). Hour. Morph. 58: 1-39.
- Gudger, E. W. 1936. A reversed almost wholly ambicolorate summer flounder, Paralichthys dentatus. Am. Mus. Nov. 896: 1-5.
- Houde, E. D. 1971. Developmental abnormalities of the flatfish, Achirus lineatus, reared in the laboratory. Fish. Bull. U. S. 69: 537-544.

- Hubbs, C. L. and L. C. Hubbs. 1945. Bilateral asymmetry and bilateral variation in fishes. Pap. Mich. Acad. Sci., Arts Lett. 30: 299-310.
- Kyle, H. M. 1923. The asymmetry, metamorphosis and origin of flatfishes. Phil. Trans. Roy. Soc. London. Ser. B, 211 (Part II): 75-129.
- Norman, J. R. 1934. A systematic monograph of the flatfishes (Heterosomata). Brit. Mus. Nat. Hist. 1: 1-459.
- Regan, C. T. 1910. The origin and evolution of the teleostean fishes of the order Heterosomata. Ann. Mag. Nat. Hist. 8: 481-484.

IX. AMBICOLORATION

- Cunningham, J. T. and C. A. McMunn. 1893. On the coloration of the skins of fishes, especially of Pleuronectidae. Phil. Trans. Roy. Soc. B184: 765-812.
- Deubler, E. E., Jr. and W. E. Fahy. 1958. A reversed ambicolorate summer flounder, Paralichthys dentatus (L.). Copeia 1958(1): 55.
- deVeen, J. F. 1969. Abnormal pigmentation as a possible tool in the study of the populations of the plaice (Pleuronectes platessa (L.)). J. Cons. Int. Expl. Mer 32: 344-383.
- Gudger, E. W. 1936. A reversed almost wholly ambicolorate summer flounder, Paralichthys dentatus (L.). Am. Mus. Nov. 896: 1-5.
- Norman, J. R. 1934. A systematic monograph of the flatfishes (Heterosomata). Brit. Mus. Nat. Hist. 1: 1-459.
- Shelton, R. G. J. and E. W. Wilson. 1973. On the occurrence of lymphocystis, with notes on other pathological conditions in the flatfish stocks of the North East Irish Sea. Aquaculture 2: 395-410.
- Stickney, R. and B. White. 1975. Ambicoloration in tank cultured flounder, Paralichthys dentatus. Trans. Amer. Fish. Soc. 104: 158-160.

ACKNOWLEDGMENTS

The authors wish to thank Drs. C. L. Smith and G. Nelson of the American Museum of Natural History for permission to reprint Dr. Gudger's original photographs; Mr. S. J. Wilk, Mr. Myron J. Silverman, Mr. Malcolm J. Silverman, Mr. J. J. O'Reilly, and Mr. T. Azarovitz of the National Marine Fisheries Service; Mr. L. Albert, Lincoln University, Dr. S. R. Wellings, University of California, Ms. M. J. Sherwood, Southern California Coastal Water Research Project, Dr. P. van Banning, Rijksinstituut voor Visserijonderzoek (Ijmuiden), and Dr. E. Egidius, Institute of Marine Research (Bergen), for permission to use a number of the photographs included in this publication.